Archives of Razi Institute Journal
"Arch. Razi Inst."

Journal Homepage: https://archrazi.areeo.ac.ir/

Research Paper

Clinical and Hematologic Response to Remdesivir Treatment in Cats With Feline Infectious Peritonitis in Iran: A Prospective Observational Study

Erfaneh Khavari[1], Seyedeh Missagh Jalali[1*], Mohammad Razi Jalali[1], Bahman Mosallanejad[1]

1. Department of Clinical Sciences, Faculty of Veterinary Medicine, Shahid Chamran University of Ahvaz, Ahvaz, Iran.

Use your device to scan and read the article online

How to cite this article Khavari E, Jalali SM, Razi Jalali M, Mosallanejad B. Clinical and Hematologic Response to Remdesivir Treatment in Cats With Feline Infectious Peritonitis in Iran: A Prospective Observational Study. Archives of Razi Institute Journal. 2026; 81(1):203-212. https://doi.org/10.66224/ARI.81.1.3992

https://doi.org/10.66224/ARI.81.1.3992

Article info:

Received: 09 Aug 2025

Accepted: 02 Oct 2025

Published: 01 Jan 2026

ABSTRACT

Introduction: Feline infectious peritonitis (FIP) is a progressive and often fatal disease caused by virulent feline coronavirus (FCoV) mutations. Despite the increasing use of antiviral agents such as remdesivir, prospective clinical data from Iran remain limited. This prospective observational study evaluated clinical and hematological responses to remdesivir in 31 polymerase chain reaction (PCR)-confirmed FIP cases.

Materials & Methods: Sixteen cats (51.6%) had the effusive form, nine (29%) the non-effusive form, and six (19.4%) exhibited ocular or neurologic involvement. All cats received remdesivir following a standardized 84-day protocol which consisted of a 4-day induction phase (10 mg/kg daily for effusive FIP and 15 mg/kg daily for non-effusive/neurologic forms), followed by once-daily subcutaneous maintenance therapy from day 5 to day 84. Clinical and laboratory evaluations were performed on days 0, 42, and 84.

Results: Significant clinical improvement occurred over the treatment period, with anorexia decreasing from 64.5% to 6.5%, weight loss from 83.9% to 19.4%, and lethargy from 67.7% to 25.8%, while dyspnea, abdominal distension, and icterus resolved completely ($P<0.05$). The mean clinical severity score demonstrated a marked reduction, decreasing from 6.40±1.20 at baseline to 1.55±0.9 at day 84 ($P<0.001$), indicating a pronounced overall clinical improvement. Hematological abnormalities characteristic of FIP also improved significantly. Hemoglobin increased from 7.72±1.57 to 9.75±1.18 g/dL and hematocrit from 28.28±5.91% to 36.7±4.57%, while total leukocytes decreased from $13.77±5.09×10^3/\mu L$ to $7.31±2.18×10^3/\mu L$ ($P<0.05$). Lymphocyte count increased (from 1.38±0.96 to $2.56±0.88×10^3/\mu L$) while neutrophils decreased (from 10.18±2.9 to $4.02±1.31×10^3/\mu L$), thereby lowering the neutrophil-to-lymphocyte ratio from 10.53±6.82 to 1.98±1.46 ($P<0.001$). Mid-treatment data (day 42) demonstrated early hematological recovery.

Conclusion: These findings suggest that remdesivir induces marked and consistent clinical improvement and substantial hematologic normalization in naturally occurring FIP in Iran, providing region-specific evidence supporting its efficacy.

Keywords:

Clinical improvement, Feline coronavirus (FCoV), Hematology, Molecular diagnosis, Remdesivir

*** Corresponding Author:**

Seyedeh Missagh Jalali, Associate Professor.

Address: *Department of Clinical Sciences, Faculty of Veterinary Medicine, Shahid Chamran University of Ahvaz, Ahvaz, Iran.*

E-mail: *mi.jalali@scu.ac.ir*

Copyright © 2026 The Author(s);
This work is licensed under a Creative Commons Attribution-NonCommercial 4.0 International license(https://creativecommons.org/licenses/by-nc/4.0/).
Noncommercial uses of the work are permitted, provided the original work is properly cited.

1. Introduction

Feline infectious peritonitis (FIP) is a highly fatal, immune-mediated disease that develops following mutations in the widely circulating feline coronavirus (FCoV) [1, 2]. While most FCoV infections cause mild or subclinical enteric disease, a subset of viral mutations enhances replication within monocytes and macrophages, leading to the emergence of the virulent FIP (FIPV) [1, 3]. This altered cellular tropism allows systemic dissemination and induces pyogranulomatous inflammation, immune dysregulation, vasculitis, and cytokine-mediated tissue injury [3-5]. Consequently, affected cats may develop either the effusive form, characterized by protein-rich serous effusions, or the non-effusive form, in which granulomatous lesions involve multiple organs [3, 6]. Without antiviral intervention, FIP is considered almost uniformly fatal [7, 8].

The clinical manifestations of FIP are diverse and often non-specific, complicating diagnosis and necessitating integration of physical examination findings, hematologic abnormalities, and molecular testing [4, 9]. Frequently reported signs include persistent fever, progressive weight loss, anorexia, lethargy, dyspnea, and abdominal distension related to effusion, lymphadenopathy, and mucous membrane pallor or discoloration. Neurologic and ocular abnormalities are common in non-effusive disease [4, 7]. Hematologic disturbances such as non-regenerative anemia, leukocytosis with neutrophilia and lymphopenia, and thrombocytosis or thrombocytopenia are recognized markers that support clinical suspicion and assist in evaluating treatment response [5, 6].

Advances in molecular diagnostics have markedly improved diagnostic accuracy. Reverse-transcription polymerase chain reaction (RT-PCR) assays targeting conserved regions of the FCoV genome, particularly the spike (*S*) gene, are now routinely used in clinically compatible cases [4, 10]. Although PCR positivity alone cannot distinguish benign enteric biotypes from pathogenic FIPV, detection of viral RNA in blood or effusion substantially increases diagnostic confidence when interpreted within the proper clinical and hematologic context [9, 10].

The therapeutic landscape of FIP has changed significantly with the introduction of antiviral agents that inhibit viral RNA-dependent RNA polymerase. Remdesivir, an adenosine nucleotide analogue with proven activity against multiple coronaviruses, has shown promising clinical efficacy in naturally occurring FIP [7, 8]. Reported outcomes include rapid improvement in systemic signs, resolution of effusion, restoration of appetite and activity, and gradual normalization of hematologic parameters [5, 8]. Despite these encouraging findings, detailed prospective evaluations—including structured clinical scoring and serial complete blood count (CBC) monitoring—remain limited, particularly in studies employing standardized treatment protocols [7, 8].

To date, no prospective investigation from Iran has documented the clinical and hematologic trajectories of PCR-confirmed FIP cases treated with remdesivir. Such evidence is essential for establishing region-specific treatment expectations, guiding therapeutic decisions, and supporting broader clinical adoption. The objective of the present study was to characterize the clinical manifestations and hematologic alterations of 31 PCR-confirmed cats with FIP treated with an 84-day remdesivir protocol. By systematically evaluating key clinical signs and CBC parameters at baseline, mid-treatment, and at the completion of therapy, this study provides a comprehensive description of treatment-associated recovery in naturally occurring FIP.

2. Materials and Methods

2.1. Study design and animals

This prospective observational study enrolled 31 domestic cats that were examined in privately owned veterinary clinics in Tehran for clinical signs suggestive of FIP. Clinical abnormalities prompting evaluation included persistent fever, weight loss, anorexia, lethargy, dyspnea, abdominal distension, dehydration, jaundice (icterus), mucous membrane pallor or discoloration, lymphadenopathy, and neurologic or ocular abnormalities. Enrollment was permitted only after molecular confirmation of FCoV infection using blood-based PCR.

All cats were evaluated before initiation of therapy and were monitored for a total of 84 days. Eligibility criteria included: (1) clinical signs compatible with FIP and (2) a positive blood PCR result for FCoV. Cats were excluded if they had received antiviral medications, glucocorticoids, or other immunosuppressive drugs within the preceding 30 days. All diagnostic and therapeutic procedures were performed in accordance with accepted veterinary clinical practice.

2.2. Clinical evaluation

A structured physical examination was performed at three time points: prior to treatment (day 0), mid-treatment (day 42±2), and completion of therapy (day 84±3).

At each visit, the attending veterinarian recorded body temperature, appetite, demeanor, hydration status, mucous membrane coloration, respiratory pattern, abdominal contour, peripheral lymph node size, and the presence or absence of pallor, dyspnea, effusion-associated abdominal distension, ocular lesions, or neurologic deficits. Baseline history regarding the onset and progression of clinical signs was documented. All examinations were performed by the same veterinarian to minimize inter-observer variability and were conducted using a standardized checklist to ensure consistency and enable paired comparisons across time points.

2.3. Clinical severity score

A clinical severity score was assigned to each cat on Days 0, 42, and 84 to quantify overall clinical disease burden. The scoring system was adapted from previously published FIP assessment methods [8]. Each abnormal clinical finding—including weight loss, anorexia, lethargy, fever, dyspnea, abdominal distension, pallor, icterus, dehydration, lymphadenopathy, vomiting, and diarrhea—was given a value of 1 if present. The total score represented the sum of abnormalities for each cat, with higher scores indicating more severe clinical involvement.

2.4. Molecular confirmation of FCoV infection

2.4.1. Sample collection and RNA extraction

For molecular confirmation, 1–2 mL of peripheral blood was collected from each cat at presentation. RNA extraction was performed using a commercial viral RNA extraction kit (Total RNA Extraction Mini Kit Plus with YTZOL reagent, Yekta Tajhiz Azma, Iran) according to the manufacturer's instructions. Extracted RNA was stored at −20 ˚C until analysis.

2.4.2. RT-PCR for FCoV detection

RT-PCR was performed using primer sets targeting a conserved region of the FCoV spike (*S*) gene, following the protocol of Wang et al. (2022) [11]. Primer sequences and Amplicon size are presented in Table 1. Amplification conditions included: Reverse transcription at 50 ˚C for 30 minutes, initial denaturation at 95 ˚C for 10 minutes, followed by 40 cycles of 95 ˚C for 15 seconds and 60 ˚C for 60 seconds. Positive and negative controls were included in each PCR run. Samples were considered positive when the amplification curve crossed the threshold before cycle 35. Only cats exhibiting compatible clinical signs and testing positive by RT-PCR were included in the study.

2.5. Hematologic evaluation

Blood samples were collected from the cephalic vein on days 0, 42, and 84. At each time point, 3–5 mL of blood was obtained, and 1–2 mL was placed into ethylene diamine tetraacetic acid (EDTA) tubes for complete blood count (CBC) analysis. All samples were analyzed within 2 hours to minimize cellular degradation. CBCs were performed using a veterinary automated hematology analyzer (NIHON KOHDEN Celltac Alpha VET, model MEK-6550K, Japan), which provided red blood cell indices, hemoglobin concentration, hematocrit, total leukocyte count, absolute differential leukocyte counts, platelet counts, and erythrocyte indices, and analyzer-specific reference intervals were applied. Wright–Giemsa–stained smears were reviewed when necessary to verify automated differential results.

2.6. Treatment protocol

All cats received remdesivir according to a standardized 84-day regimen adapted from established therapeutic protocols for FIP [8]. The protocol consisted of a 4-day induction phase followed by a maintenance phase. During induction, cats with effusive FIP received 10 mg/kg once daily intravenously or subcutaneously, while cats with non-effusive or neurologic/ocular forms received 15 mg/kg once daily. Beginning on day 5 and continuing through day 84, all cats received once-daily subcutaneous injections of remdesivir.

Maintenance dosages were adjusted according to clinical form: 8–10 mg/kg for effusive cases, 10–12 mg/kg for non-effusive cases, and 12–15 mg/kg for cats exhibiting neurologic or ocular involvement. Injection sites (lateral thorax, flank, dorsal cervical region) were rotated routinely to minimize discomfort and reduce the risk of tissue irritation. All injections were administered slowly, and cats were monitored for adverse reactions including injection-site swelling, pain, lethargy, and gastrointestinal disturbances.

2.7. Statistical analysis

Paired categorical clinical variables (day 0 vs day 84) were analyzed using McNemar's test. Hematologic parameters were assessed for normality using the Shapiro–Wilk test. Normally distributed variables were compared using paired t-tests; non-normally distributed variables were analyzed using the Wilcoxon signed-rank test. Mean±SD, and P-values were calculated to assess changes across time points. A $P<0.05$ was considered statistically significant. Statistical analyses were performed using SPSS software, version 26 (IBM SPSS Statistics).

Table 1. Primer sequences used for RT-PCR detection of FCoV

Target gene	Primer Name	Sequence (5′→3′)	Amplicon Size (bp)
Spike (*S*) gene	FCoV-S-F	AGATCCAGTTGAGGTAGAAGTT	218
	FCoV-S-R	ATCATCTTGTCTGCGTTCTTC	

3. Results

3.1. Description of the study population

Thirty-one domestic cats diagnosed with FIP were enrolled after confirmation of FCoV RNA by blood-based RT-PCR. The cats ranged in age from 5 to 24 months, with a median age of 13 months, and body weights between 1.9 and 4.4 kg (mean: 3.2±0.7 kg). The study population consisted of 16 males and 15 females. Based on clinical form, 16 cats (51.6%) exhibited the effusive type, 9 cats (29.0%) presented with the non-effusive form, and 6 cats (19.4%) showed ocular or neurologic involvement. All 31 cats successfully completed the standardized 84-day remdesivir protocol and were included in the final clinical and hematologic analyses (Table 2).

3.2. Clinical findings

At baseline (day 0), the most frequently observed abnormalities included weight loss (83.9%), anorexia (64.5%), and lethargy (67.7%). Other commonly noted signs were fever, dyspnea, abdominal distension, and mucous membrane pallor, each affecting approximately 38.7–48.4% of the cats. Following completion of the 84-day remdesivir regimen, substantial improvement was recorded across all parameters. The prevalence of weight loss declined to 19.4%, anorexia to 6.5%, and lethargy to 25.8%. Fever decreased from 38.7% to 16.1%, while dyspnea and abdominal distension resolved completely in all affected cats. Mucous membrane pallor also improved from 48.4% at baseline to 19.4% at day 84. McNemar's test confirmed significant reductions in weight loss, anorexia, lethargy, dyspnea, and abdominal distension ($P<0.05$). No new clinical abnormalities developed during the treatment period. The mean clinical severity score demonstrated a marked reduction, decreasing from 6.4±1.2 at baseline to 1.55±0.9 at day 84 ($P<0.001$), indicating pronounced overall clinical improvement (Table 3) (Figures 1 and 2).

3.3. Hematologic Results

Serial hematologic assessments revealed progressive improvement throughout the 84-day treatment period. At baseline, red cell indices were reduced, with an RBC count of $5.66\pm1.18\times10^6/\mu L$, hemoglobin of 7.72±1.57 g/dL, and hematocrit of 28.28±5.91%. By day 84, these values had increased significantly, reaching $7.55\pm1.1\times10^6/\mu L$ for RBC, 9.75±1.18 g/dL for hemoglobin, and 36.70±4.57% for hematocrit ($P<0.001$). Total leukocyte count demonstrated a marked decline, decreasing from $13.77\pm5.09\times10^3/\mu L$ at baseline to $7.31\pm2.18\times10^3/\mu L$ by day 84 ($P<0.05$) (Table 4).

Table 2. Baseline characteristics of the 31 PCR-confirmed FIP cats

Signalment	Category	No. (%)	Range within Group
Sex	Male	16(51.6)	–
	Female	15(48.4)	–
Age (m)	≤12	14(45.2)	5–12
	>12	17(54.8)	13–24
Body weight (kg)	≤3	12(38.7)	1.9–3
	>3	19(61.3)	3.1–4.4
Clinical form	Effusive	16(51.6)	–
	Non-effusive	9(29)	–
	Ocular/Neurologic	6(19.4)	–

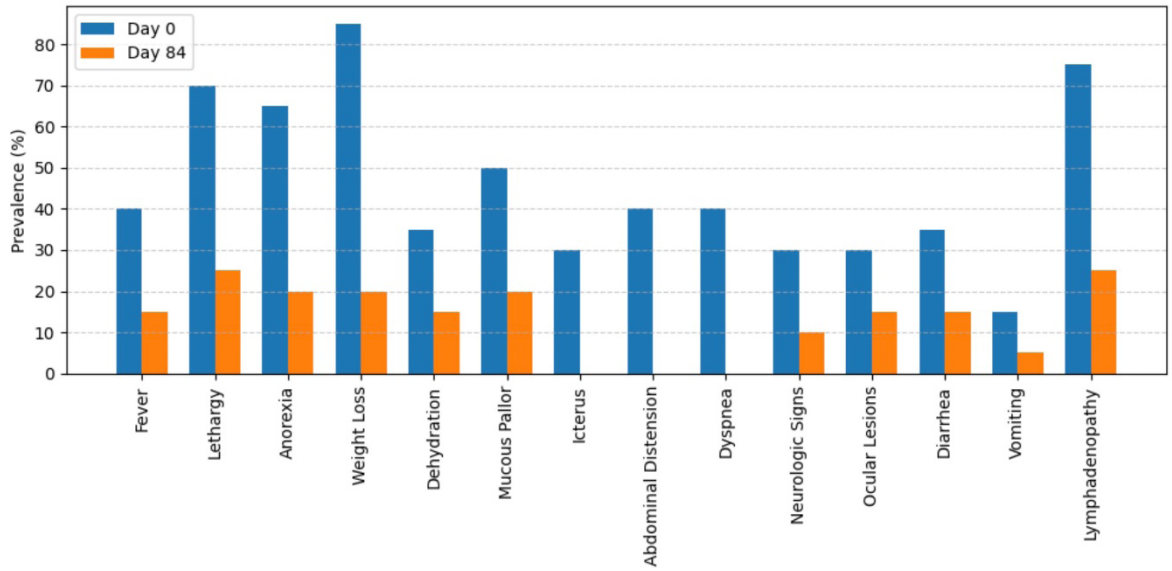

Figure 1. Prevalence of major clinical signs at baseline (day 0) and after treatment (day 84) in 31 PCR-confirmed cats with FIP

Note: Bars represent mean values with standard error.

Absolute differential leukocyte counts also improved. Neutrophils decreased from 10.18±2.9×10³/µL at baseline to 4.02±1.31×10³/µL at day 84, while lymphocytes increased from 1.38±0.96×10³/µL to 2.56±0.88×10³/µL ($P<0.001$). These changes produced a substantial reduction in the neutrophil-to-lymphocyte ratio, falling from 10.53±6.82 at baseline to 1.98±1.46 at day 84. Monocytes and eosinophils showed mild but statistically significant changes over the treatment period, falling from 0.81±0.58×10³/µL to 0.21±0.16×10³/µL and rising from 0.19±0.09×10³/µL to 0.49±0.34×10³/µL, respectively ($P<0.05$). Band neutrophils, present at low levels at baseline (0.28±0.14×10³/µL), declined to near zero by day 84. Platelet counts decreased from an initially elevated value of 462.74±229.61×10³/µL to 280.68±73.5×10³/µL at day 42 and subsequently stabilized within the normal range at 298.42±78.15×10³/µL at day 84 ($P<0.05$).

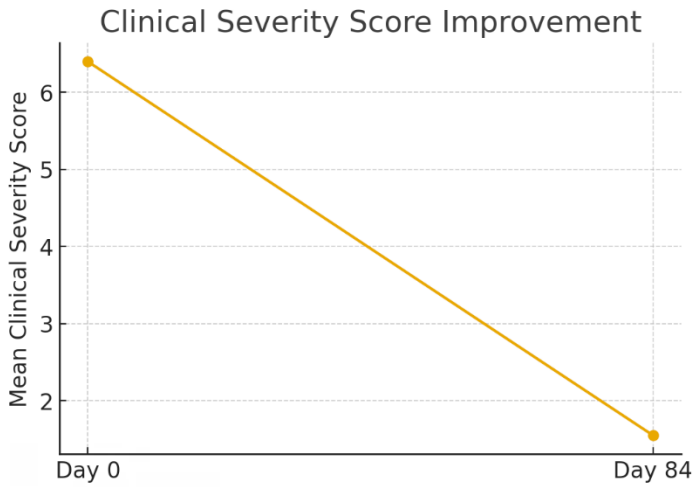

Figure 2. Clinical severity score at baseline (day 0) and after completion of the 84-day remdesivir protocol (day 84) in 31 PCR-confirmed cats with FIP

Note: The score was calculated as the total number of abnormal clinical signs present in each cat. A marked reduction in the mean score was observed, indicating substantial clinical improvement.

Table 3. Prevalence of principal clinical signs at baseline (day 0) and after treatment (day 84) in 31 cats with FIP

Clinical Sign	No. (%)/Mean±SD		P
	Day 0	Day 84	
Weight loss	26(83.9)	6(19.4)	<0.001
Anorexia	20(64.5)	6(19.4)	0.004
Lethargy	21(67.7)	8(25.8)	0.004
Fever	12(38.7)	5(16.1)	0.125
Dyspnea	12(38.7)	0(0)	0.008
Abdominal distension	12(38.7)	0(0)	0.008
Pallor	15(48.4)	6(19.4)	0.031
Icterus	9(29)	0(0)	0.031
Dehydration	11(35.5)	5(16.1)	0.219
Diarrhea	11(35.5)	5(16.1)	0.344
Vomiting	5(16.1)	2(6.5)	0.625
Lymphadenopathy	23(74.2)	8(25.8)	0.006
Clinical severity score	6.40±1.2	1.55±0.9	<0.001

Note: P lower than 0.05 were considered statistically significant for differences between day 0 and day 84 of treatment.

4. Discussion

The objective of this prospective observational study was to characterize the clinical and hematologic responses of 31 PCR-confirmed cats with FIP treated with a standardized 84-day remdesivir protocol. Across all evaluated parameters, the results demonstrated substantial clinical improvement accompanied by marked normalization of key hematologic abnormalities. Core clinical signs—including weight loss, anorexia, lethargy, fever, dyspnea, abdominal distension, mucous membrane pallor, icterus, and dehydration—declined steadily throughout the treatment period, with complete resolution of dyspnea and abdominal distension by day 84. Hematologic disturbances typically associated with active FIP, such as anemia, leukocytosis with neutrophilia, lymphopenia, and thrombocytosis, also improved significantly by days 42 and 84. These combined findings indicate a strong therapeutic response and provide evidence supporting the effectiveness of remdesivir in naturally occurring FIP.

The clinical outcomes in this cohort are broadly consistent with findings from larger antiviral studies. In a retrospective analysis of 307 cats treated with legally sourced remdesivir or GS-441524, Taylor et al. (2023) reported survival rates approaching 90% [8]. While the present study reported a 100% completion rate among the 31 cats included in the final dataset, this value does not represent the entire initially assessed population. Additional cats were screened at presentation but were excluded due to severe clinical deterioration, loss to follow-up, or death prior to day 84. Thus, completion data must be interpreted cautiously and considered within the context of this attrition. A major distinction from retrospective investigations is that all cats retained in the present study were required to have blood-based PCR confirmation. Although blood PCR has lower sensitivity than effusion PCR, its high specificity in clinically compatible cases reduces diagnostic heterogeneity and strengthens confidence that the improvements observed reflect genuine FIP treatment responses.

Comparable patterns of clinical improvement have also been documented in controlled antiviral trials. Cosaro et al. (2023) demonstrated non-inferiority between oral remdesivir and GS-441524 in 18 cats with effusive FIP, reporting rapid reduction of effusion and resolution of systemic illness [12]. The present study included effusive, non-effusive, and ocular/neurologic cases, yet the magnitude and speed of improvement—particularly the complete disappearance of dyspnea and abdominal

Table 4. Hematologic parameters as Mean±SD at day 0, day 42, and day 84 in 31 cats with FIP treated with remdesivir

Parameter	Mean±SD			P
	Day 0	Day 42	Day 84	
RBC (10^6/µL)	5.66±1.18	6.84±1.01	7.55±1.1	<0.001
Hemoglobin (g/dL)	7.72±1.57	9.03±1.06	9.75±1.18	<0.001
Hematocrit (L/L)	28.28±5.91	32.58±3.45	36.70±4.57	<0.001
MCV (fL)	42.12±4.62	43.58±2.58	44.27±1.9	0.044
MCH (pg)	11.31±2.87	15.1±1.02	15.12±0.68	<0.001
MCHC (g/dL)	29.18±2.65	33.28±1.45	33.54±1.01	<0.001
WBC (10^3/µL)	13.77±5.09	11.08±4.79	7.31±2.18	<0.001
Neutrophils (10^3/µL)	10.18±2.9	6.98±1.96	4.02±1.31	<0.001
Lymphocytes (10^3/µL)	1.38±0.96	2.66±0.67	2.56±0.88	<0.001
Monocytes (10^3/µL)	0.81±0.58	0.32±0.23	0.21±0.16	0.005
Eosinophils (10^3/µL)	0.19±0.09	0.54±0.39	0.49±0.34	0.018
Band cells (10^3/µL)	0.28±0.14	0.11±0.06	0±0	<0.001
Platelets (10^3/µL)	462.74±229.61	280.68±73.5	298.42±78.15	0.006
Neutrophil-to-lymphocyte ratio	10.53±6.82	2.8±0.97	1.98±1.46	<0.001

Note: Absolute differential counts are expressed as×10^3 cells/µL. P-values were derived from paired t-tests or Wilcoxon signed-rank tests after assessment of distribution normality.

distension—parallel the rapid stabilization described in effusive-only cohorts. By incorporating structured hematologic evaluation at fixed time points, the present study expands upon previous findings and provides more detailed insight into the physiological trajectory of recovery during remdesivir therapy.

The hematologic trends observed here align closely with findings from GS-441524-based research. Larson et al. (2025) reported increases of approximately 25–30% in hemoglobin and hematocrit during antiviral therapy; the present study demonstrated similar improvements of 26% and 32%, respectively [13]. Total leukocyte count decreased by nearly half between baseline and day 84, mirroring reductions in systemic inflammation noted by Larson et al. (2025) [13]. Tršar et al. (2025) also documented improved neutrophil and lymphocyte distributions following GS-441524 treatment; the current cohort exhibited a comparable transition from neutrophilia toward a balanced leukocyte profile, reflected in a marked reduction in the neutrophil-to-lymphocyte ratio [14].

The structured clinical severity score used in this study proved to be a practical tool for quantifying treatment response. The decline in mean score from 6.40 at baseline to 1.55 at day 84 reflects a substantial reduction in overall disease burden. Because this scoring system relies solely on readily accessible clinical observations, it is well suited for general veterinary practice, where advanced diagnostic biomarkers such as alpha-1 acid glycoprotein, serum amyloid A, or cytokine profiling may be unavailable. When combined with serial complete blood count evaluation, this scoring approach provides a comprehensive and practical method for monitoring clinical progression and therapeutic efficacy.

Despite these strengths, several limitations must be acknowledged. The sample size, although larger than many prospective FIP studies, remains insufficient for detailed subgroup comparisons among effusive, non-effusive, and neurologic/ocular cases. The absence of a GS-441524 control group limits direct evaluation of comparative antiviral efficacy; however, numerical comparisons with existing literature offer meaningful context. Biochemical parameters and acute-phase proteins

were not assessed, restricting evaluation of systemic inflammation to hematologic indices alone. Additionally, all cases originated from a single geographic region, which may reduce generalizability. Finally, follow-up was limited to the duration of the 84-day protocol; longer-term monitoring, such as that performed by Larson et al. (2025), would be necessary to assess relapse risk and long-term remission durability [13].

5. Conclusion

This prospective study demonstrates that an 84-day remdesivir regimen produces substantial clinical recovery and marked hematologic normalization in PCR-confirmed FIP. Major clinical abnormalities—including respiratory compromise, gastrointestinal signs, and systemic lethargy—improved rapidly, while red cell indices, leukocyte profiles, and platelet values showed marked normalization throughout the treatment period. Notably, this study represents the first prospective clinical evaluation of remdesivir for naturally occurring FIP in Iran, providing novel, region-specific data on its clinical and hematologic effects. The close alignment between these findings and those reported in international antiviral studies further supports the therapeutic efficacy of remdesivir. Based on the clinical and hematologic responses, remdesivir can be recommended as an effective and accessible antiviral option for the treatment of FIP in clinical practice. Remdesivir is currently available in Iran and is manufactured by several domestic pharmaceutical companies. However, to date, no published studies have evaluated its efficacy against indigenous FCoV strains in Iran. The main limitations of this study include a relatively limited sample size, the lack of biochemical and inflammatory biomarker assessment, and restricted long-term post-treatment follow-up. Future investigations should include larger controlled trials, integration of biochemical and inflammatory markers, and molecular characterization of regional FCoV strains. Despite these limitations, the present study provides strong, region-specific evidence that remdesivir represents an effective and accessible antiviral option for managing FIP in clinical practice.

Acknowledgements

The authors would like to acknowledge the Research Vice-Chancellor of Shahid Chamran University of Ahvaz for financial support and the private veterinary clinics in Tehran that collaborated in this study.

Compliance with ethical guidelines

The study involved client-owned animals undergoing routine clinical care, and no additional experimental procedures were performed. Therefore, formal institutional ethical approval was not required. Informed consent was obtained from all owners prior to inclusion of their animals in the study.

Data availability

All data analyzed during this study are included in this article.

Funding

This study was extracted from the PhD dissertation of Erfaneh Khavari, approved by the Department of Clinical Sciences, Faculty of Veterinary Medicine, Shahid Chamran University of Ahvaz, Ahvaz, Iran. This study was supported by Shahid Chamran University of Ahvaz, Ahvaz, Iran (Grant No.: SCU. VC 1404.199).

Authors' contributions

Conceptualization, study design, project administration, and supervision: Seyedeh Missagh Jalali, Mohammad Razi Jalali, and Bahman Mosallanejad; Data acquisition: Erfaneh Khavari; Data interpretation: Seyedeh Missagh Jalali and Erfaneh Khavari; Statistical analysis: Seyedeh Missagh Jalali and Erfaneh Khavari; Writing the original draft: Erfaneh Khavari and Seyedeh Missagh Jalali; Review and editing: Seyedeh Missagh Jalali and Mohammad Razi Jalali.

Conflict of interest

The authors declared no conflict of interest.

References

[1] Gao YY, Wang Q, Liang XY, Zhang S, Bao D, Zhao H, et al. An updated review of feline coronavirus: Mind the two biotypes. Virus Res. 2023; 326:199059. [DOI:10.1016/j.virusres.2023.199059] [PMID]

[2] Solikhah TI, Agustin QAD, Damaratri RA, Siwi DAF, Rafi'uttaqi GN, Hartadi VA, et al. A review of feline infectious peritonitis virus infection. Vet World. 2024; 17(11):2417-32. [DOI:10.14202/vetworld.2024.2417-2432] [PMID]

[3] Pedersen NC, Sykes JE. Feline Coronavirus Infections. In: Sykes JE, editor. Greene's infectious diseases of the dog and cat. Louis (MO): W.B. Saunders; 2021. [DOI:10.1016/B978-0-323-50934-3.00031-8]

[4] Thayer V, Gogolski S, Felten S, Hartmann K, Kennedy M, Olah GA. 2022 AAFP/everycat feline infectious peritonitis diagnosis guidelines. J Feline Med Surg. 2022; 24(9):905-33. [DOI:10.1177/1098612X221118761] [PMID]

[5] Cucolicchio MG, Silva BC, Passos PH, Oliveira IM. Feline Infectious peritonitis-diagnostic and therapeutic approach. Acta Sci Vet. 2024; 52:1-10. [Link]

[6] Licitra BN, Whittaker GR. Coronavirus Infection. In: Ettinger SJ, Feldman EC, Cote E, editors. Ettinger's textbook of veterinary internal medicine. 9th ed. Philadelphia (PA): Elsevier; 2024. [Link]

[7] Mir S, Peters M, Penny G, Agsaoa A, Mir M. From challenge to cure: A look at feline infectious peritonitis and emerging treatment strategies and breakthroughs. Vet Sci. 2025; 12(7):650. [DOI:10.3390/vetsci12070650] [PMID]

[8] Taylor SS, Coggins S, Barker EN, Gunn-Moore D, Jeevaratnam K, Norris JM, et al. Retrospective study and outcome of 307 cats with feline infectious peritonitis treated with legally sourced veterinary compounded preparations of remdesivir and GS-441524 (2020-2022). J Feline Med Surg. 2023; 25(9):1098612X231194460. [DOI:10.1177/1098612X231194460] [PMID]

[9] Tasker S. Diagnosis of feline infectious peritonitis: Update on evidence supporting available tests. J Feline Med Surg. 2018; 20(3):228-43. [DOI:10.1177/1098612X18758592] [PMID]

[10] Barua S, Sarkar S, Chenoweth K, Johnson C, Delmain D, Wang C. Insights on feline infectious peritonitis risk factors and sampling strategies from polymerase chain reaction analysis of feline coronavirus in large-scale nationwide submissions. J Am Vet Med Assoc. 2024; 263(1):82-9. [DOI:10.2460/javma.24.03.0208] [PMID]

[11] Wang L, Olmstead C, Fredrickson R. Real-Time RT-PCR for detection of feline coronavirus. In: Wang L, editor. Animal coronaviruses. New York: Springer Protocols Handbooks; 2022. [DOI:10.1007/978-1-0716-2091-5_10]

[12] Cosaro E, Pires J, Castillo D, Murphy BG, Reagan KL. Efficacy of oral remdesivir compared to GS-441524 for treatment of cats with naturally occurring effusive feline infectious peritonitis: A blinded, Non-Inferiority Study. Viruses. 2023; 15(8):1680. [DOI:10.3390/v15081680] [PMID]

[13] Larson K, Hart E, Negash R, Novicoff W, Jacque N, Evans S. Prospective analysis of clinicopathologic correlates of at-home feline infectious peritonitis treatment using GS-441524. Pathogens. 2025; 14(5):507. [DOI:10.3390/pathogens14050507] [PMID]

[14] Tršar L, Štrljič M, Svete AN, Koprivec S, Tozon N, Žel MK, et al. Evaluation of selected inflammatory markers in cats with feline infectious peritonitis before and after therapy. BMC Vet Res. 2025; 21(1):330. [DOI:10.1186/s12917-025-04731-x] [PMID]

This Page Intentionally Left Blank