Archives of Razi Institute Journal
"Arch. Razi Inst."

Journal Homepage: https://archrazi.areeo.ac.ir/

Research Paper

Therapeutic Potential of *Hibiscus sabdariffa* in Minimizing Gentamicin-induced Nephrotoxicity and Testicular Histopathological Alterations In Rats

Mohamad Raviansyah Jawindra[1], Wiwik Misaco Yuniarti[2*], Devia Kurniawati Yoanita Kurniawati[3], Issaura Vita Yulinda[3], Aldhia Safiranisa[3], Ahmad Nasir Fachrudin[3], Bambang Sektiari Lukiswanto[2], Ratna Widyawati[4]

1. Department of Reproductive Biology, Universitas Airlangga, Surabaya, Indonesia.
2. Department of Veterinary Clinic, Faculty of Veterinary Medicine, Universitas Airlangga, Surabaya, Indonesia.
3. Department of Veterinary Medicine, Universitas Airlangga, Surabaya, Indonesia.
4. Department of Surgery, Faculty of Veterinary Medicine, Universitas Wijaya Kusuma Surabaya, Surabaya, Indonesia.

Use your device to scan and read the article online

How to cite this article Jawindra MR, Yuniarti WM, Kurniawati DKY, Yulinda IV, Safiranisa A, Fachrudin AN, Lukiswanto BS, et al. Therapeutic Potential of *Hibiscus sabdariffa* in Minimizing Gentamicin-induced Nephrotoxicity and Testicular Histopathological Alterations In Rats. Archives of Razi Institute Journal. 2026; 81(4):931-942. https://doi.org/10.32598/ARI.81.4.3807

https://doi.org/10.32598/ARI.81.4.3807

Article info:
Received: 14 Mar 2026
Accepted: 23 May 2026
Published: 01 Jul 2026

Keywords:
Gentamicin, *Hibiscus sabdariffa*, Nephrotoxicity, Testicular toxicity

ABSTRACT

Introduction: Gentamicin, a widely used aminoglycoside antibiotic, is associated with significant nephrotoxicity and gonadotoxicity, limiting its clinical utility. This study was designed to evaluate the protective effects of roselle (*Hibiscus sabdariffa*) extract, known for its rich antioxidant content, on renal histopathology and seminiferous tubule thickness in rats exposed to gentamicin-induced toxicity.

Materials & Methods: Twenty-five male Wistar rats were randomly assigned to five groups: a negative control, a positive control (gentamicin only), and three treatment groups receiving roselle extract at 200, 400, or 600 mg/kg body weight along with gentamicin. The extract was administered orally for 15 consecutive days, while gentamicin (80 mg/kg) was injected intraperitoneally from day 8 to 15 to induce organ damage. At the study's conclusion, kidney and testis tissues were collected for histopathological examination using Hematoxylin and Eosin (H&E) staining. Renal damage was assessed by scoring glomerular and tubular degeneration, necrosis, and inflammatory cell infiltration, whereas seminiferous tubule thickness was measured.

Results: The positive control group showed severe renal damage, characterized by widespread tubular necrosis, glomerular atrophy, and intense inflammation, alongside a significant reduction in seminiferous tubule thickness compared to the negative control. Conversely, rats co-treated with roselle extract demonstrated a dose-dependent amelioration of these pathological changes, showing marked improvements in kidney structure and preservation of testicular integrity. Notably, the 200 mg/kg dose exhibited the most pronounced protective effect, restoring tissue architecture to near-normal conditions.

Conclusion: These findings suggest that roselle extract mitigates gentamicin-induced organ damage, likely through its potent antioxidant and anti-inflammatory properties that combat drug-induced oxidative stress. This supports its potential as a natural therapeutic agent to counteract the adverse effects of essential drugs.

*** Corresponding Author:**
Wiwik Misaco Yuniarti, Professor.
Address: *Department of Veterinary Clinic, Faculty of Veterinary Medicine, Universitas Airlangga, Surabaya, Indonesia.*
E-mail: *wiwikmisaco@yahoo.com*

Copyright © 2026 The Author(s);
This work is licensed under a Creative Commons Attribution-NonCommercial 4.0 International license (https://creativecommons.org/licenses/by-nc/4.0/).
Noncommercial uses of the work are permitted, provided the original work is properly cited.

1. Introduction

Antibiotics, hailed as medical breakthroughs for their role in combating bacterial infections, are not without adverse consequences. Gentamicin, a widely used aminoglycoside antibiotic effective against *Pseudomonas*, *Proteus*, and *Serratia* species, has revolutionized the treatment of severe infections [1, 2]. However, its clinical utility is significantly limited due to its well-documented nephrotoxicity [3] and broader organ toxicity, particularly evident in the histopathological changes of the kidneys and testes.

Gentamicin-induced kidney damage involves a complex interplay of oxidative stress, inflammation, and structural damage to renal tissues [4], while its detrimental impact on testicular function is marked by disruptions in spermatogenesis and alterations in reproductive parameters, largely driven by oxidative mechanisms [5]. Oxidative stress, characterized by an imbalance between the production of reactive oxygen and nitrogen species (ROS/RNS) and the body's antioxidant defenses, leads to lipid peroxidation, protein denaturation, and DNA damage [6, 7].

Herbal products have long been explored for their protective roles against drug-induced organ toxicity [8, 9]. One of the herbs that have been known to have rich constituent of active compound is Roselle flower (*Hibiscus sabdariffa*). Roselle flower extract is rich in bioactive compounds, particularly phenolic compounds such as anthocyanins and flavonoids, which function as free radical scavengers, antioxidants, anti-inflammatory agents, and inhibitors of lipid peroxidation [10, 11]. In addition, roselle contains significant amounts of ascorbic acid (vitamin C), which contributes to reducing oxidative stress and cellular damage caused by reactive oxygen species (ROS), thereby mitigating degeneration, necrosis, and inflammatory cell infiltration [12].

Experimental studies have show that the administration of roselle extract in gentamicin-treated rats significantly attenuated oxidative stress markers and improved histopathological features of the testes [13]. Furthermore, the nephroprotective effects of roselle extract highlight its therapeutic potential in managing antibiotic-induced organ toxicity. The nephroprotective effects and antioxidant competence might offer protection against renal glomerular necrosis, glomerular inflammation, tubular degeneration, interstitial inflammation, and thickening of the testicular seminiferous tubules, which can be assessed through their histopathological images [14].

2. Materials and Methods

2.1. Preparation of rosella extract

The maceration method was used to make rosella flower extract (*H. sabdariffa*) by weighing 500 grams of simplicia powder and extracting it using a 96% ethanol solvent. Rosella flower powder was soaked in 96% ethanol until it was fully submerged. Three cycles of the maceration procedure were carried out for a total of twenty-four hours while being constantly stirred. The filtrate and residue were then separated using a flannel cloth. The resultant filtrate was then concentrated using a rotary evaporator set to 50 ˚C. A water bath was used to thicken the extract in order to remove any leftover solvent, yielding a concentrated extract of rosella flowers.

2.2. Animal procedure

The study utilised 25 male Wistar strain white rats (*Rattus norvegicus*), each weighing between 150 and 200 grammes and aged 2 to 3 months. The experimental rats were obtained from Bintang Jaya White Rat Supplier in Surabaya and fulfilled the criteria of being healthy (clear eyes and normal behaviour). A simple random sampling method used to categorize the white rats into five treatment groups. The negative control group (C-) received a 0.5% CMC-Na suspension orally for 15 days, added with intraperitoneal aquadest from day 8 to day 15. The positive control group second group (C+) acted as the positive control, administered a 0.5% CMC-Na suspension orally for 15 days and gentamicin injection at 80 mg/kg intraperitoneally from day 8 to day 15. The first treatment group (T1) received roselle flower extract at 200 mg/kgBW orally for 15 days and Gentamicin injection at 80 mg/kg Intraperitoneally from day 8 to day 15. The second treatment group (T2) received roselle flower extract at 400 mg/kgBW orally for 15 days and gentamicin injection at 80 mg/kg Intraperitoneally from day 8 to day 15. The third treatment group (T3) received roselle flower extract at 600 mg/kgBW orally for 15 days and gentamicin injection at 80 mg/kg intraperitoneally from day 8 to day 15.

2.3. Histopathological examination of kidney

The kidney histopathological examination was carried out using a Nikon E100 light microscope in 400x magnification, equipped with an Optilab Advance Plus digital camera (12 megapixels) and Image Raster image processing software. Adjustments to assess proximal tubular epithelial cell degeneration are essential for the assessment of renal damage [15]. The infiltration of inflammatory cells in glomerulus is assessed as follows: 0

= indicates absence of inflammatory cells in the glomerulus, 1 = intermittent nearness of inflammatory cells, 2 = central infiltration of inflammatory cells, 3 = multifocal invasion of inflammatory cells, 4 = diffused infiltration of inflammatory cells. The assessment for necrotic gromelurus/ degeneration is as follows: 0 = no degenerative alterations observed, 1 = degenerative cells <25%, 2 = degenerative cells 26-50%, 3 = degenerative cells 51-75%, 4 = degenerative cells >76%. The assessment for tubular necrosis /degeneration is as follows: 0 = no degenerative alterations observed, 1 = degenerative cells <25%, 2 = degenerative cells 26-50%, 3 = degenerative cells 51-75%, 4 = degenerative cells >76%. The infiltration of inflammatory cells in the renal interstitium is assessed as follows: 0 = indicates absence of inflammatory cells in the renal interstitium. 1 = intermittent nearness of inflammatory cells, 2 = central infiltration of inflammatory cells, 3 = multifocal invasion of inflammatory cells, 4 = diffused infiltration of inflammatory cells.

2.4. Histopathological examination of testicular seminiferous tubule thickness

The testicular seminiferous tubule thickness examination was carried out using a Nikon E100 light microscope in 100x magnification, equipped with an Optilab Advance Plus digital camera (12 megapixels) and Image Raster image processing software. The measurement of the thickness of testicular seminiferous tubules was carried out by measuring the thickness of the mucosal epithelium observed in 10 fields of view at 100x magnification. The inclusion criteria for the measured seminiferous tubules were: intact tubule cross-sections, no swelling, and a relatively round shape. The measurement was performed by drawing a perpendicular line from the basal membrane layer to the spermatid layer.

2.5. Analysis

Data obtained from the histopathological measurements of the kidneys and seminiferous tubules of the testis were analyzed statistically using the IBM SPSS software version 29.2. Initial testing was performed using the Shapiro-Wilk normality test. Data that were normally distributed (P>0.05) were further analyzed using ANOVA followed by Duncan's post-hoc test, while data that were not normally distributed (P<0.05) were analyzed using the non-parametric Kruskal-Wallis test and followed by Mann-Whitney. Significant differences between groups were indicated by a P<0.05.

3. Results

3.1. Glomerular inflammation

Table 1 presents the mean glomerular inflammation scores for each experimental group. The negative control group (C-) showed the lowest inflammation score (0.033±0.08), significantly lower than the positive control group (C+) which received gentamicin (1.067±0.48). Treatment groups T2 and T3, receiving 400 mg/kgBW and 600 mg/kgBW of roselle extract respectively, exhibited similar inflammation scores to the C+ group, suggesting that these doses did not significantly mitigate glomerular inflammation induced by gentamicin. Conversely, group T1 (200 mg/kgBW roselle extract) showed a significantly lower score (0.5±0.21) compared to C+, indicating a potential ameliorative effect at this lower dose. Complementary to these quantitative results, Figure 1 provides histopathological images of renal glomerular inflammation, with yellow arrows indicating the inflammatory cell infiltration observed at 400× magnification. In the negative control (C–), the glomeruli appear normal with clear structure and no visible inflammatory cells. In contrast, the positive control (C+) displays obvious signs of inflammation, with numerous inflammatory cells infiltrating the glomerular area (yellow arrows). The T1 group (200 mg/kgBW roselle extract) shows a slight increase in inflammatory cells compared to the C– group, but the overall glomerular structure remains mostly intact. However, tissue from the T2 (400 mg/kgBW) and T3 (600 mg/kgBW) groups still shows infiltration similar to the C+ group, with mild disruption of glomerular structure. These images support the data in Table 1, highlighting that the lower dose of roselle extract (T1) maintained glomerular architecture closer to normal, while higher doses were less effective in limiting gentamicin-related inflammation.

3.2. Glomerular necrotic

As shown in Table 2, the negative control group (C-) demonstrated minimal glomerular necrotic score (0.13±0.16). The positive control group (C+) exhibited a significantly higher necrotic score (1.43±0.89) and doesn't have a statistical difference compared to T2 treatment group (0.76±0.15) and T3 treatment group (1.16±0.54). The T1 treatment group (1.16±0.38) displaying the most notable effect when compared to the C- group (0.13±0.16), indicating a beneficial effect of roselle extract in reducing gentamicin-induced glomerular necrosis. The histopathological images are presented in Figure 2, which shows histopathological images of renal glomerular necrosis at

Table 1. Glomerular inflammation score between groups

Group	Mean±SD
(C-) 0.5% CMC-Na and aquadest	0.033±0.08[a]
(C+) Gentamicin 80 mg/kgBW	1.067±0.48[c]
(T1) Gentamicin 80 mg/kgBW + roselle extract 200 mg/kgBW	0.5±0.21[b]
(T2) Gentamicin 80 mg/kgBW + roselle extract 400 mg/kgBW	0.76±0.15[c]
(T3) Gentamicin 80 mg/kgBW + roselle extract 600 mg/kgBW	1.16±0.54[c]

[a, b, c] Different superscripts showed significant differences between groups (P<0.05).

Table 2. Glomerular necrotic score between groups

Group	Mean±SD
(C-) 0.5% CMC-Na and aquadest	0.13±0.16[a]
(C+) Gentamicin 80 mg/kgBW	1.43±0.89[c]
(T1) Gentamicin 80 mg/kgBW + roselle extract 200 mg/kgBW	1.16±0.38[b]
(T2) Gentamicin 80 mg/kgBW + roselle extract 400 mg/kgBW	1.2±0.62[c]
(T3) Gentamicin 80 mg/kgBW + roselle extract 600 mg/kgBW	1.16±0.54[c]

[a, b, c] Different superscripts showed significant differences between groups (P<0.05)

400× magnification. The yellow arrows pointing to mesangial cells undergoing necrosis, confirming the extent of cellular damage. In the negative control (C–), glomeruli appear healthy with intact mesangial cells and no visible signs of necrosis. The positive control (C+) shows clear necrotic changes, with multiple mesangial cells losing their normal morphology (yellow arrows). Sections from the T1 group (200 mg/kgBW roselle extract) reveal noticeably fewer necrotic cells, and the glomerular structure closer to normal condition as shown in C– group. In contrast, tissue from the T2 (400 mg/kgBW) and T3 (600 mg/kgBW) groups still exhibits necrotic changes similar to those observed in the C+ group.

3.3. Tubular necrotic / degenerative

Table 3 presents the tubular necrotic and degenerative scores. The C– group recorded a low score (0.63±0.34), while the C+ group showed marked tubular damage (3.17±0.48). Statistical analysis indicated that the T1 (200 mg/kgBW Roselle Extract) and T2 (400 mg/kgBW Roselle Extract) groups produced comparable outcomes, with only slight differences from the C– group. These results suggest that both doses were effective in reducing tubular necrosis and degeneration. Histopathological images in Figure 3 further support these findings, illustrating renal tubular changes at 400× magnification. In the C– group, the renal tubules retain their normal architecture with

Table 3. Tubular necrotic / degenerative score between groups

Group	Mean±SD
(C-) 0.5% CMC-Na and aquadest	0.63±0.34[a]
(C+) Gentamicin 80 mg/kgBW	3.17±0.48[d]
(T1) Gentamicin 80 mg/kgBW + roselle extract 200 mg/kgBW	2.17±0.96[bc]
(T2) Gentamicin 80 mg/kgBW + roselle extract 400 mg/kgBW	1.6±0.66[b]
(T3) Gentamicin 80 mg/kgBW + roselle extract 600 mg/kgBW	2.41±0.66[cd]

[a, b, d, bc, cd] Different superscripts showed significant differences between groups (P<0.05)

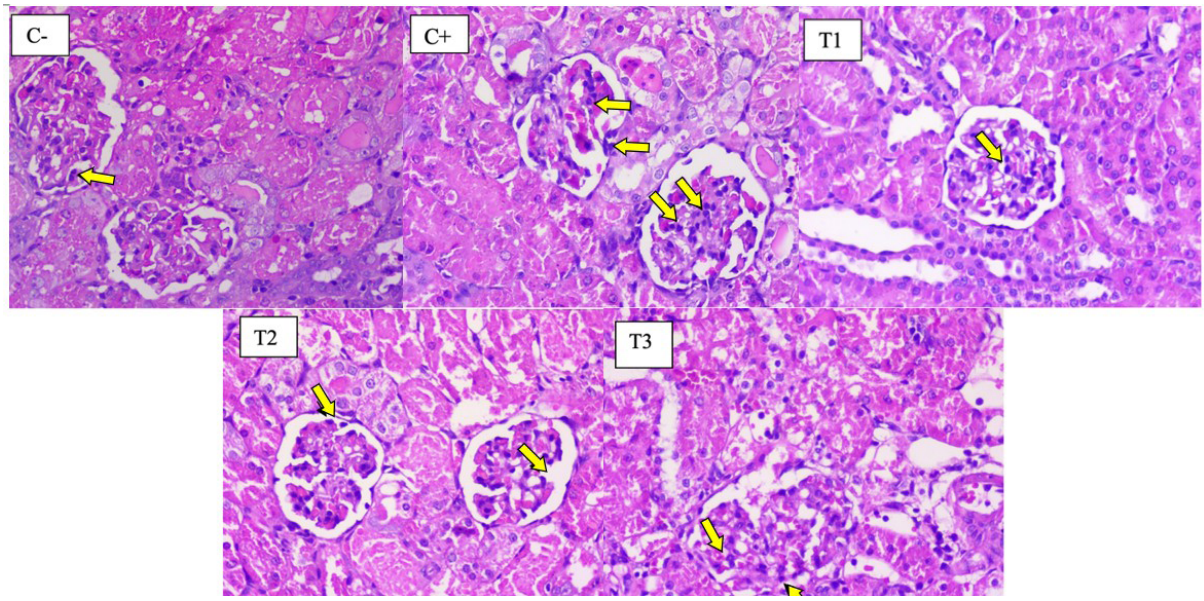

Figure 1. Histopathological images of renal glomerular inflammation (H&E staining 400×)

Note: The yellow arrows (⇨) indicate inflammatory cell infiltration.

well-preserved epithelial lining and no visible degeneration. In contrast, the C+ group exhibits extensive necrosis characterized by widespread epithelial cell loss, tubular dilation, and disruption of the basement membrane, which are highlighted by the yellow arrows. Sections from the T3 group (600 mg/kgBW roselle extract) reveal mild to moderate degenerative changes, suggesting that the higher dose provided limited protection. Meanwhile, the T1 and T2 groups show the least tubular damage, with largely preserved epithelial cells, minimal necrotic areas, and structural features that most closely resemble those seen in the C– group. This pattern implies that the lower and moderate doses of roselle extract may have exerted a protective effect on the renal tubules, potentially through their antioxidant and anti-inflammatory properties, whereas the highest dose may not confer additional benefit and could even begin to lose efficacy. These findings provide strong histological confirmation of the quantitative data, emphasizing that the protective effect of roselle extract is most apparent at the lower and intermediate doses.

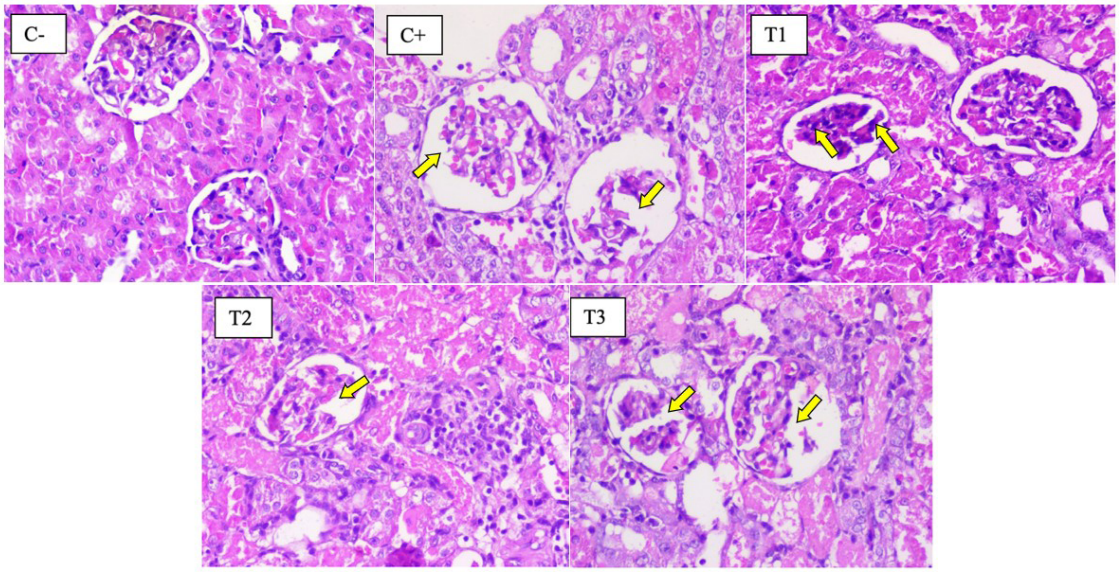

Figure 2. Histopathological images of renal glomerular necrosis (H&E staining 400×)

Note: The yellow arrows (⇨) indicate mesengial cell of glomerulus undergoes cell necrosis.

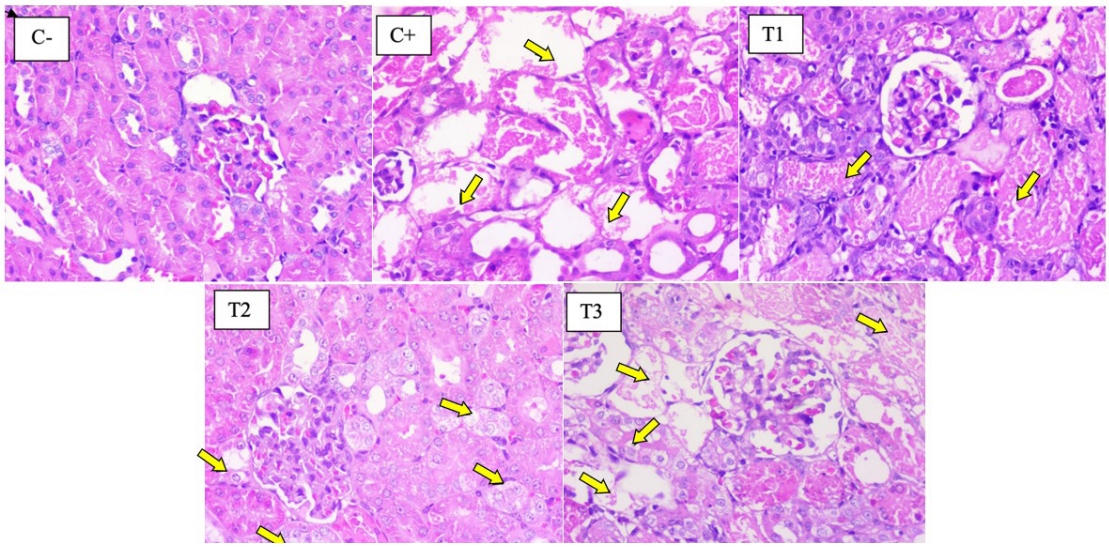

Figure 3. Histopathological images of renal tubular necrosis (H&E staining 400×)

Note: The yellow arrows (⇨) indicate the part of renal tubulus that undergoes necrosis or degeneration.

3.4. Interstitial inflammation

Table 4 indicates the interstitial inflammation scores. The C- group had a minimal score (0.13±0.16). The C+ group showed significant interstitial inflammation (1.9±0.72). Treatment group T1 (200 mg/kgBw roselle extract) significantly reduced inflammation (0.4±0.51) and have a closer histological condition compared to the C- group, suggesting an anti-inflammatory effect. However, T3 (600 mg/kgBW roselle extract) showed a score (2.2±0.46) comparable to or even higher than the C+ group, suggesting a dose-dependent effect where higher doses might not be as beneficial or could even exacerbate inflammation in the interstitium. Figure 4, the histopathological images of renal interstitial inflammation at 400× magnification, visually confirms the inflammatory cell infiltration, as indicated by the yellow arrows, reinforcing the quantitative data. In Figure 4, kidney sections from the C– group show normal interstitial tissue with no visible inflammatory cells. In contrast, the C+ group displays widespread infiltration of inflammatory cells, which is marked by the yellow arrows. The T1 group (200 mg/kgBW roselle extract) shows only sparse inflammatory cells, and the overall tissue structure remains close to normal, supporting the anti-inflammatory effect suggested by the scores. The T2 group (400 mg/kgBW) presents moderate infiltration, indicating partial improvement compared to C+. Interestingly, sections from the T3 group (600 mg/kgBW) reveal dense clusters of inflammatory cells and disrupted tissue architecture, closely resembling or even exceeding the inflammation seen in the C+ group. These histological findings align with the data in Table 4, illustrating that the lower dose of roselle extract provided the clearest protective effect, while the highest dose appeared to worsen interstitial inflammation.

3.5. Seminiferous tubules epithelial's thickness

Table 5 presents the mean thickness of the seminiferous tubule epithelium across the experimental groups. The negative control group (C-) exhibited a mean thickness of 74.11±16.66 µm. The positive control group (C+), administered gentamicin, showed a slightly increased mean thickness of 82.92±17.93 µm, although this difference was not statistically significant compared to C-. This observation in the C+ group aligns with previous studies indicating that gentamicin can affect testicular tissue, potentially by elevating ROS levels which can impact the integrity of spermatogenic cells and other testicular components. Among the treatment groups, T2 (gentamicin 80 mg/kgBW + roselle extract 400 mg/kgBW) demonstrated a significantly higher epithelial thickness (80.75±14.75 µm) compared to the C- group, and notably maintained a thickness comparable to the C+ group. This suggests that the 400 mg/kgBW dose of roselle extract may exert a protective or regenerative effect on the seminiferous tubules, potentially by enhancing antioxidant defenses against gentamicin-induced oxidative stress, as Roselle is rich in compounds like anthocyanins, flavonoids, and ascorbic acid known to neutralize ROS and improve cellular integrity. Conversely, treatment groups T1 (200 mg/kgBW roselle extract) with 69.01±12.20 µm and T3 (600 mg/kgBW roselle extract) with 72.8±19.66 µm did not show significant differences from the c- group, nor did they significantly improve thickness compared to the C+

Table 4. Interstitial inflammation score between groups

Group	Mean±SD
(C-) 0.5% CMC-Na and aquadest	0.13±0.16[a]
(C+) Gentamicin 80 mg/kgBW	1.9±0.72[d]
(T1) Gentamicin 80 mg/kgBW + roselle extract 200 mg/kgBW	0.4±0.51[b]
(T2) Gentamicin 80 mg/kgBW + roselle extract 400 mg/kgBW	1.04±0.81[c]
(T3) Gentamicin 80 mg/kgBW + roselle extract 600 mg/kgBW	2.2±0.46[d]

[a, b, c, d] Different superscripts showed significant differences between groups (P<0.05).

group. This indicates a dose-dependent efficacy, where the 400 mg/kgBW dose appears most effective in preserving or restoring seminiferous tubule epithelial thickness. Figure 5 provides histopathological images of the seminiferous tubule epithelium at 400× magnification.

4. Discussion

The administration of gentamicin at a dose of 80 mg/kg body weight for eight days, as observed in the positive control group (C+), resulted in noticeable renal damage, with histopathological scores showing clear increases in glomerular inflammation (1.07±0.48), glomerular necrosis (1.43±0.89), and tubular degeneration (3.17±0.48). These findings align with the known mechanism of gentamicin toxicity, wherein the drug enters cells and binds to polysomes, thereby disrupting protein synthesis. This disruption leads to increased lipid peroxidation and a reduction in ATP production [2, 16]. The decline in ATP levels, along with excessive generation of ROS, promotes intracellular accumulation of sodium (Na^+), as well as calcium (Ca^{2+}) and water influx, ultimately resulting in cellular degeneration marked by cloudy swelling, cell enlargement, and cytoplasmic vacuolization [15].

Gentamicin-induced nephrotoxicity occurs through various mechanisms, generally classified into vascular, glomerular, and tubular components. These toxic effects vary with dose and administration route. In the tubular system, gentamicin causes necrosis of proximal tubular epithelial cells and disrupts endocytic functions [17]. Within the glomerulus, the initial filtration structure of the nephron, gentamicin induces mesangial cell contraction and reduces the glomerular filtration rate. Additionally, it decreases renal blood flow by increasing vascular resistance without affecting perfusion pressure, which in turn reduces oxygen and ATP availability in the tubules [18]. The accumulation of gentamicin in the proximal tubules is attributed to the expression of specific protein and cation transporters in that region. Moreover, the megalin–cubilin receptor complex facilitates the uptake of gentamicin through endocytosis, contributing to renal injury via oxidative stress mechanisms [19].

The results of this study demonstrate that the negative control group (C–) maintained nearly normal histological structures, with very low scores for inflammation (0.03±0.08), necrosis (0.13±0.16), and tubular changes (0.63±0.34), while the treatment groups receiving roselle extract showed varying degrees of improvement. Among

Table 5. Seminiferous tubule epithelial's thickness between groups

Group	Mean±SD
	Thickness (µm)
(C-) 0.5% CMC-Na and aquadest	74.11±16.66[a]
(C+) Gentamicin 80 mg/kgBW	82.92±17.93[b]
(T1) Gentamicin 80 mg/kgBW + roselle extract 200 mg/kgBW	69.01±12.2[a]
(T2) Gentamicin 80 mg/kgBW + roselle extract 400 mg/kgBW	76.68±14.75[a]
(T3) Gentamicin 80 mg/kgBW + Roselle extract 600 mg/kgBW	72.8±19.66[a]

[a, b] Different superscripts showed significant differences between groups (P<0.05).

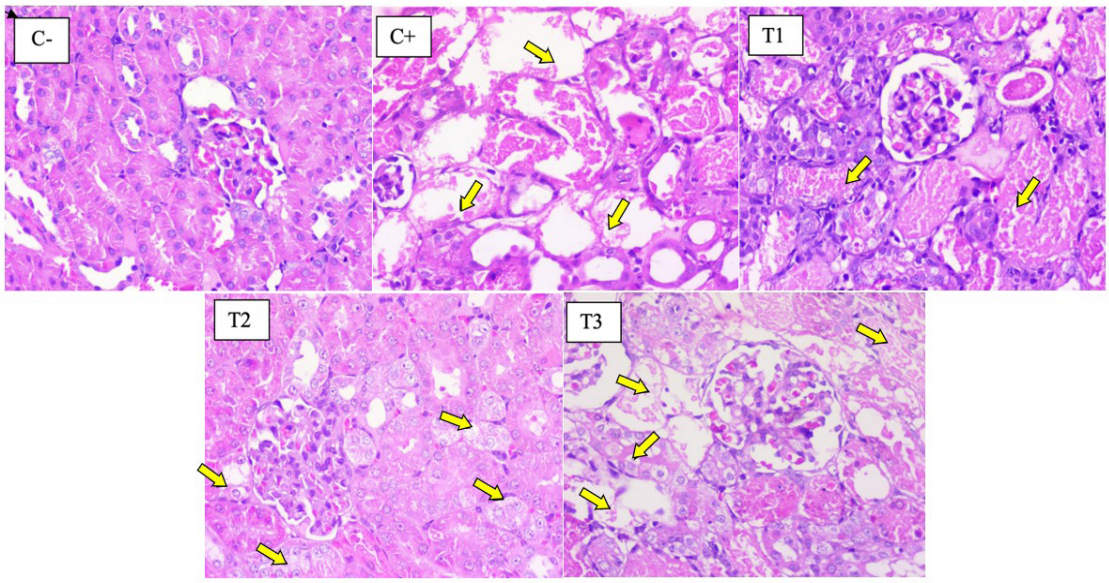

Figure 4. Histopathological images of renal insterstitial inflammation (H&E staining 400×)

Note: The yellow arrows (⇨)indicate inflammatory cell infiltration.

them, T1 (200 mg/kgBW) had the most consistent protective effect, lowering glomerular inflammation to 0.5±0.21 and keeping tubular degeneration at 1.83±0.41, the closest to C– values. T2 (400 mg/kgBW) showed a partial reduction in damage, with slightly higher scores in tubular degeneration (1.6±0.66) but similar improvements in glomerular necrosis (0.76±0.15). T3 (600 mg/kgBW), on the other hand, did not improve histology further; in fact, its glomerular inflammation score (1.33±0.21) and interstitial inflammation (2.2±0.46) approached or exceeded those of C+, suggesting that a higher dose might have pro-oxidant effects.

Gentamicin is also known to be toxic to the testes, and this study supports that observation: the C+ group showed marked thinning of seminiferous tubules, consistent with elevated ROS levels reported in testicular tissue [5]. In contrast, T1 preserved seminiferous tubule thickness closest to C–, while T2 showed moderate improvement and T3 less so.

Various studies have shown that gentamicin toxicity stems from the body's inability to eliminate excessive ROS [20]. This imbalance reduces follicle-stimulating hormone (FSH) and luteinizing hormone (LH) produc-

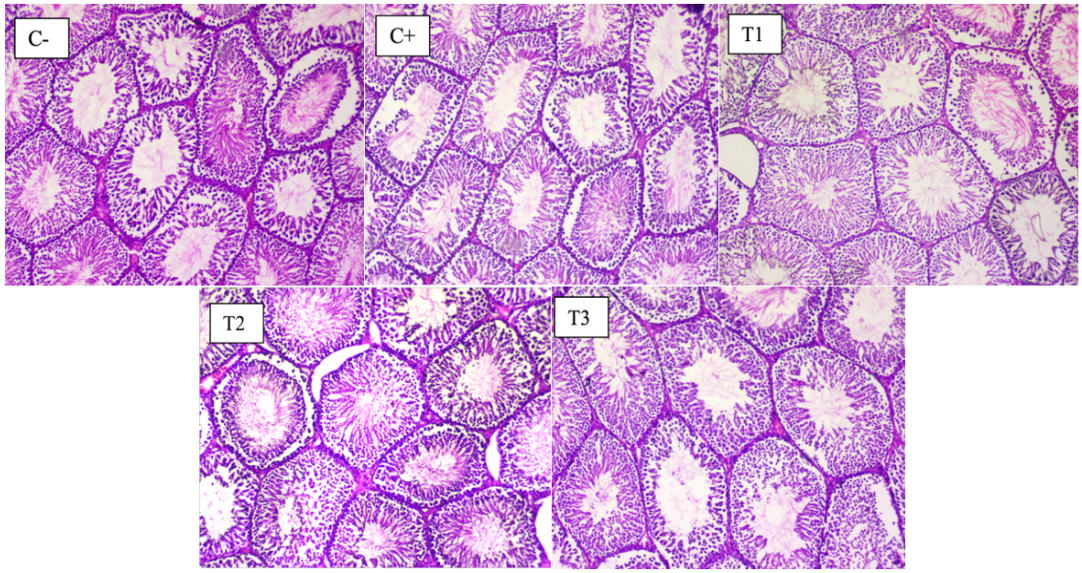

Figure 5. Histopathological images of renal insterstitial inflammation (H&E staining 400×)

tion, lowering sperm quality and causing seminiferous tubule thinning [21]. Gentamicin also diminishes endogenous antioxidants such as superoxide dismutase (SOD), catalase (CAT), and glutathione (GSH), further weakening the body's protective system [5].

The results of this study show that roselle (*H. sabdariffa*) extract, particularly at 200 mg/kgBW (T1), improved histopathological findings of renal degeneration, necrosis, and inflammatory cell infiltration, and also improved seminiferous tubule thickness in the testicular organ. Roselle flower extract is rich in bioactive compounds such as anthocyanins, flavonoids, and ascorbic acid, all of which function as antioxidants that inhibit lipid peroxidation and reduce oxidative stress [22]. Anthocyanins are known to enhance the activity of the body's natural antioxidant enzymes, including SOD, CAT, and GSH [23]. Flavonoids support the repair of damaged cell membranes and compete with unsaturated lipids as oxidative substrates, thereby minimizing cellular degeneration. Furthermore, vitamin C (ascorbic acid) is capable of neutralizing ROS such as superoxide anions ($O2^{+}$), hydrogen peroxide (H_2O_2), and hydroxyl radicals (OH^{-}), effectively preventing oxidative damage to cellular components and protecting against necrosis in both kidney and testes.

Anthocyanins present in Roselle flower also exhibit notable anti-inflammatory effects that contribute to the protection of kidney and testicular tissues. These bioactive compounds act by inhibiting the activation of inflammatory signaling pathways such as nuclear factor-kappa B (NF-κB), thereby suppressing the release of pro-inflammatory cytokines including interleukin-1β (IL-1β), tumor necrosis factor-alpha (TNF-α), and interleukin-6 (IL-6) [24]. The anti-inflammatory properties of roselle anthocyanins have been linked to the attenuation of cellular infiltration and oxidative stress, which are common pathological features in kidney inflammation models [25]. The anti-inflammatory activity of roselle flower extract is mediated by anthocyanins, which reduce the expression of pro-inflammatory cytokines like TNF-α, oxidative stress, and MDA levels, allowing endogenous antioxidants to function optimally [26]. In testicular damage models, these anthocyanins reduce apoptosis and preserve tissue architecture by enhancing endogenous antioxidant enzyme activity such as SOD and CAT [27].

5. Conclusion

By downregulating inflammatory mediators and enhancing the antioxidant defense system, Roselle anthocyanins help prevent cytokine-induced tissue injury, highlighting their therapeutic potential in renal and reproductive health. The discussion of *H. sabdariffa* extract mitigated gentamicin-induced kidney and testicular damage in rats by improving histopathological features and maintaining the structure of the seminiferous tubules. A dose of 200 mg/kg produced the most prominent effect, supporting the extract's potential as an antioxidant and anti-inflammatory agent against drug-induced organ toxicity.

Acknowledgements

The authors thank to Head of Division of Veterinary Clinic Faculty of Veterinary Medicine, Universitas Airlangga, Jl. Mulyorejo, Kampus C UNAIR, Surabaya, 60115, Indonesia, for the contribution in guiding and directing the authors to complete this research.

Compliance with ethical guidelines

Animal ethical approval was obtained from the Research Ethics Commission of the Faculty of Veterinary Medicine, Universitas Airlangga, Surabaya, Indonesia (Code: 1.Ke.118.12.2020).

Funding

This research did not receive any grant from funding agencies in the public, commercial, or non-profit sectors.

Authors' contributions

Conceptualization and study design: Wiwik Misaco Yuniarti and Devia Kurniawati Yoanita Kurniawati; Data acquisition: Issaura Vita Yulinda, Aldhia Safiranisa, and Ahmad Nasir Fachrudin; Statistical analysis: Mohamad Raviansyah Jawindra, Wiwik Misaco Yuniarti, and Bambang Sektiari Lukiswanto; Writing: Bambang Sektiari Lukiswanto and Mohamad Raviansyah Jawindra; Administrative, technical, and material support: Ratna Widyawati; Final approval: All authors.

Conflict of interest

The authors declared no conflict of interest.

Data availability

The data supporting the findings of this study are available in the research records conducted by researchers.

References

[1] Rashid U, Khan MR. Fagonia oliveri prevented hepatorenal injuries induced with gentamicin in rat. Biomed Pharmacother. 2017; 88:469-79. [DOI:10.1016/j.biopha.2017.01.088] [PMID]

[2] Jannat N, Amin T, Sultana N, Jahan MR, Islam MR. Long-term administration of gentamicin affects hemato-biochemical parameters and liver architecture of Swiss albino mice. J Adv Biotechnol Exp Ther. 2018; 1(2): 29-35. [DOI:10.5455/jabet.2018.d6]

[3] Al-Mashhadi AMM, Al-Sharafi NM. Protective Effects of Eugenol Against Iron Overload-induced Nephrotoxicity in Male Rats. Iran J Vet Med. 2025; 19(2):341-56. [DOI:10.32598/ijvm.19.2.1005540]

[4] Khan M.R, Badar I, Siddiquah A. Prevention of hepatorenal toxicity with Sonchus asper in gentamicin treated rats. BMC Complement Altern Med. 2011; 11:113. [DOI:10.1186/1472-6882-11-113] [PMID]

[5] Dogan T, Yildirim BA, Terim-Kapakin KA, Kiliclioglu M, Senocak EA. Protective effects of crocin against gentamicin-induced damage in rat testicular tissue: Modulating the levels of NF-κB/TLR-4 and Bax/Bcl-2/caspase-3 signaling pathways. Food Chem Toxicol. 2025; 200:115407. [DOI:10.1016/j.fct.2025.115407] [PMID]

[6] Elfaky MA, Thabit AK, Sirwi A, Fahmy UA, Bahabri RM, Al-Awad EA, et al. Development of a novel pharmaceutical formula of nanoparticle lipid carriers of gentamicin/α-tocopherol and in vivo assessment of the antioxidant protective effect of α-tocopherol in gentamicin-induced nephrotoxicity. Antibiotics. 2019; 8(4):234. [DOI:10.3390/antibiotics8040234] [PMID]

[7] Bagali RS, Jalalpure SS, Patil SS. Evaluation of Schrebera swietenioides Roxb. fruit ethanolic extract for antioxidant and hepatoprotective activity against CCl4 induced liver injury in rats. Res J Pharm Technol. 2020; 13(11):5115-20. [Link]

[8] Majee C, Mazumder R, Choudhary AN. Acute and subacute oral toxicity studies on aquatic plant Trapa natans L. using a rat model. Res J Pharm Technol. 2022; 15(7):2923-27. [DOI:10.52711/0974-360X.2022.00487]

[9] Almeer R, Alyami NM. Renal-protective effect of Asparagus officinalis aqueous extract against lead-induced nephrotoxicity mouse model. Environ Sci Pollut Res Int. 2023; 30(52):112745-57. [DOI:10.1007/s11356-023-30280-7] [PMID]

[10] Suleiman I, Ayo JO, Kawu MU, Tanko Y, Shittu M, Yakub LS. Antioxidant effect of co-administration of aqueous extract of Hibiscus sabdariffa Linn (Malvaceae) calyx and vitamin E on carbamazepine-induced testicular changes in adult Wistar rats. Int J Novel Res Life Sci. 2016; 3(2):35–43. [Link]

[11] Montalvo-Gonzalez E, Villagran Z, Gonzalez-Torres S, Iniguez-Munoz LE, Isiordia-Espinoza MA, Ruvalcaba-Gomez JM, et al. Physiological effects and human health benefits of Hibiscus sabdariffa: A review of clinical trials. Pharmaceuticals (Basel). 2022; 15(4):464. [DOI:10.3390/ph15040464] [PMID]

[12] Kianian F, Karimian SM, Kadkhodaee M, Takzaree N, Seifi B, Adeli S, et al. Combination of ascorbic acid and calcitriol attenuates chronic asthma disease by reductions in oxidative stress and inflammation. Respir Physiol Neurobiol. 2019; 270:103265. [DOI:10.1016/j.resp.2019.103265] [PMID]

[13] Ajiboye BO, Famusiwa CD, Nifemi DM, Ayodele BM, Akinlolu OS, Fatoki TH, et al. Nephroprotective effect of Hibiscus sabdariffa leaf flavonoid extracts via KIM-1 and TGF-1β signaling pathways in streptozotocin-induced rats. ACS Omega. 2024; 9(17):19334-44. [DOI:10.1021/acsomega.4c00254] [PMID]

[14] Zheng Z, Schmidt-Ott KM, Chua S, Foster KA, Frankel RZ, Pavlidis P, et al. A Mendelian locus on chromosome 16 determines susceptibility to doxorubicin nephropathy in the mouse. Proc Natl Acad Sci U S A. 2005; 102(7):2502-7. [DOI:10.1073/pnas.0409786102] [PMID]

[15] Arimbi, Azmijah A, Darsono R, Plumeriastuti H, Widiyatno TV, Legowo D. [Textbook of General Veterinary Pathology (Indonesian)]. 2nd ed. Surabaya: Airlangga University Press; 2015. [Link]

[16] Arab F, Naeimi S, Javaheri-Vayeghan A, Muhammadnejad A, Hamedani MA. [Protective Effect of Camel Milk on Gentamicin-induced Nephrotoxicity: From Renal Biomarkers to Histopathology Evidence (Persian)]. Iran J Vet Med. 2021; 15(1):79-92. [Link]

[17] Javed U, Khan M, Saleemi MK, Khan A, Javed I, Rafique S. Toxico-pathological effects of parenteral administration of gentamicin in growing broilers. Int J Agric Biol. 2013; 15(3):529-34. [Link]

[18] Randjelovic P, Veljkovic S, Stojiljkovic N, Sokolovic D, Ilic I. Gentamicin nephrotoxicity in animals: Current knowledge and future perspectives. EXCLI J. 2017; 16:388-99. [DOI:10.17179/excli2017-165] [PMID]

[19] Quiros Y, Vicente-Vicente L, Morales AI, Lopez-Novoa JM, Lopez-Hernandez FJ. An integrative overview on the mechanisms underlying the renal tubular cytotoxicity of gentamicin. Toxicol Sci. 2011; 119(2):245-56. [DOI:10.1093/toxsci/kfq267] [PMID]

[20] Aly HAA, Hassan MH. Potential testicular toxicity of gentamicin in adult rats. Biochem Biophys Res Commun. 2018; 497(1):362-7. [DOI:10.1016/j.bbrc.2018.02.085] [PMID]

[21] Mardatillah M, Wurlina W, Yudaniayanti IS, Primarizky H, Plumeriastuti H, Hamid IS. Moringa oleifera leaf extract restored the diameter and thickness of the seminiferous tubules of rat (Rattus norvegicus) injected with gentamicin. Ovozoa J Anim Reprod. 2022; 11:15-21. [DOI:10.20473/ovz.v11i1.2022.15-21]

[22] Triyastuti MS, Anwar N. Bioactive compounds from purple roselle calyx (Hibiscus sabdariffa L.) extract using multistage countercurrent method. Media Gizi Indones. 2022; 17(1):1-10. [DOI:10.20473/mgi.v17i1.1-10]

[23] Mattioli R, Francioso A, Mosca L, Silva P. Anthocyanins: A comprehensive review of their chemical properties and health effects on cardiovascular and neurodegenerative-diseases. Molecules. 2020; 25(17):3809. [DOI:10.3390/molecules25173809] [PMID]

[24] Sogo T, Terahara N, Hisanaga A, Kumamoto T, Yamashiro T, Wu S, et al. Anti-inflammatory activity and molecular mechanism of delphinidin 3-sambubioside, a Hibiscus anthocyanin. BioFactors. 2015; 41(1):58-65. [DOI:10.1002/biof.1201] [PMID]

[25] Gad FA, Farouk SM, Emam MA. Antiapoptotic and antioxidant capacity of phytochemicals from Roselle (Hibiscus sabdariffa) and their potential effects on monosodium glutamate-induced testicular damage in rat. Environ Sci Pollut Res. 2021; 28(2):2379-90. [DOI:10.1007/s11356-020-10674-7] [PMID]

[26] Bendokas V, Stanys V, Mazeikiene I, Trumbeckaite S, Baniene R, Liobikas J. Anthocyanins: From the field to the antioxidants in the body. Antioxidants. 2020; 9(9):819. [DOI:10.3390/antiox9090819] [PMID]

[27] Budin SB, Rahman WZ, Jubaidi FF, Yusof NL, Taib IS, Zainalabidin S. Roselle (Hibiscus sabdiriffa) polyphenol-rich extract prevents testicular damage of diabetic rats. J Appl Pharm Sci. 2018; 8(2):065-70. [Link]

This Page Intentionally Left Blank