Archives of Razi Institute Journal
"Arch. Razi Inst."

Journal Homepage: https://archrazi.areeo.ac.ir/

Research Paper

Investigating Types of Immunity and Histopathological Lesions in the Rat's Bladder Infected With *Trichosomoides crassicauda*

Hossein Komeijani Bezcheluee[1], Saloomeh Shirali[1, 2*], Saeed Hesaraki[1], Gholamreza Nikbakht Brujeni[3]

1. Department of Pathobiology, SR.C., Islamic Azad University, Tehran, Iran.
2. Department of Biotechnology, Ahv.C., Islamic Azad University, Ahvaz, Iran.
3. Department of Microbiology and Immunology, Faculty of Veterinary Medicine, University of Tehran, Tehran, Iran.

Use your device to scan and read the article online

How to cite this article Komeijani Bezcheluee H, Shirali S, Hesaraki S, Nikbakht Brujeni Gh. Investigating Types of Immunity and Histopathological Lesions in the Rat's Bladder Infected With *Trichosomoides crassicauda*. Archives of Razi Institute Journal. 2026; 81(4):943-954. https://doi.org/10.32598/ARI.81.4.3882

https://doi.org/10.32598/ARI.81.4.3882

Article info:
Received: 01 Jan 2026
Accepted: 22 Mar 2026
Published: 01 Jul 2026

Keywords:
Cystitis, Inflammatory cytokines, IL-4/IFN-Ɣ ratio, *Trichosomoides crassicauda*

ABSTRACT

Introduction: *Trichosomoides crassicauda* is a nematode residing in the bladder of rats. This study was conducted to investigate the experimental lesions caused by this nematode in the bladder wall.

Materials & Methods: Ten male Wistar rats, each with an average weight of 250 grams, were used for this study. The rats were divided into two groups: five were infected with *T. crassicauda* eggs, while the other five were left uninfected. Both groups were observed for 60 days following the egg inoculation. After this period, a necropsy was conducted to examine the bladder and liver for any gross lesions. Tissue samples, approximately 5 mm thick., were collected from the bladder and liver and preserved in 10% buffered formaldehyde. Additionally, the bladder samples were analyzed for the expression of genes associated with the cytokines tumor necrosis factor (TNF-α), Interleukin-1 beta (IL-1β), IL-4, interferon-gamma (IFN-γ), and IL-5.

Results: Hyperemia and catarrhal exudate were detected in the bladder mucosa of the infected group. However, no visible uroliths or tumoral lesions were observed. Microscopically, transitional epithelial cell hyperplasia with edema and an influx of small to moderate mononuclear leukocytes, mainly of the lymphoid lineage, were observed. In the infected group, the expression of the inflammatory-immune genes *TNF-α*, *IL-1β*, *IL-4*, *IL-5* and *IFN-Ɣ* intake was higher in comparison to the sham group. The IL-4/IFN-Ɣ ratio was increased.

Conclusion: *T. crassicauda* caused minor tissue changes accompanied by significant expression of inflammatory cytokines related to Th2 dominance, and cellular immunity (IFN-Ɣ) probably does not play a role in the immune response in rats infected with *T. crassicauda*.

*** Corresponding Author:**
Saloomeh Shirali, Assistant Professor.
Address: *Department of Pathobiology, SR.C., Islamic Azad University, Tehran, Iran.*
E-mail: *s.shirali2017@gmail.com*

Copyright © 2026 The Author(s);
This work is licensed under a Creative Commons Attribution-NonCommercial 4.0 International license (https://creativecommons.org/licenses/by-nc/4.0/).
Noncommercial uses of the work are permitted, provided the original work is properly cited.

1. Introduction

Trichosomoides crassicauda is a nematode worm that resides in the bladder of rats and that, through its direct life cycle, can spread among rats in a geographic area or breeding area through ingestion of food and water contaminated with urine containing embryonated eggs [1]. Upon ingestion of embryonated eggs in the gastrointestinal tract, these eggs hatch in the stomach into larvae that invade the stomach wall and travel to the nearest blood vessel to migrate via the bloodstream to the urinary system, such as the kidneys and bladder, as well as the lungs [1, 2]. Although the worm's larvae cannot cross the placental barrier, infection occurs in newborns when the feed or water they consume is contaminated with maternal urine. Newborn rats can also become infected through milk [3]. In a pathological study conducted by Ozkorkmaz et al. in 2011 on diabetic-infected rats with *T. crassicauda*, it was reported that the presence of large numbers of *T. crassicauda* in the transitional epithelium of the bladder wall can induce multiple papillomas and epithelial tissue degeneration [3]. The presence of large numbers of *T. crassicauda* over a long period can be accompanied by granulomatous inflammation, which is accompanied by a significant presence of eosinophils and through the growth factors that are released, it increases the proliferation of transitional cells of the bladder. This condition may predispose the bladder to cancer through carcinogen-promoted mechanisms [3-5]. Infection of laboratory white rats with *T. crassicauda* is usually subclinical. However, interfere with various types of academic, especially in cases of inflammatory research or research work on the kidneys. Therefore, identifying, diagnosing, and managing these rats' breeding sites is critical in academic research [6].

Th1 immunity protects against viruses, tumor cells, and microorganisms that live inside cells by using cytotoxic T cells, NK cells, activated macrophages, and antibodies from B cells. The main cytokine that starts the differentiation and growth of Th1 cells from Th0 lymphocytes that have not yet recognized an antigen is interleukin 12 (IL-12) [7]. Th1 cells produce high levels of interferon gamma (IFN-γ), which protects the Th1-shifted immune pathway and is also the best cytokine for fighting Th2 immunity. IL-4 is a typical Th2 cytokine that protects against extracellular microorganisms. B cells, eosinophils, and basophils are the main cells in Th2 immunity. In the case of Th2-leading, high levels of IL-4, IL-5, and IL-10 can be produced, leading to allergic IgE-mediated reactions or autoimmunity caused by specific autoreactive antibodies [7, 8]. Simultaneously, IL-4 acts as the primary opposing cytokine that prevents the immune response from shifting towards Th1 immunity [7, 9]. The type of immune response in the *T. crassicauda* infection in laboratory animals regarding Th1- or Th2-dominant immune responses is still insufficient. Therefore, the present study tried to work on the type of cytokine response in the bladder wall and the histopathological changes associated with *T. crassicauda*.

2. Material and Methods

2.1. The parasite *T. crassicauda* and its eggs

T. crassicauda is a nematode worm that resides in the bladder of rats and which, through its direct life cycle, can spread among rats in a geographic area or breeding area through ingestion of food and contaminated with urine containing embryonated eggs. Upon ingestion of embryonated eggs in the gastrointestinal tract, these eggs hatch in the stomach and hatch into larvae that invade the stomach wall and penetrate the stomach wall, enter nearby blood vessels, and migrate via the bloodstream such as the kidneys and bladder, as well as the lungs.

2.2. Experiment

2.2.1. Rats

In this study, ten male Wistar rats with an average weight of 200 grams were housed in an animal cage with a 12-hour light/dark cycle. Fresh airflow was maintained, and the temperature was kept between 22 and 25 degrees Celsius. The rats had free access to commercial pellets and water. Five rats were infected with *T. crassicauda* eggs, while five others were not, and both groups were kept for 60 days after the egg inoculation.

2.2.2. Induction of infection

Ten female worms containing embryonated eggs were lysed in a Potter-Elvehjem homogenizer containing 1 mL of water in a cylinder and centrifuged at 800 rpm three times at 2 s each. The number of embryonated and non-embryonic eggs was counted in 10 µL aliquots of the homogenized suspension. Each rat was orally infected with 100 embryonated eggs [10].

2.3. Necropsy and sampling

According to the principles of ethics for working with laboratory animals, the animals were anesthetized by placing them in a chamber containing 70% carbon dioxide gas 60 days after induction of the infection by the

Table 1. The bladder tissue histopathological scoring

Score	Transitional Epithelium	Edema	Leukocyte Infiltration (×400)
0	<4 cells	Absent	<5 cells
1	4-cell layer hyperplasia	Low	5-15 cells
2	5-6-cell layer hyperplasia	Moderate	15-25 cells
3	6-cell layer hyperplasia <	High	25 cells <

egg inoculation. They were then euthanized by increasing the gas concentration to 100% and then necropsied. The urinary system was assessed, and the bladder was meticulously excised and placed in a Petri dish with physiological serum. The bladders were placed separately under a stereomicroscope to observe the worms. The nematodes were identified by counting them and using methods to diagnose helminth parasites based on their appearance.

2.4. Pathology

2.4.1. Sampling

The 0.5 cm bladder and liver samples were fixed for seven days in 10% formalin buffer. Then, hematoxylin-eosin (H&E) staining was performed and evaluated.

2.4.2. Macroscopy

Thread-like worms up to 10 mm in focal mucinous cysts or free in the lumen of the bladder were looked for. There was no apparent tumor, or bulged mass in the mucosal surface of the bladders. So, the degree of focal hemorrhages and mucous catarrhal exudate in the bladders of both groups was scored from 0-3 as 0: absent, 1: mild, 2: moderate, and 3 = serve. The pathology score for each group is presented as the sum of the grades of all lesions. Livers were also compared descriptively, considering the lack of scoreable lesions only in terms of hemorrhage and granuloma foci.

2.4.3. Microscopy

The liver and bladder tissues of rats were examined histopathologically. Lesions in the bladder were examined for edema, hyperplasia, and ulceration, and in the liver for degeneration, necrosis, inflammation, and granulomatous process. Bladder and liver tissues were scored and compared according to Tables 1 and 2. The pathology score for each group is presented as the sum of the grades of all lesions.

2.5. Gene expression

2.5.1. Tissue homogenization

Half of each bladder was homogenized for the gene expression assays. Homogenization was performed using a tissue homogenizer after the samples had been diluted in four volumes of homogenate buffer (HEPES, KCl, EGTA, DTT). Bladder homogenates were centrifuged at 3000 g for 15 min, and the supernatants were stored. supernatants were stored at −70 ˚C until the molecular assays could be performed.

2.5.2. RNA extraction

RNA extraction was performed using RNX PLUS solution (Sina Gene - Iran). For this purpose, 100 µL of homogenized tissue was added to 1000 µL of RNX PLUS solution, vortexed, and 200 µL of chloroform was added. After being placed on ice (5 min), the solution was centrifuged at 13,000 rpm (15 min). Isopropanol was added to a new tube with an equal volume to the supernatant and shaken.

The solution was stored at -20 ˚C (6 h) and centrifuged at 13000 rpm (15 min), and the supernatant was carefully discarded. Next, 1 mL of 75% ethanol was added to the sediment pellet and centrifuged at 7500 rpm for 8 minutes. The supernatant was discarded, and after the sediment pellet dried, 50 µL of diethylpyrocarbonate (DEPC) water was added to dissolve it, and it was placed in a -80 ˚C freezer.

2.5.3. cDNA synthesis

Sterile, RNase-free 0.2 mL microtubes were prepared on a cold rack for RNA samples. Then, melt the enzyme buffer at room temperature, and if sediment was observed in it, it was dissolved by vortexing. 2 ug Pure RNA, 10 uL PDB (2x), 2 uL RT Enzyme, were poured into a 0.2 microtube. Finally, by adding DEPC water, the final volume reached 20 µL. In the next step, after mixing the materials mentioned above, the lids of the micro-

Table 2. The liver tissue histopathological scoring

Score	Lobular Necrosis (×400)	Lobular Vacuolar Degeneration	Leukocyte Infiltration in Lobule and Triad (×400)	Number of the Granuloma (×100)
0	<5 cells	Randomly	<5 cells	0
1	5-10 cells	<25%	5-15 cells	1
2	10-15 cells	25-50%	15-25 cells	2
3	15-20 cells	50-75%	25-50 cells	3
4	20 cells <	75% <	50 cells <	4

tubes were closed and placed in the thermocycler block according to the temperature program of 16 (5 min), 30 (5 min), 45 (50 min), and 80 (5 min).

2.5.4. Specific primers for reverse transcription polymerase chain reaction

In this study, the beta-actin gene was utilized as an internal control after acquiring its sequence and the primers for cytokines *TNF-α*, *IL-1β*, *IL-4*, *IFN-Ɣ*, and *IL-5* genes from the NCBI site, as well as the specific gene sequences for each gene, the sequences of the primers were designed using the Primer Express program and the primer sequences were blasted to confirm their accuracy and specificity. The primer sequences are shown in Table 3.

2.5.5. Realtime PCR

To make a 20 µL reaction, the following materials were poured into a 0.2 microtube in the following order: 10 µL of Cybergreen Recombinant Redimix (Cat Number: NAT007) Master Mix, 2 µL of 10 pmol forward primer and 2 µL of 10 pmol reverse primer, 2 µL of template DNA, 6 µL of PCR grade water. After pouring all the ingredients, the strip lid was closed and they were spun. The temperature protocol consisted of an initial denaturation at 95 ˚C for 3 min, followed by 35 cycles of denaturation at 95 ˚C (30 s), annealing at 61 ˚C (30 s), polymerization at 72 ˚C (50 s), and final polymerization at 72 ˚C (5 min).

Table 3. Primers for genes related to inflammatory cytokines

Primer	Sequence	Molecular Weight
TNF-α - F	TTGGGTTCTCTTGGCTGTTA	251 bp
TNF-α - R	TTCTGTCASTSTSTSTSSSA	
IL-1β - F	CCAGGATGAGGACCCAAGCA	519 bp
IL-1β - R	TCCCGACCATGCTGTTTCC	
IL-4 - F	GCCTCCAAGAACACTGA	223 bp
IL-4 - R	ACGTACTCTGGTTGGCTTCC	
IL-5 - F	TGGCAGAGACCTTGACACTG	242 bp
IL-5 - R	CCATCTTTCCCCTCCACAAT	
IFN-Ɣ - F	TTGGGTTCTCTTGGCTGTTA	151 bp
IFN-Ɣ - R	TTCTGTCASTSTSTSTSSSA	
β-actin F	AGAAAATCTGGCACCACACC	395 bp
β-actin R	STSSTTAATGTCACGCACGA	

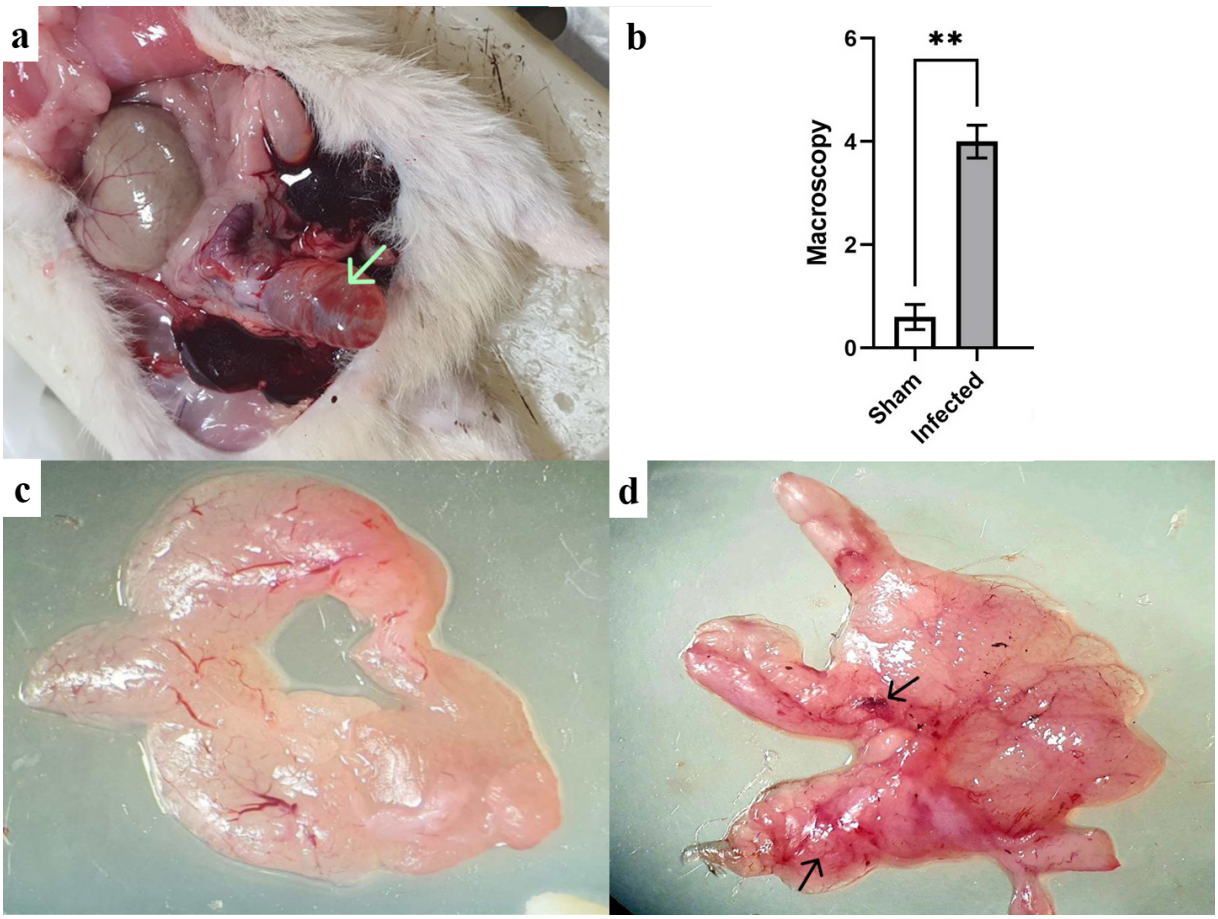

Figure 1. Gross appearance of the rat bladders: Serosal surface of infected (a) and mucosa of the sham (c) and infected (d) groups

**P<0.01.

Note: Hyperemia and hemorrhage (arrows) could be seen in the wall of the infected bladder. Comparison diagram (b) revealed the significant differences between sham and infected groups.

2.5.6. IL-4 /IFN-γ ratio

IFN-γ is a typical Th1 cytokine, while IL-4 is a typical Th2 cytokine with antagonistic properties. So, IL-4/IFN ratios show changes in the number of Th2 cells compared to Th1 cells when studying the type of immune response in a tissue or culture [7].

2.6. Statistical analysis

Non-parametric statistical tests were performed using Graph Pad Prism 9.0 software for histopathological scoring. The significance of inter-individual differences was established with P-values categorized as follows: less than 0.05 ($P \leq 0.05$), less than 0.01 ($P \leq 0.01$), less than 0.001 ($P \leq 0.001$), and less than 0.0001 ($P \leq 0.0001$). Finally, the data are presented as Mean±SEM.

3. Results

3.1. Clinical findings

All infected rats showed normal behavior without any obvious clinical signs.

3.2. Pathological findings

3.2.1. Macroscopic appearance

The serous surface (Figure 1a) of the bladder showed marked hyperemia, and the mucosal surfaces (Figures 1c and 1d) showed slight hemorrhages. Significant histopathological differences were observed between the sham and infected groups in scoring bladder wall lesions (Figure 1b).

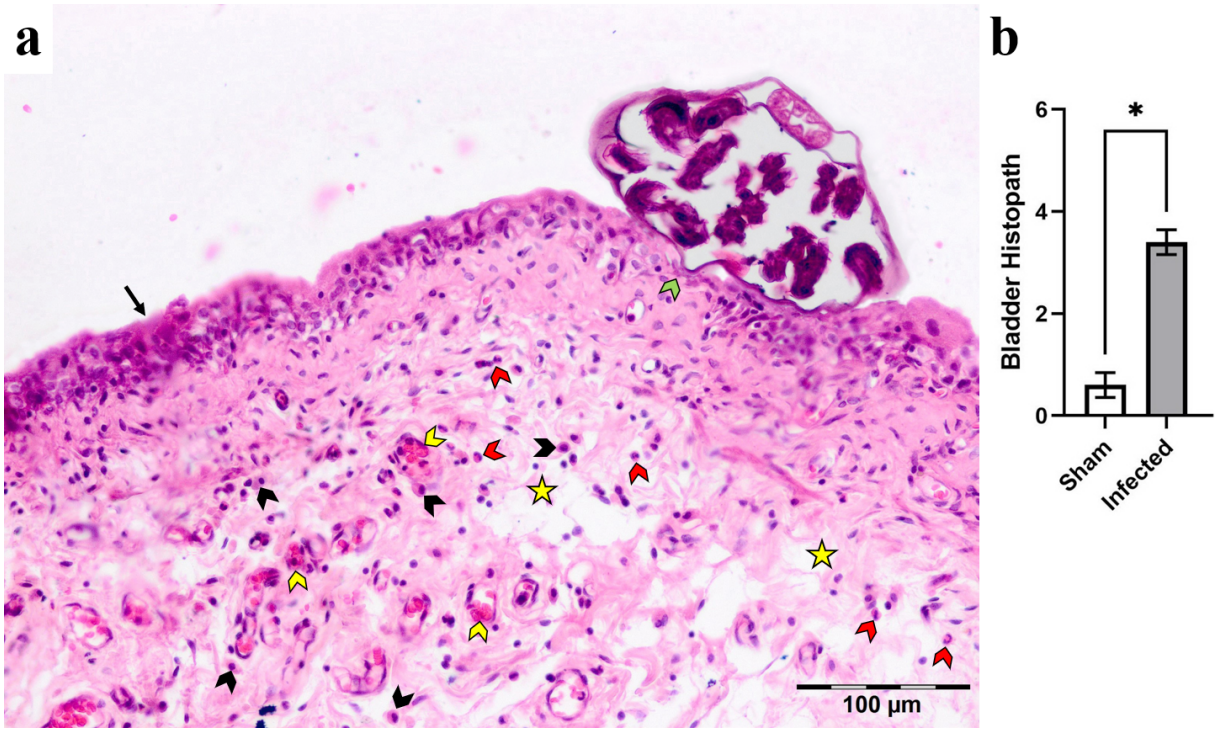

Figure 2. Cross section of the Infected rat bladder tissue (a) and comparative diagram (b)

*P<0.05.

Note: Hyperemia (yellow arrowheads), edema (stars), epithelial hyperplasia (arrow), epithelial atrophy (green arrowhead) adjacent to sectioned nematode, mast cells (black arrowheads), and eosinophils (red arrowheads), could be seen (H&E×200).

The liver did not show noticeable gross changes. However, in a rat of the infectious group, there were some pinpoint focal discolorations.

3.2.2. Microscopic appearance

3.2.2.1. Bladder

Significant histopathological differences were observed between the sham and infected groups in scoring bladder wall lesions (Figure 2a). The bladder epithelium of sham rats consists of three cell layers: cuboidal or columnar basal cells, intermediate cells, and superficial squamous cells. In infected rats, the epithelium exhibits 4 to 5 cell layers. Edema and hyperemia were present with chronic mononuclear infiltration, mainly lymphocytes and plasma cells, without the expected presence of eosinophil infiltration in the bladder submucosa. Parasites were lying in the intraepithelial cystic space with intrauterine immature and embryonated eggs. The adjacent cells showed atrophic and necrotic appearance (Figures 2c and 2d). The comparison diagram for histopathology (Figure 2b) revealed the significant differences between sham and infected groups (P<0.05).

3.2.2.2. Liver

The number of mononuclear (Kupffer) cells was normal, and no pathological changes, necrosis, or degeneration were observed in the liver of the sham group (Figure 3a). In the infected group, however, irregular arrangement of hepatic cords, focal necrosis of hepatocytes, slight vacuolar degeneration, infiltration of inflammatory cells mainly of the macrophage and eosinophil type in the lobules, along with large amounts of lymphoid lineages in the lobules and portal spaces were observed. Of course, numerous granulomas were formed within the lobules with the invasion and accumulation of macrophages (Figures 3c and 3d). Comparison diagram for histopathology (Figure 3b) revealed the significant differences between sham and infected groups.

3.3. Bladder tissue inflammatory cytokines

The results showed that all cytokines, even IFN-Ɣ, were significantly increased in the infected compared to the sham groups (P<0.0001). The inflammatory cytokines TNF-α and IL-1β, along with cytokines indicating TH2 activity (IL-4 and IL-5), were increased more than IFN-Ɣ (P<0.0001) (Figure 4). There was a significant

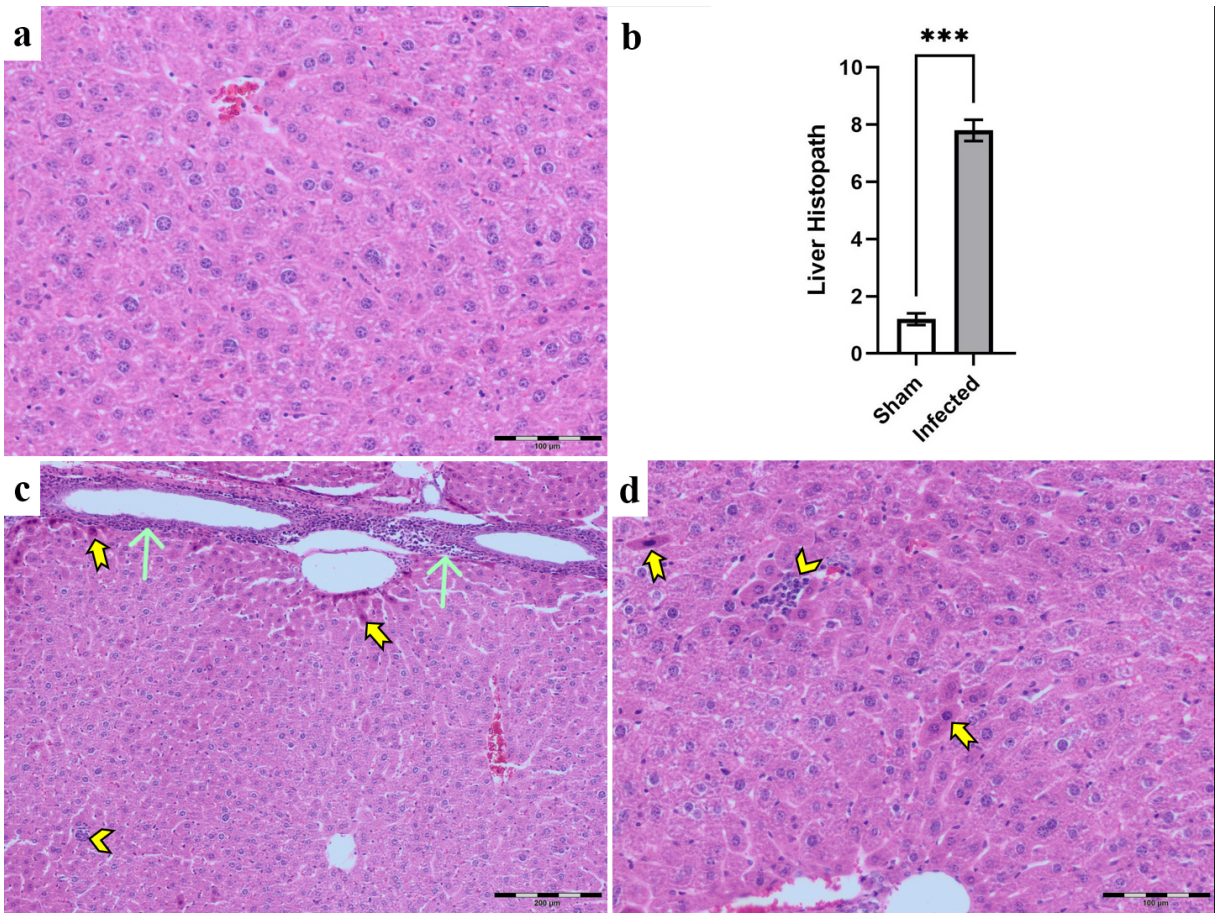

Figure 3. Cross section of the rat liver

Sham (a) and Infected (c, d) groups and comparison diagram (b) for histopathology.

***P<0.001.

Note: Although the sham group exhibited normal structure, the infected group displayed necrosis (notched arrows), leukocyte infiltration (arrows), and microgranuloma formation (arrowhead) (H&E, a, d: ×200, c: ×100).

difference between the sham and infected groups in the ratio of IL-4 /IFN-ɣ in the bladder tissue of this study (P<0.05) despite the non-significant ratio of IL-5 /IFN-ɣ (Figure 5).

4. Discussion

One of the important parasitic agents in the urinary system of laboratory rats is the nematode *T. crassicauda*. Bellingham first reported and described this parasite in 1840 in wild and laboratory rats as a non-pathogenic worm [11]. Diagnosis of *T. crassicauda* infection in laboratory rats is not as easy as with other nematodes because they mostly penetrate the bladder tissue unless sections of the parasite are observed in the bladder tissue after sample preparation by performing histopathology or worms inside the bladder have not yet penetrated the bladder wall, in which case they will be visible under a stereomicroscope. Finding parasite eggs in the adult worm and the animal's urine aids in diagnosis, although this is not always possible [3]. Cornish et al. in 1988 reported that female *T. crassicauda* worms often contained embryonated eggs, often accompanied by segments of male worms that had pierced the bladder mucosa and were visible by histopathological examination [4]. Bahrami et al. reported that around 56.72% of laboratory rat bladders in Ahvaz University were infected with the worm *T. crassicauda*. A significant disparity existed between female and male animals, with males demonstrating a greater prevalence of infection [12].

Rothenburger et al. in 2019 reported that the most prevalent microscopic issues in rats in Vancouver were chronic pneumonia, cardiomyopathy, and thyroid hyperplasia. Additionally, *T. crassicauda* in the bladder, *Eucoleus* sp., and *Capillaria hepatica* were the main in-

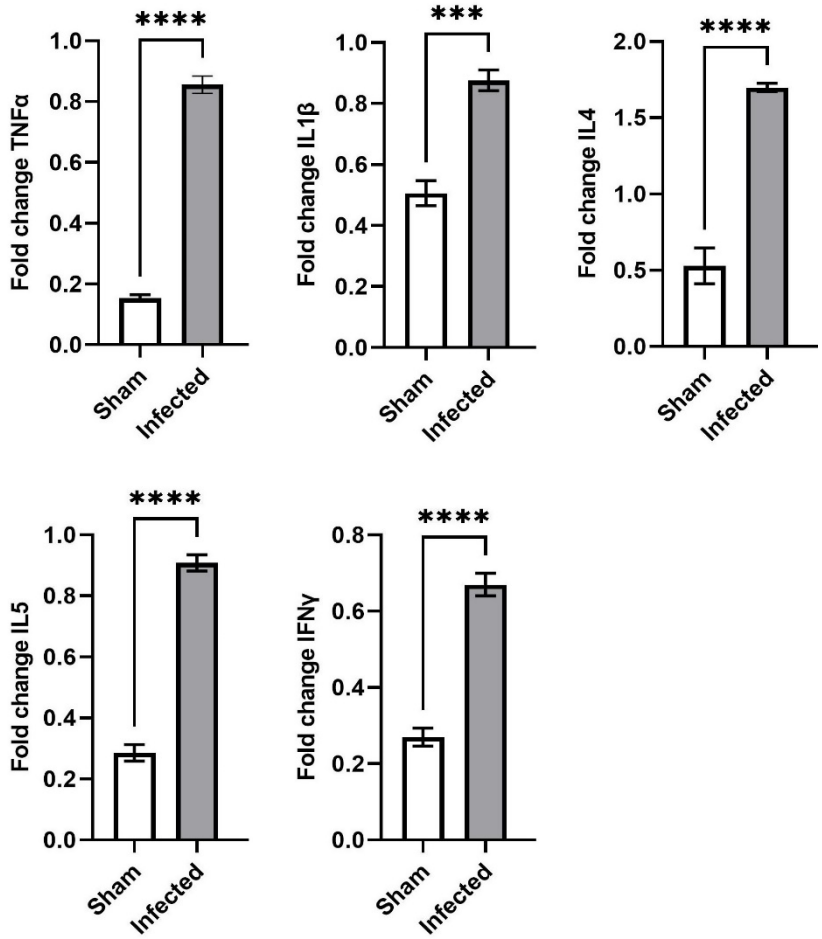

Figure 4. Effects of *T. crassicauda* infection on inflammatory cytokines in the bladder

***P<0.001, ****P<0.0001.

Note: The mRNA levels of TNF-α (a), IL-1b (b), IL-4 (c), IL-5 (d), and IFN-γ (e) were evaluated using RT-PCR

fections due to nematodes. The congenital, degenerative and neoplastic diseases were uncommon [13]. Najafi et al. investigated urine and bladder tissue (necropsy) for *T. crassicauda* eggs and bodies, respectively. Out of 112 pee samples obtained on one day, 16 tested positive for eggs. Conversely, out of 214 rat bladders, 114 harbored *T. crassicauda* worms. Transitional hyperplasia with edema of the wall and even metaplasia toward squamous epithelium were described as microscopic lesions in the bladder. Female worms with egg-bearing uteri were located in the epithelium. Despite its common infection, Najafi concluded that urine tests cannot identify *T. crassicauda* [14].

In Antonakopoulos et al.'s 1991 study on the effects of *T. crassicauda*, the bladder epithelium of infected rats showed diffuse hyperplasia, 4 to 6 cells thick. Inside the bladder's hyperplastic epithelium, tubes held the front and back parts of the female worms. The inner layer of the tunnel wall was made up of hyperplastic epithelial cells. Some epithelial cells had pyknotic nuclei and fibro-granular cytoplasm close to the parasite, but there was no clear plasma membrane on the surface next to the lumen [15]. Sarakides et al. in 2001 revealed, bladders containing variable amounts of parasites were observed, along with epithelial cell hyperplasia and inflammation, with or without urinary stones [16]. OzKorkmaz (2011) showed that in diabetic rats infected with *T. crassicauda*, the bladder epithelium had inflammation, hyperplasia, and papilloma [3]. In this study, diffuse and mild epithelial hyperplasia was observed in the bladder, with a moderate degree of hyperplasia noted in areas where worms were present. Additionally, no tumors or papillomas were found.

In their 1991 study on the effects of *T. crassicauda*, Antonakopoulos et al. found that when adult nematodes of *T. crassicauda* were fed on the transitional epithelium of

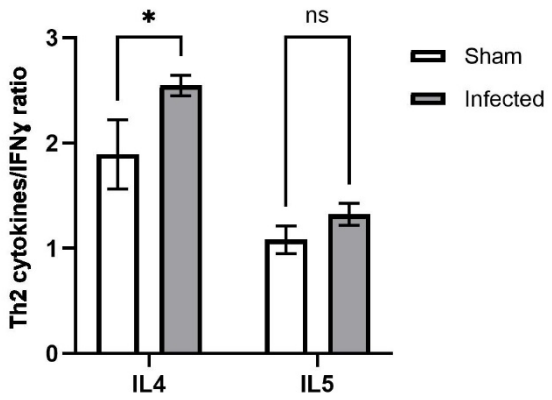

Figure 5. Effects of *T. crassicauda* infection on IL-4 and IL-5 / IFN-γ ratio

Ns: Non-significant.

*P<0.05; **P<0.01; ***P<0.001; ****P<0.0001.

the bladder, there was no increase in the number or types of inflammatory cells present in the submucosa propria. It is thought that the hyperplastic epithelium keeps adult *T. crassicauda* away from the bladder's blood vessels, creating a "protected site" for the worm that stops the body from having a strong, long-lasting inflammatory response [15]. Bahrami et al. (2014) also demonstrated that the parasites induced histopathological lesions, including hyperplasia, ulceration, and eosinophilic cystitis [12].

In the histopathological report of bladders infected with *T. crassiccauda* by Sikora et al. in 2022, bladder edema, necrosis of the urothelium in the areas adjacent to the worm, and local hyperplasia around it were mentioned. The worms and eggs were enclosed by transitional epithelial cells. The adjacent cells had dystrophic and necrotic changes. The desquamation increased the local permeability of the mucous layer. The worms were located in the lamina propria and submucosa without inflammatory reaction above or between the rugae. Despite the direct contact of the nematode eggs with the lamina propria, single immune cells were observed only in a few rats. As can be seen in the reports of various researchers, despite the extensive changes in the urothelium, the connective tissue underneath did not undergo many pathological changes, and even the presence of leukocytes was rarely reported [17]. In the present study, to determine the severity of inflammation and the type of response to the presence of this type of parasite in the bladder, it was determined that in addition to urothelium, changes in the submucosal tissue were also seen, albeit mildly, including edema, the presence of mononuclear leukocytes with a small number of eosinophils. These results were justified by the evaluation of inflammatory cytokines T and T with increased expression of their genes. Therefore, the present results were obtained in confirmation of other reports regarding epithelial tissue changes and in contrast to some reports about inflammatory changes in the submucosal tissue.

The IL-4 and IFN-Ɣ are contra-regulatory cytokines, and IFN-Ɣ is a typical Th1 cytokine, and IL-4 is a typical Th2 cytokine [7, 18]. Therefore, we can determine which of these two pathways is more enhanced or depressed based on their ratio. The balance of Th1 and Th2 subsets is implicated in the regulation of many immune responses. The Thl-type cytokines IFN-y and TNF-a are required for response against intracellular infections, while Th2 cells (secreting IL-4, IL-5 and IL-10) are responsible for protection against extracellular ones [7].

Thl cytokines have also been implicated in the pathogenesis of autoimmune diseases and/or their animal models, such as multiple sclerosis [19], diabetes mellitus [20] and rheumatoid arthritis [21] in which a T-cell response against an unknown self-antigen may play a role. In contrast, the Th2 related cytokines IL-4 and IL-10 downregulate inflammation in these models. Th0 and Th1 lymphocytes produce the cytokine IFN-Ɣ, with the difference that Th0 clones also produce the cytokine IL-4. Both Th0 and Th1 are cytotoxic [7].

IFN-Ɣ and IFNα have been shown to greatly reduce the production of IgE and the expression of the IgE type II receptor (FcεRII/CD23) when IL-4 is present. They are not thought to be useful in combating parasites [22]. A study by Wen et al. (2024) found that taking zinc sup-

plements can lower the autoimmune response against the intestinal wall. This is done by increasing Th2 cells, decreasing Th1 and Th17 cells, and raising blood levels of IL-1β and IL-18. They showed that Th2 and Th1 cytokines have antagonistic effects. Their discovery was through the reduction of the NF-kB/NLRP3 signaling pathway [23].

In a study conducted by Yasen et al. in 2021, it was found that the Th1/Th2/Th2 cytokine profile was associated with the stages of tissue-resident hydatid cysts. In hepatic echinococcosis patients with inactive cysts, Th1 and Th17 cytokines were dominant, while Th2 cytokines were more prominent in hepatic echinococcosis patients with active cysts. They showed that Th1 and Th17 more strongly mediated parasite restriction [24].

Several studies have indicated that elevated levels of IL-4 are linked to protection against severe malaria, and that IL-4 promotes the development of protective antibody responses against malaria in humans and mice who have been immunized [18, 25].

Using a fully permissive murine filariasis model, Al-Qaoud et al. looked into how IL-5 helps remove helminths in living animals. They infected BALB/c mice with *Litomosoides sigmodontis*. By inhibiting IL-5, eosinophils and neutrophils could not accumulate at the worms' site, resulting in weak inflammatory nodules around them, which allowed for their survival. They proposed that IL-5 might indirectly contribute to parasite death by elevating granulocyte-colony stimulating factor (G-CSF), TNF, and IL-8 while reducing IL-10 levels [26].

Takamoto et al. attempted to find the IL-5 role in resistance to Toxocara by infecting genetically IL-5-deficient mice with embryonated *Toxocara canis* eggs. Takamoto reported that fewer eosinophils infiltrated infected mice's lungs, liver, heart, and skeletal muscle. Consequently, *T. canis* larvae do not produce an IL-5-like molecule, and IL-5 produced by host cells is solely responsible for eosinophilia in mice infected with this nematode. The number and location of *T. canis* larvae did not change the IL-5 deficient condition. Takamoto's results indicated that eosinophils reduce lung and liver histopathology with *T. canis* [27].

Elevated levels of inflammatory cytokines TNF-α and IL-1β indicated a more severe inflammatory state in the infected group. This logic was consistent with microscopic observations, where edema and a slight presence of leukocytes were observed under the microscope.

Based on the studies referenced in recent cases, it concluded that Th1 leadership plays a more effective role in combating various infections, particularly parasitic ones, compared to Th2 leadership and the cytokines it produces. In instances where Th2 activity is more pronounced, there is likely to be a decline in the body's resistance and a reduction in inflammatory cascades. The present study found that parasites in the bladder wall elicited the lowest inflammatory response, which may be attributed to the dominance of IL-4, indicating a preference for Th2 leadership. Also, the low expression of IL-5 compared to IFN-ɣ in the infected group and its lack of significant difference with the control group can explain the lack or small presence of eosinophil cells in the bladder wall tissue.

Taulescu et al. (2011) observed and described white masses that were caused by granulomatous reactions. Migration of the larval stage of the parasite from the tissues of the lungs, liver, and kidneys causes the formation of bleeding pathways and chronic granulomatous inflammation with the invasion and infiltration of macrophages in these organs [28]. In the present study, liver tissue was evaluated, and it was observed that foci of granulomatous inflammation were visible in what previous studies have investigated. Also, a large influx of various leukocytes and polymorphonuclear cells was seen in the portal space.

In a 2021 immunohistochemical study by Sikora et al., it was highlighted that CD3 (T lymphocytes) and CD20 (B lymphocytes) were only found in small, isolated clusters around the worms and eggs in the bladder mucosa. This finding confirmed the lack of inflammatory infiltration related to the parasite. Similarly, in the present study, the inflammatory response was also weak and characterized as TH2 type [17].

5. Conclusion

The results of this study are consistent with the observations of other studies in terms of the type of parasite, its presence in the bladder and its tissue, and the occurrence of granulomatous reactions. By observing the parasite remains in the center of the formed cysts, it was determined that the cause of the cysts was due to the host's defense reaction. Because of the high level of contamination in Iranian lab rats, which is caused by not having any quarantine programs or following health and management rules (like keeping colonies too close together) and using breeding systems without protective dams, the management and breeding structure need to be improved. Health should be checked regularly to ensure the animals are as clean as possible.

Improving the quality of laboratory rodents requires barrier systems, controlled environmental conditions, and regular health monitoring. Because numerous helminth infections occur, particularly in lab rats, and because TH2 plays a crucial role in many immune responses against nematode infections in these animals, we chose to investigate a *T. crassicauda* infection. Our study revealed that the histopathological lesions were mild, and the level of inflammation was not significant. The extent of necrosis and epithelial hyperplasia was not severe, despite the worms' presence in the epithelial layer. However, in the case of the liver, we found that the lesions were more pronounced, characterized by a substantial influx of mononuclear and multinuclear leukocytes. Furthermore, areas of macrophage accumulation in the liver parenchyma indicated granulomatous inflammation.

Acknowledgements

The authors wish to thank Mohammad Abedi for doing the histological processing.

Compliance with ethical guidelines

This study was approved by the Research Ethics Committee of Science and Research Branch, Islamic Azad University, Tehran, Iran (Code: IR.IAU.SRB.REC.1403.245).

Funding

This research did not receive any grant from funding agencies in the public, commercial, or non-profit sectors.

Authors' contributions

Conceptualization and study design: Saeed Hesaraki; Experiments: Saeed Hesaraki; Data acquisition: Saloomeh Shirali; Data analysis and interpretation: Saloomeh Shirali and Hossein Komeijani Bezcheluee; Writing: Saeed Hesaraki and Hossein Komeijani Bezcheluee; Materials support: Gholamreza Nikbakht Brujeni.

Conflict of interest

The authors declared no conflict of interest.

Data availability

All data analyzed during this study are included in this published article.

References

[1] Bone JF, Harr JR. Trichosomoides crassicauda infection in laboratory rats. Lab Anim Care. 1967; 17(3):321-6. [Link]

[2] Bowman MR, Paré JA, Pinckney RD. Trichosomoides crassicauda infection in a pet hooded rat. Vet Rec. 2004; 154(12):374-5. [DOI:10.1136/vr.154.12.374] [PMID]

[3] Ozkorkmaz EG. Microscopic investigations in a diabetic rat urinary bladder infected with Trichosomoides crassicauda. J Electron Microsc (Tokyo). 2011; 60(4):261-5. [DOI:10.1093/jmicro/dfr012] [PMID]

[4] Cornish J, Vanderwee MA, Findon G, Miller TE. Reliable diagnosis of Trichosomoides crassicauda in the urinary bladder of the rat. Lab Anim. 1988; 22(2):162-5. [DOI:10.1258/002367788780864385] [PMID]

[5] Juhász A, Tóth T, Eldridge CJL, Majoros G. The first survey of endoparasite infection in the brown rat (Rattus norvegicus) from a synanthropic environment in Hungary. Vet Parasitol Reg Stud Rep. 2024; 56:101141. [DOI:10.1016/j.vprsr.2024.101141] [PMID]

[6] Julius RS, Schwan EV, Chimimba CT. Helminth composition and prevalence of indigenous and invasive synanthropic murid rodents in urban areas of Gauteng Province, South Africa. J Helminthol. 2018; 92(4):445-54. [DOI:10.1017/S0022149X17000761] [PMID]

[7] Rogozynski NP, Dixon B. The Th1/Th2 paradigm: A misrepresentation of helper T cell plasticity. Immunol Lett. 2024; 268:106870. [DOI:10.1016/j.imlet.2024.106870] [PMID]

[8] Pisetsky DS. Pathogenesis of autoimmune disease. Nat Rev Nephrol. 2023; 19(8):509-24. [DOI:10.1038/s41581-023-00720-1] [PMID]

[9] Xu C, Obers A, Qin M, Brandli A, Wong J, Huang X, et al. Selective regulation of IFN-γ and IL-4 co-producing unconventional T cells by purinergic signaling. J Exp Med. 2024; 221(12):e20240354. [DOI:10.1084/jem.20240354] [PMID]

[10] Tiersch KM, Daş G, Samson-Himmelstjerna GV, Gauly M. The role of culture media on embryonation and subsequent infectivity of Capillaria obsignata eggs. Parasitol Res. 2013; 112(1):357-64. [DOI:10.1007/s00436-012-3143-z] [PMID]

[11] Thomas LJ. Studies on the life history of Trichosomoides crassicauda (Bellingham). J Parasitol. 1924; 10(3):105-36. [DOI:10.2307/3270872]

[12] Bahrami S, Rezaei A, Alborzi A. Trichosomoides crassicauda infection in Wistar rats. Arch Razi Inst. 2014; 69(1):63-7. [Link]

[13] Rothenburger JL, Himsworth CG, La Perle KMD, Leighton FA, Nemeth NM, Treuting PM, et al. Pathology of wild Norway rats in Vancouver, Canada. J Vet Diagn Invest. 2019; 31(2):184-99. [DOI:10.1177/1040638719833436] [PMID]

[14] Najafi F, Taghavi Ghadikolai M, Naddaf SR, Hasanpour H, Mobedi I, Mowlavi G. Trichosomoides crassicauda infection in laboratory rats with histopathological description in the bladder tissue. J Med Microbiol Infect Dis. 2017; 5(1-2):31-4. [DOI:10.29252/JoMMID.5.1.2.31]

[15] Antonakopoulos GN, Turton J, Whitfield P, Newman J. Host-parasite interface of the urinary bladder-inhabiting nematode Trichosomoides crassicauda: Changes induced in the urothelium of infected rats. Int J Parasitol. 1991; 21(2):187-93. [DOI:10.1016/0020-7519(91)90009-V] [PMID]

[16] Serakides R, Ribeiro A, Silva C, Santos R, Nunes V, Nascimento E. Proliferative and inflammatory changes in the urinary bladder of female rats naturally infected with Trichosomoides crassicauda: report of 48 cases. Arq Bras Med Vet Zootec. 2001; 53(2):1-5. [DOI:10.1590/S0102-09352001000200012]

[17] Sikora V, Lyndin M, Hyriavenko N, Moskalenko R, Lyndina Y, Sikora K, et al. Morphological peculiarities of parasitic (Trichosomoides crassicauda) infection in rat urinary bladder. Maced Vet Rev. 2021; 44(2):159–67. [DOI:10.2478/macvetrev-2021-0019]

[18] Petritus PM, Burns JM Jr. Suppression of lethal Plasmodium yoelii malaria following protective immunization requires antibody-, IL-4-, and IFN-γ-dependent responses induced by vaccination and/or challenge infection. J Immunol. 2008; 180(1):444-53. [DOI:10.4049/jimmunol.180.1.444] [PMID]

[19] Belousova O, Lopatina A, Melnikov M. The role of dopamine in the modulation of monocyte-induced Th17- and Th1-immune response in multiple sclerosis. Int Immunopharmacol. 2024; 137:112540. [DOI:10.1016/j.intimp.2024.112540] [PMID]

[20] Gray V, Chen W, Tan RJY, Teo JMN, Huang Z, Fong CH, et al. Hyperglycemia-triggered lipid peroxidation destabilizes STAT4 and impairs anti-viral Th1 responses in type 2 diabetes. Cell Metab. 2024; 36(12):2511-27.e7. [DOI:10.1016/j.cmet.2024.10.004] [PMID]

[21] Chen Z, Ma Z, Gao J, Gao Y, Mei F. Relationship between serum MMP-2, Siglec-1, Th1/Th2 cell ratio, and disease activity in rheumatoid arthritis. Altern Ther Health Med. 2024; AT10385. [PMID]

[22] So EY, Park HH, Lee CE. IFN-γ and IFN-α post-transcriptionally down-regulate the IL-4-induced IL-4 receptor gene expression. J Immunol. 2000; 165(10):5472-9. [DOI:10.4049/jimmunol.165.10.5472] [PMID]

[23] Wen C, Wang J, Sun Z, Zhong R, Li M, Shen X, et al. Dietary zinc ameliorates TNBS-induced colitis in mice associated with regulation of Th1/Th2/Th17 balance and NF-κB/NLRP3 signaling pathway. Biol Trace Elem Res. 2024; 202(2):659-70. [DOI:10.1007/s12011-023-03715-y] [PMID]

[24] Yasen A, Li W, Aini A, Ran B, Jiang T, Shao Y, et al. Th1/Th2/Th17 cytokine profile in hepatic cystic Echinococcosis patients with different cyst stages. Parasite Immunol. 2021; 43(7):e12839. [DOI:10.1111/pim.12839] [PMID]

[25] Kotepui KU, Thirarattanasunthon P, Rattaprasert P, Kotepui M. A systematic review and meta-analysis of blood interleukin-4 levels concerning malaria infection and severity. Malar J. 2022; 21(1):217. [DOI:10.1186/s12936-022-04237-z] [PMID]

[26] Al-Qaoud KM, Pearlman E, Hartung T, Klukowski J, Fleischer B, Hoerauf A. A new mechanism for IL-5-dependent helminth control: Neutrophil accumulation and neutrophil-mediated worm encapsulation in murine filariasis are abolished in the absence of IL-5. Int Immunol. 2000; 12(6):899-908. [DOI:10.1093/intimm/12.6.899] [PMID]

[27] Takamoto M, Ovington KS, Behm CA, Sugane K, Young IG, Matthaei KI. Eosinophilia, parasite burden and lung damage in Toxocara canis infection in C57Bl/6 mice genetically deficient in IL-5. Immunology. 1997; 90(4):511-7. [DOI:10.1046/j.1365-2567.1997.00208.x] [PMID]

[28] Tabaran F, Cătoi C, Gal A, Bolfă P, Taulescu M, Nagy A, et al. Histopathological changes of the urinary bladder in the natural occurred infection with Trichosomoides crassicauda in albino rats. Bull UASVM Vet Med. 2011; 68(1):412–5. [DOI:10.15835/buasvmcn-vm:1:68:6844]