Archives of Razi Institute Journal
"Arch. Razi Inst."

Journal Homepage: https://archrazi.areeo.ac.ir/

Research Paper

Immunohistochemical Assessment of TTF-1, EGFR, Napsin-A, p53, and Proliferation Biomarkers in Canine Pulmonary Adenomas

Nasrin Hassanzadeh[1], **Amir Amniattalab**[2*]

1. Department of Veterinary Clinical Sciences, Ur.C., Islamic Azad University, Urmia, Iran.
2. Department of Veterinary Pathology, Ur.C., Islamic Azad University, Urmia, Iran.

Use your device to scan and read the article online

How to cite this article Hassanzadeh N, Amniattalab A. Immunohistochemical Assessment of TTF-1, EGFR, Napsin-A, p53, and Proliferation Biomarkers in Canine Pulmonary Adenomas. Archives of Razi Institute Journal. 2026; 81(4):889-900. https://doi.org/10.32598/ARI.81.4.3701

https://doi.org/10.32598/ARI.81.4.3701

Article info:
Received: 23 Mar 2026
Accepted: 13 May 2026
Published: 01 Jul 2026

Keywords:
Adenoma, Canine lung pathology, EGFR, Napsin-A, TTF-1

ABSTRACT

Introduction: Primary lung tumors (PLTs) are rare in dogs, and benign pulmonary adenomas of connective tissue origin and primary pulmonary neoplasms are infrequently reported in the genera Canis and Felis. This study aimed to examine the pathological and immunohistochemical features of canine pulmonary adenomas diagnosed over a 10-year period.

Materials & Methods: Dogs with lung adenoma (n=6) underwent necropsy and were investigated for hematological changes, histopathology (hematoxylin and eosin [H&E], Masson's trichrome, and Perl's Prussian blue staining), and immunohistochemistry.

Results: Out of 882 dogs of various breeds with clinical respiratory signs, pulmonary adenomas were detected in six (0.68%), mostly in large, 8- to 12-year-old dogs. Hematological assessments revealed remarkable neutrophilia in the tumor-bearing group ($P<0.05$), and all tumors were identified as papillary adenomas. Interestingly, two tumor-affected dogs had concurrent chronic heart failure manifested by pulmonary hemosiderophages, which is being reported for the first time. The tumors' immunophenotype was TTF-1-, EGFR-, Napsin-A-, CEA-, EMA-, CK+, Vimentin-, p53-, and Ki-67 negative, indicating the lack of malignant potential. Whilst EGFR expression was not detected in tumorous lungs, positive expression of EGFR, TTF-1, and Napsin-A was observed in approximately 30%, 30%-40%, and 40% of normal pulmonary cells, respectively. The expression profiles for these markers in dogs' normal pulmonary cells, with variations in TTF-1 and Napsin-A expression, may provide a baseline for comparison with EGFR expression patterns in malignant lung tumors such as adenocarcinomas.

Conclusion: The results suggest that canine pulmonary adenomas are completely benign and have no malignant potential, and immunohistochemical assessments can aid in disease prognosis and inform the development of tailored therapy protocols.

*** Corresponding Author:**
Amir Amniattalab, Associate Professor.
Address: *Department of Veterinary Pathology, Ur.C., Islamic Azad University, Urmia, Iran.*
E-mail: *Amir.Amniattalab@iau.ac.ir*

Copyright © 2026 The Author(s);
This work is licensed under a Creative Commons Attribution-NonCommercial 4.0 International license (https://creativecommons.org/licenses/by-nc/4.0/).
Noncommercial uses of the work are permitted, provided the original work is properly cited.

1. Introduction

Primary lung tumors (PLTs) are rare but are a key contributor to lung disease in dogs, accounting for roughly 1% of all tumors in the genus *Canis*. PLTs are characteristically malignant and are rarely represented by benign lesions such as adenoma, papilloma, hemangioma, and granuloma. In the veterinary literature, other tumor types include localized histiocytic sarcoma, fibrosarcoma, chondrosarcoma, osteosarcoma, hemangiopericytoma, mast cell tumor, and neuroendocrine tumors [1]. With a reported prevalence of 4.17 per 100,000, PLTs rarely occur in dogs. However, the incidence rate increased over a two-decade period, ending in 1989, presumably due to the growing age of dogs [2]. Despite digital radiography revealing more countable bronchi than analog radiography, this increased visibility should not automatically lead to a diagnosis of airway disease in veterinary patients [3]. Therefore, pathology is a more appropriate diagnostic method for pulmonary disorders. Since the solid pattern of PLTs is rare in domestic animals, it remains paramount to assess morphological features and conduct immunohistochemical assays for the precise diagnosis of primary pulmonary neoplasms [4]. Some of the IHC markers cannot be considered independent prognostic factors, and therefore these markers are more reliable when used together as part of an antibody panel [5, 6]. A pulmonary papillary adenoma is a benign epithelial tumor that frequently occurs in the periphery of the lung. Since the first case in humans was reported by Spencer et al. in 1980, 41 cases of this tumor have been reported worldwide [7]. In precision medicine, immunohistochemistry possesses marked versatility in classifying tumors into subtypes and assessing biomarkers for systemic therapy and clinical decision-making [8]. Though TTF-1 is a specific and sensitive marker for canine PTLs, it is also expressed in thyroid carcinomas, which frequently metastasize to the lung. Napsin A and surfactant protein A (SP-A) are key markers in the histological diagnosis of human non-small-cell lung cancer. Nonetheless, they have not been extensively studied in canine neoplasms [9]. Of all the markers specific to pulmonary epithelium, TTF-1 has been the focus subject of numerous studies. In normal lung tissues, TTF-1 is predominant in the nuclei of alveolar cells, particularly in type II pneumocytes, non-ciliated bronchiolar cells (Clara cells), and basal cells. Of all the non-small cell lung tumors, TTF-1 expression has been reported in up to 94% of adenocarcinomas [10]. Similarly, Napsin A is a useful marker for identifying type II pneumocytes [11]. Taking note of the foregoing, this research characterizes and evaluates the pathological pattern of canine PLTs and compares variations in the expression profiles of the immunohistochemical markers TTF-1, CK, EMA, CEA, Ki-67, vimentin, p53, Napsin-A, and EGFR.

2. Materials and Methods

2.1. Animals

The current study was conducted with the approval of the Research Ethics Committee of Islamic Azad University, Urmia Branch on September 8, 2024.

A total of 1,831 dogs of various breeds were studied at the Veterinary Clinic of Islamic Azad University, Urmia Branch, and four private veterinary clinics in Urmia County between December 22, 2014, and December 21, 2024, over a 10-year period. Among them, 882 dogs demonstrated clinical respiratory signs, and pulmonary masses were identified in six dogs that subsequently underwent necropsy. The study included dogs submitted to necropsy due to various reasons such as failure to respond to routine anti-inflammatory and antibiotic therapy for pulmonary diseases, deteriorating clinical condition, metastatic tumors, road traffic accidents, and the owner's request. Pulmonary tissue masses were carefully examined for color, tissue consistency, size, location, and the status of the regional lymph nodes, i.e. bronchial and mediastinal lymph nodes, and the findings were recorded. Naturally, encountering tumors, particularly in older dogs, was expected due to the improved health care and increased longevity of companion animals. As some of the referred dogs showing respiratory signs were from petrochemical or chemical manufacturing plants, the presence of neoplastic masses in the respiratory system was considered possible.

2.2. Hematology

Blood samples containing ethylenediaminetetraacetic acid (EDTA) were drawn from the jugular veins of six healthy dogs and six dogs with pulmonary adenoma using a 21-gauge needle and analyzed using the Abbott Cell-Dyn 3500 automatic hematology analyzer.

2.3. Pathology

Tissue samples from the pulmonary masses were fixed in 10% formalin for at least 48 hours, then processed using standard methods. Dehydration, clearing, and impregnation were performed using a tissue processor before preparing paraffin blocks. Sections 6 µm thick were prepared and stained with hematoxylin and eosin (H&E)

[12]. Masson's trichrome and Perl's Prussian blue stains were used to identify connective tissue and iron deposits, respectively.

2.4. Immunohistochemistry

After confirming pulmonary adenoma through light microscopy and determining its pathological type and pattern, six normal and six pulmonary adenoma lung tissue sections were immunohistochemically stained using the EnVision + Dual Link System-HRP method.

Deparaffinized sections were rehydrated with ethanol and treated with 3% hydrogen peroxide for 30 minutes to block endogenous peroxidase activities. Antigen retrieval was performed using 0.01 M citrate buffer at pH 6.0 for 25 minutes. Non-specific staining was blocked by incubating slides in 5% bovine serum albumin in TBS for 30 minutes. Slides were then washed, incubated overnight at 4 ˚C with various primary antibodies including TTF-1 (Dako, USA; 1:200), Ki-67 (Dako, Denmark; 1:100), cytokeratin (Dako, Glostrup, Denmark, clone AE1/AE3; 1:50), vimentin (Dako; clone 3B4; 1:100), EGFR (Clone 31G7, Zymed Laboratories, San Francisco, California, USA; 1:50), EMA (Dako, USA; 1:100), CEA (Dako, USA; 1:300), p53 (Dako, Glostrup, Denmark; 1:100), and Napsin-A (Biocare, Concord, CA, USA; 1:100), washed again with phosphate-buffered saline (PBS), treated with streptavidin-horseradish peroxidase, and counterstained with Harris hematoxylin [13]. The positive cells (with brown immunoreactivity) were counted in five random fields (each spanning 2.37 mm²) using a ×40 objective lens to grade the expression level and intensity of immunohistochemical markers for each normal and pathological sample. The percentage of positively stained cells of any intensity relative to total number of cells was calculated. The Equation 1 was employed to calculate the H-Score (Histochemical scoring assessment), which is a superior indicator of marker expression intensity and the distribution of different expression intensities across each sample.

1. $H\text{-score}=(0\times p_0)+(1\times p_1)+(2\times p_2)+(3\times p_3)$

In this context, P represents the percentage of positive cells (+, ++, and +++) in the tissue, displayed as P1, P2, and P3, respectively. The numerical H-Score ranges from 0 to 300 [14, 15].

2.5. Statistical analysis

Statistical analysis of the obtained data was carried out using GraphPad Prism version 9. Normality was assessed using the Shapiro-Wilk test for the quantitative data. Then, an independent t-test was used to examine differences in the mean hematological parameters between the study groups due to the normal distribution of the hematological data. Additionally, the mean histochemical scores (% and H-score) of healthy and adenoma-affected dogs were compared using an independent t-test. A $P\leq0.05$ was considered statistically significant.

3. Results

3.1. Clinical diagnosis and necropsy

Out of 882 dogs that had respiratory signs, six dogs had pulmonary adenomas, with tissue samples obtained at necropsy and the diagnosis confirmed by light microscopic examination. It must be noted that one dog with a pulmonary adenoma died in a road traffic accident. The tumor was discovered incidentally during a necropsy examination.

e from various breeds, including German Shepherd, Shih Tzu, Dachshund, Rottweiler, Terrier, Iraqi, Sarabi, and mixed native Iranian breeds. Out of the six dogs that had adenoma tumors, two were of mixed Iranian breeds (both male, 8-10 years old), one was a Shih Tzu (female, 12 years old), two were German Shepherds (both male, 8-12 years old), and one was a Rottweiler (female, 10 years old). The tumors appeared as single, separate masses with distinct boundaries, were white to gray, and had a relatively soft to firm consistency. Tumor shapes were mostly circular or oval, with diameters ranging from 4 to 10 cm (Figure 1). The dogs with tumors had shown clinical signs for three to eight weeks, including cough, anxiety, halitosis, increased heart rate, and lethargy, and had a history of non-response to treatment with conventional antibiotics such as gentamicin and cephalexin. During the necropsy, the tumor mass was found in the caudal lobe of the right lung in four animals and in the right middle lung lobe in two animals. In addition to the tumor, numerous gray- to brown-colored spots were diffusely observed in various lung lobes during the necropsy of two dogs (one mixed Iranian breed and one German Shepherd).

3.2. Hematology

The quantitative data for the hematological parameters in the studied dogs, categorized as normal and those with pulmonary adenoma, are presented in Table 1 as Mean±SD. Accordingly, the neutrophil count was significantly increased in the tumor group compared to the normal group ($P\leq0.05$). No significant increase or de-

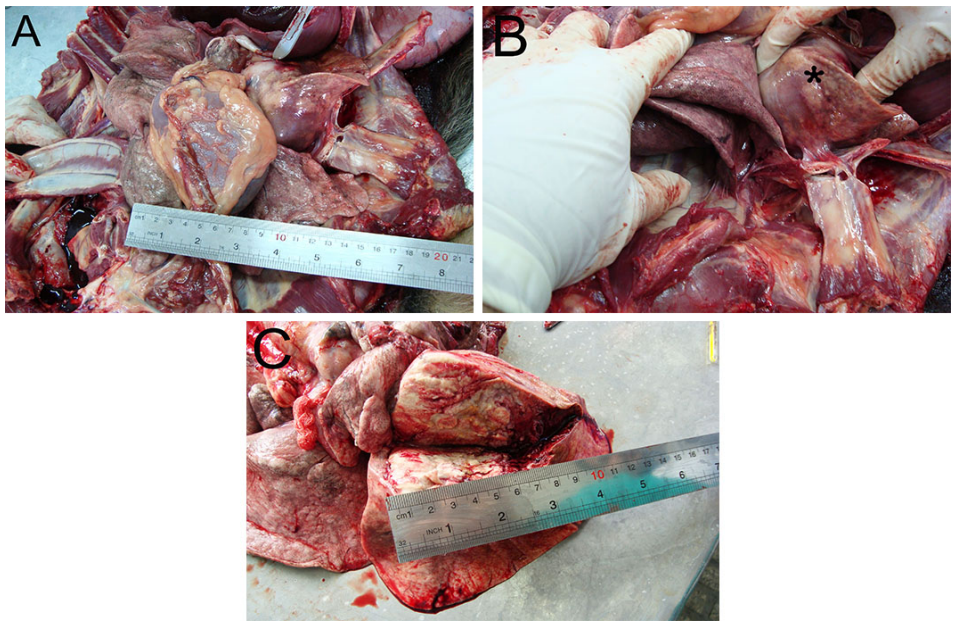

Figure 1. Gross appearance of a pulmonary adenoma in a 10-year-old male German Shepherd during necropsy

A) Location of with the adenoma in relation to the lung and heart (scalpel), B) Adenoma (asterisk) in the lung with gray-brown spots within the lung parenchyma, C) Cross-section of the adenoma with an approximate diameter of 8 cm, white color, firm consistency, and a heterogeneous tissue composition

crease was observed in the other hematological parameters between the two groups (P>0.05).

3.3. Pathology

Microscopically, pulmonary masses found in six necropsied dogs were diagnosed as adenomas. Glandular structures with papillary patterns and thick fibrovascular cores containing scant connective tissue were observed in pulmonary adenomas. Uniform glands were well differentiated, without pleomorphism, anisocytosis, or mitotic figures, and there was no evidence of hemorrhage or necrosis in the lung parenchyma, all of which indicated the benign nature of the tumor (Figures 2A and 2D). However, a limited number (1-4) of cysts with varying sizes were present (consistent with cystadenoma) in the parenchyma of two adenomas. Meanwhile, there was abundant smooth muscle tissue in the thick stromal scaffolding with minimal connective tissue (Masson's trichrome) (Figures 2B and 2D). Alveolar macrophages were observed in H&E-stained sections, corresponding to the gray-brown spots (pigments) in the lung parenchyma associated with the tumor. The pigments turned blue after Perl's Prussian blue staining, confirming the presence of iron(hemosiderin) (Figures 2E and 2F). It was determined that the presence of hemosiderin-laden alveolar macrophages (hemosiderophages) in the lung parenchyma of two animals with adenomas was indicative of left-sided heart failure.

3.4. Immunohistochemistry

The study compared immunohistochemical marker scores between dogs with pulmonary adenoma and normal dogs using an independent t-test (Figures 3A and 3B). Results showed significantly higher expression levels of TTF1, EGFR, and Napsin-A in healthy lungs compared to adenoma tissues (P<0.001). The expression percentage and H-score for EMA and CEA markers were low in both groups, but were statistically different (P<0.001). Cytokeratin (CK) showed higher expression in the pulmonary tumor group, indicating its epithelial origin. Vimentin expression in normal lung cells was minimal. However, the expression percentage and H-score in stromal cells located in interstitial spaces of glandular units (smooth muscle and connective tissue cells) demonstrated a significant increase (P<0.001), indicating the mesenchymal origin of the stromal cells within the tumor. Cellular expression percentage and H-Score were negligible in both groups for the p53 marker. The average cellular expression in normal lung and tumor tissue was less than 1% and 5%, respectively. Ultimately, cellular expression of the K-i67 marker was minimal and below 1% in both groups. Moreover, the H-Score in the tumor group was much lower compared to the normal group. The findings for this marker and the pathological pattern indicate that the cellular proliferation rate in the tumor group was minimal. Thus, all pulmonary adenomas identified in the examined dogs were

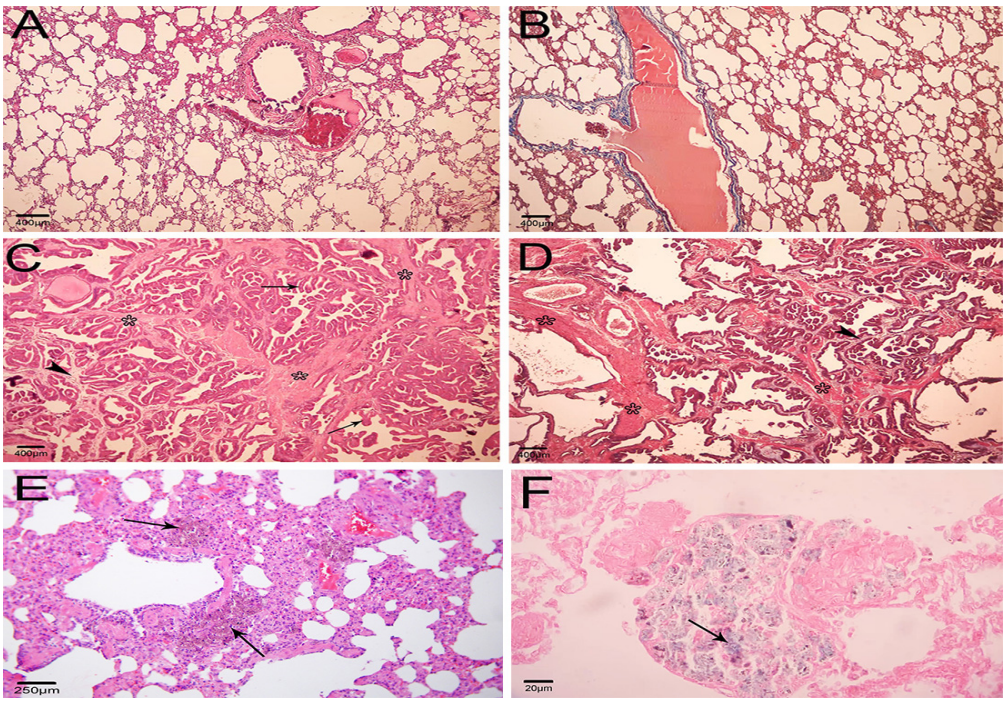

Figure 2. Light microscopic photomicrograph of normal canine lung tissue and pulmonary adenoma

A) Normal lung with regular structures (H&E); B) Normal lung without fibrosis in the parenchyma and minimal connective tissue around blood vessels (blue; Masson's trichrome); C) Lung adenoma with a papillary glandular pattern (arrow), thick smooth muscle stroma (asterisk), and minimal connective tissue (arrowhead) surrounding glandular units without necrosis or hemorrhage in the parenchyma: Glandular cells are well differentiated without anisocytosis, pleomorphism, or mitotic figures (H&E); D) Adenoma with abundant smooth muscle tissue (asterisk) stained pink-red and minimal connective tissue (arrowhead) stained blue among glandular units (Masson's trichrome); E) Presence of intra-alveolar macrophages (hemosiderophages) (arrow) in the lung parenchyma with brown pigment within the cytoplasm (H&E); F) Iron deposits inside hemosiderophages, stained blue, confirming left-sided heart failure in a dog with lung adenoma (Perl's Prussian blue)

benign and lacked malignant potential. Finally, immunohistochemical expression patterns for TTF-1, EGFR, Napsin-A, EMA, CEA, CK, vimentin, p53, and Ki-67 in the normal lung group and the pulmonary adenoma group were compared in Figures 4 and 5.

4. Discussion

This research, conducted over a 10-year period in Urmia, studied 882 dogs aged 8-12 years showing respiratory issues. It found that six dogs (0.68%) had pulmonary adenomas, mostly in larger breeds, but the rarity of these tumors makes it hard to draw firm conclusions about their associations with age, sex, and breed. Previous studies have noted possible associations, including a higher occurrence in male dogs [16] and specific breeds like Boxers, Australian Shepherd, Irish Setters, Doberman Pinscher, and Mountain Dog breeds [2, 17]. This issue may be related to the popularity of various dog breeds in different geographical locations [17]. In the current research, we found a few localized cysts whose walls were lined with cuboidal neoplastic cells. Given the benign nature of the tumors, necrotic and desquamated epithelial cells were not present in these tumors, unlike those observed in cystadenocarcinomas [18]. Most research has focused on malignant tumors, but this study investigated the characteristics and malignant potential of benign pulmonary adenomas. A significant finding was the occurrence of pulmonary adenoma alongside chronic heart failure in two dogs, as indicated by the presence of hemosiderophages in the lungs. There was no clear cause for the coexistence of these conditions, and no similar cases have been reported. Necropsy showed no other tumors or vascular damage, although some dogs exhibited left ventricular hypertrophy.

This study found that neutrophilia in cases of pulmonary adenoma might be due to inflammation in the respiratory system, as the animals had shown respiratory signs like coughing for about a month before necropsy. The present study evaluated the TTF-1 expression in normal and adenoma-affected lungs. In normal lungs, 20-40% nuclear expression with a high H-score of TTF-1 was observed, while no positive reaction was found

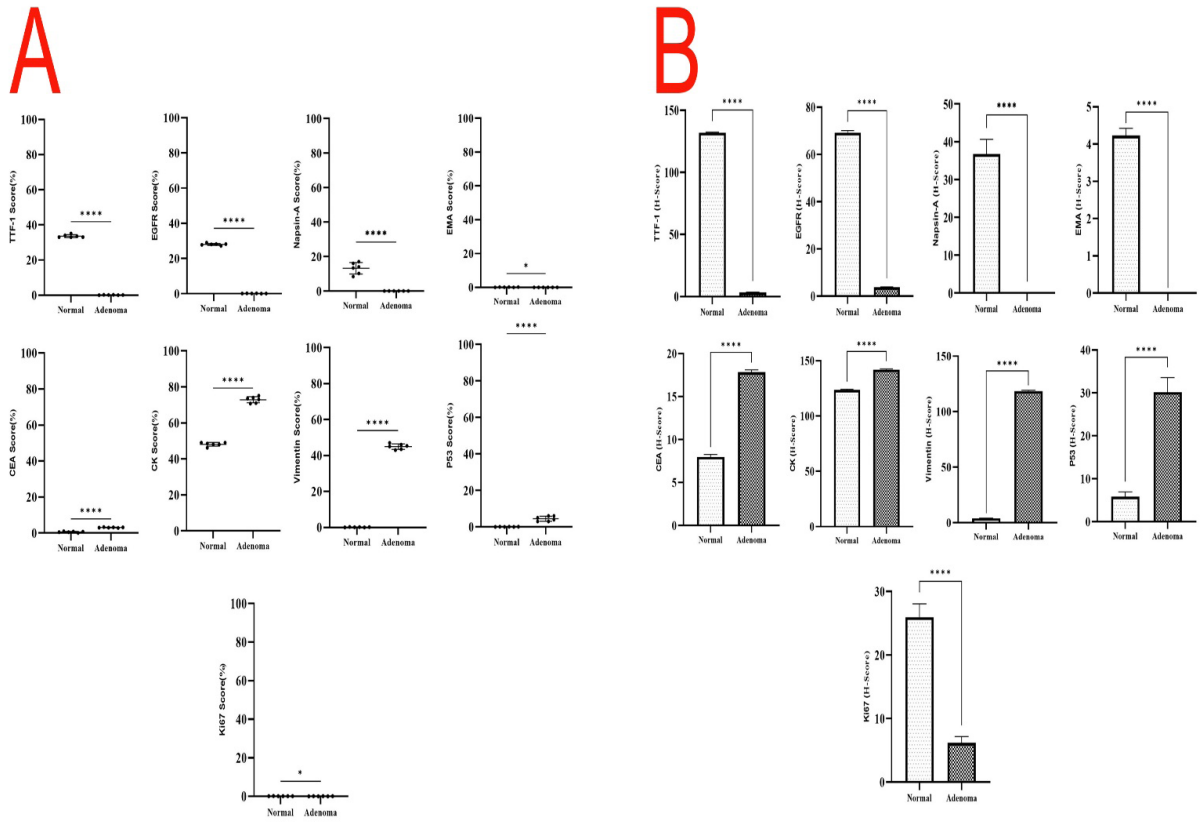

Figure 3. A) The results of the independent t-test for the percentage of cellular expression of various immunohistochemical markers in normal and pulmonary adenoma lungs; B) The results of the independent t-test for the H-score of the different immunohistochemical markers in normal and pulmonary adenoma lungs

Ns: Not significant.

*Statistically significant (P<0.05).

Note: Data are presented as Mean±SD.

in the adenoma cells. TTF-1 is a key marker for canine lung tumors and also expressed in thyroid cancers that metastasize to the lungs. Other markers like Napsin A and SP-A, important for human lung cancer, are gaining attention in the evaluation of canine neoplasms [9]. TTF-1 negativity is associated with an unfavorable cancer phenotype, including the absence of specific genomic alterations, higher tumor burden, and poorer performance status [19]. The marker should be used alongside other diagnostic indicators to differentiate tumor types, with tumor characteristics also playing a vital role in treatment decisions.

The findings of the current study regarding the Napsin-A marker indicate both positive expression and intensity (H-Score) in the normal group, with no marker expression in the adenoma group. These findings are similar to the work of Ramos-Vara et al. (2016), who reported immunopositivity for this marker in normal canine lung tissue [20]. Our results showed that alveolar cells in normal canine lungs exhibited approximately 30% positive cytoplasmic expression of EGFR, with an H-score of 60-80, whereas tumor cells had almost no expression. Unlike humans, EGFR mutations are rare in canine lung adenocarcinoma. Increased EGFR expression was also seen in lungs affected by anthracosis, suggesting a link to air pollution and cancer risk [17]. The present study found no EGFR expression in adenoma lungs, while about 30% of normal lung cells showed EGFR positivity. TTF-1 and Napsin-A expression patterns were similar in normal lung tissue, and changes in these markers may affect EGFR expression in malignant lung tumors like adenocarcinoma [21]. It should be noted that in the current study, the expression of these three markers in tumor parenchymal cells was negative due to the benign nature of the lung adenoma. Moreover, their expression might undergo significant changes with tumor malignancy. The IHC results for EMA and CEA markers showed weak

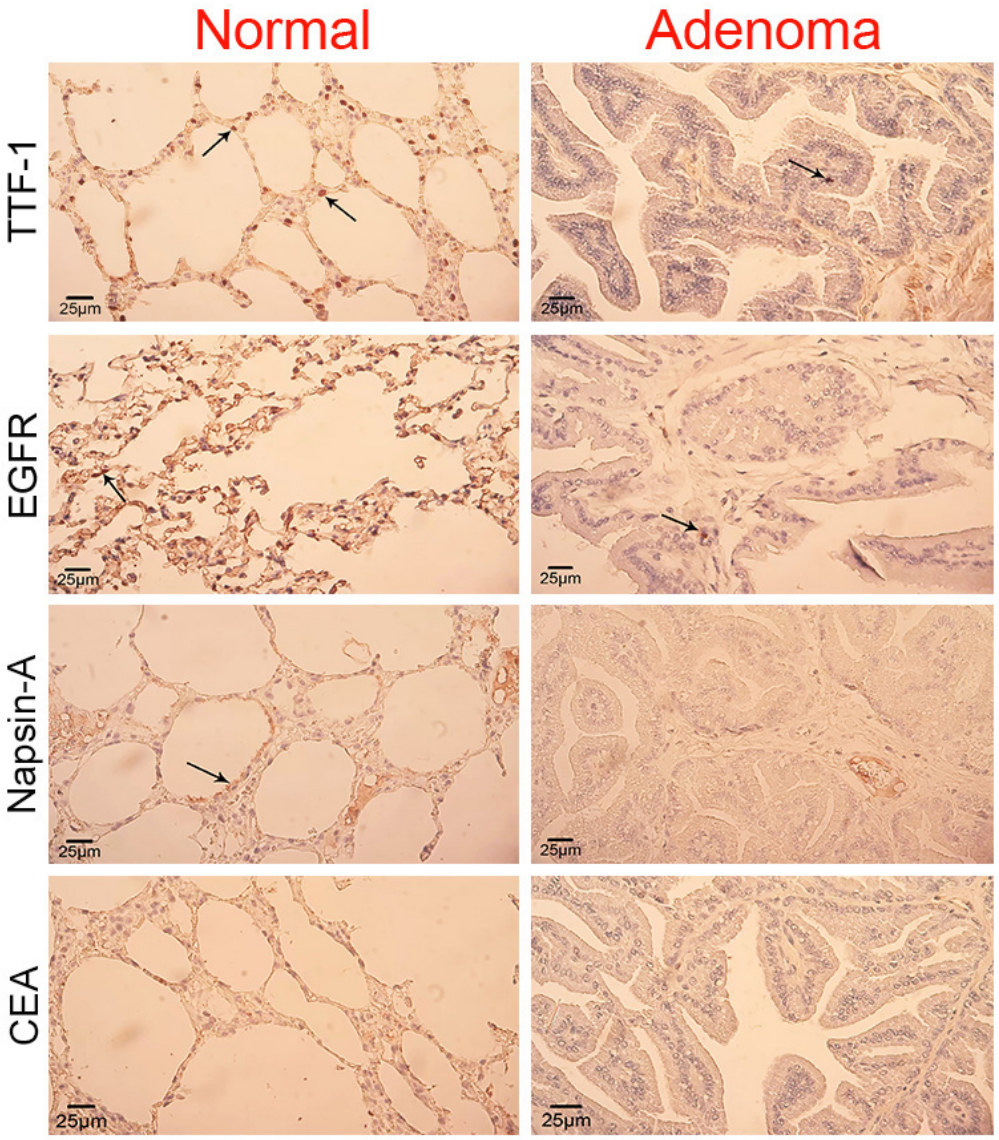

Figure 4. Immunohistochemical photomicrograph of normal lung and pulmonary adenoma tissues

Note: Relatively strong nuclear TTF-1 expression in type II pneumocytes (arrow) in the normal lung and weak expression in the tumor cells (arrow). Cytoplasmic expression of Napsin-A and EGFR in the normal lung (arrow) and absent or weak expression (arrow) in tumor tissue. The absence of CEA expression in both tumor and normal lung tissues is also observed (IHC).

expression in tumors and normal lungs. Negative results were expected for benign adenoma tumors, supporting the exclusion of a neuroendocrine tumor origin [22]. Regarding the IHC results for CK in the current study, the origin of tumor cells was confirmed to be epithelial. Previous studies on humans and canines have revealed that CK expression increases in lung epithelial tumors, particularly malignant tumors like adenocarcinomas [4, 7]. IHC results showed no vimentin expression in normal lung cells. In the adenoma group, 40-60% of mesenchymal cells between the glands had positive expression, but glandular cells were negative for the vimentin due to their epithelial origin. Although a study showed that the combined expression of cytokeratin and vimentin in canine lung tumors is similar to that observed in humans [16]. Vimentin is a type III intermediate filament strongly expressed in lung cancer, associated with metastatic tissue and shorter survival in patients with non-small cell lung cancer. Vimentin's role in the metastatic process has been extensively studied under experimental conditions [23]. Concerning the immunohistochemical expression of the p53 in the current study, results showed no expression in the normal lungs and weak expression of less than 10% in the tumor cells. Previous studies have indicated that canine p53 family proteins have biological activities similar to their human counterparts. These

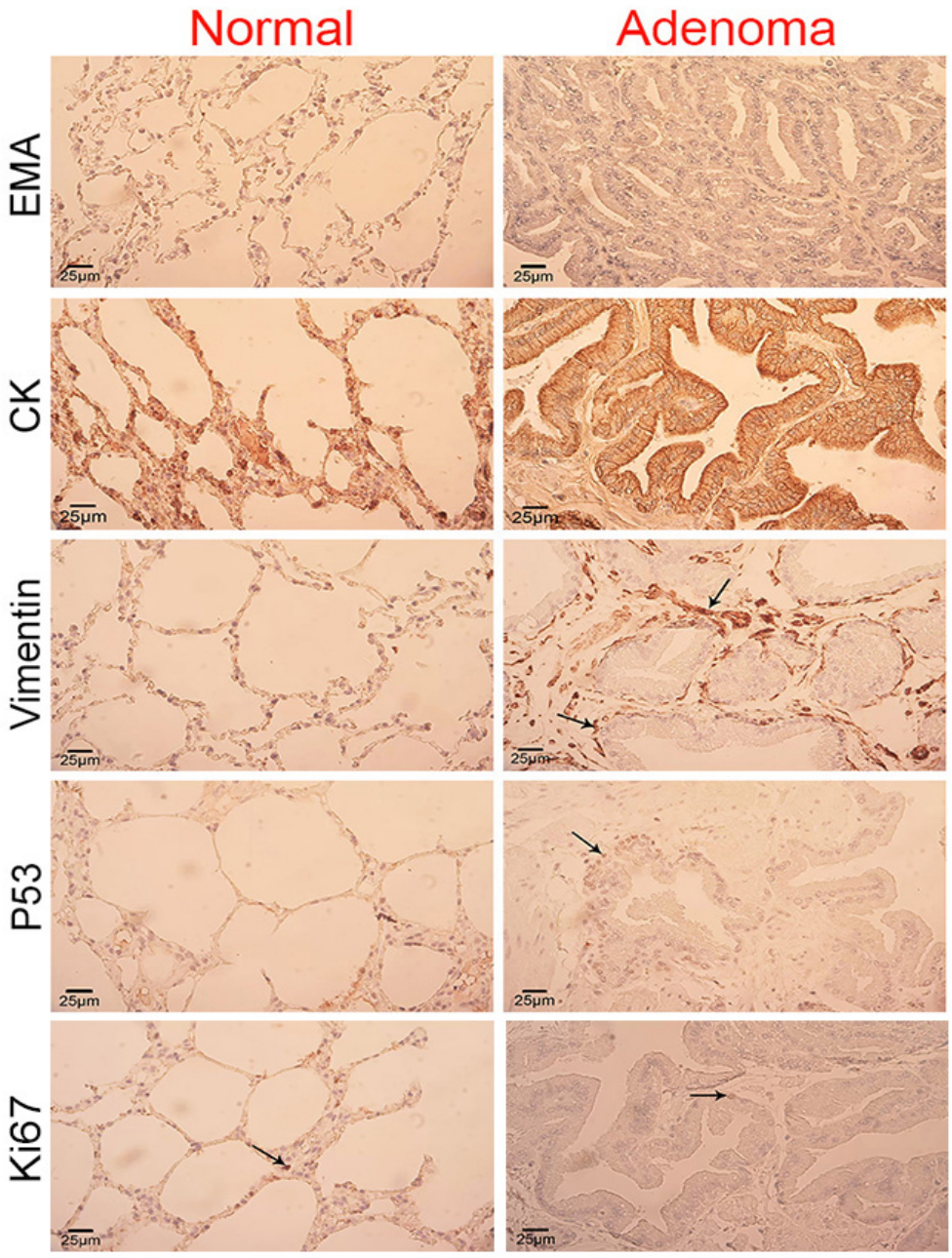

Figure 5. Continuation of immunohistochemical staining of normal and tumor lung tissues

Note: Absence of EMA expression in tumor and normal lungs, weak nuclear P53 expression in tumor cells (arrow), and strong, diffuse cytoplasmic CK expression in normal lungs, which was even higher in the tumor cells. Absence of vimentin expression in normal lung cells and strong expression in the stromal tissue (muscle and connective tissue cells) surrounding glandular units of the tumor tissue (arrow). Weak nuclear Ki-67 expression (arrow) in normal and tumor lung cells, which indicates a a low proliferative activity consistent with the benign nature of the tumor (IHC).

similarities make dogs a valuable tumor model for human studies [24]. Ultimately, IHC results for the Ki-67 marker in the current study indicated no expression in tumor and normal tissues. This marker is employed to evaluate cellular proliferation and is often used as a biomarker for the prognosis of malignant tumors. The negative status of adenoma tumor cells in the current study indicates their benign nature and lack of malignant potential. Evaluating the cell proliferation index might be valuable in assessing prognosis following surgical treatments of canine lung cancers [25]. High Ki-67 expression in malignant lung tumors typically indicates a poor prognosis. The percentage of Ki-67-positive cells in human lung adenomas has been reported to be 2-6%

Table 1. Comparison of the hematological variables between normal dogs and dogs with pulmonary adenoma

Variables	Dog Selection (n=12)		P
	Mean±SD		
	Normal (n=6)	With Lung Adenoma (n=6)	
HCT (%) (Reference: 37-55)	44.33±4.45	42.17±5.19	0.456
Hb (g/L) (Reference: 140-190)	163.3±9.52	161.8±9.06	0.785
RBC (10^{12}/L) (Reference: 5.8-8.50)	6.8±0.83	6.62±0.68	0.687
MCV (fl) (Reference: 66-75)	69.5±1.87	69.83±2.04	0.774
MCHC (g/L) (Reference: 32-36)	33.17±1.42	33±1.26	0.837
PLT (10^9/L) (Reference: 150-400)	250.2±52.53	328.5±61.95	0.731
WBC (10^9/L) (Reference: 6-13)	9.2±1.31	11.05±1.98	0.086
Neut (10^9/L) (Reference: 3-10.50)	6.6±1.13	10.72±1.29	0.001
Lym (10^9/L) (Reference:1-4)	2.47±0.66	2.6±0.52	0.706
Mon (10^9/L) (Reference: 0.15-1.2)	0.55±0.26	0.65±0.33	0.582
Eos (10^9/L) (Reference:0-0.1.3)	0.45±0.21	0.47±0.23	0.901

Abbreviations: Hct: Hematocrit; Hb: Hemoglobin; RBC: Red blood cells; MCV: Mean corpuscular volume; MCHC: Mean corpuscular hemoglobin concentration; PLT: Platelets; WBC: White blood cells; Neut.: Neutrophil; Lym: Lymphocyte; Mon.: Monocyte; Eos.: Eosinophil.

Note: $P<0.05$ was considered statistically significant.

[7, 11]. In malignant canine lung tumors like adenocarcinoma, the percentages of Ki-67-positive cells have been reported to range from 20-50% [26].

5. Conclusion

The study conducted in Urmia County over a 10-year period involved 882 dogs showing respiratory signs. Only six dogs (0.68%) were diagnosed with pulmonary papillary adenoma. In two cases, the dogs also had chronic heart failure. The tumors showed the following immunophenotypes: TTF-1-, EGFR-, Napsin-A-, CEA-, EMA-, CK+, vimentin-, p53-, and Ki-67-, indicating a low malignant potential. The findings suggest that canine pulmonary adenomas are benign. The results from the immunohistochemical analysis could help guide treatment plans and prognostic assessment.

Acknowledgements

The authors would like to thank the members of the Laboratory, Department of Pathology, TUMS Cancer Institute, for their technical support in immunohistochemistry.

Compliance with ethical guidelines

This study was approved by the Research Ethics Committee of the Urmia Branch, Islamic Azad University, Urmia, Iran (Code: IR.IAU.URMIA.REC.1403.152).

Funding

This research did not receive any grant from funding agencies in the public, commercial, or non-profit sectors.

Authors' contributions

Conceptualization, study design, data acquisition, administrative, writing the original draft, technical, and material support: All authors; Supervision, analysis, data interpretation,statistical analysis, review and editing: Amir Amniattalab.

Conflict of interest

The authors declared no conflict of interest.

Data availability

The data that support the findings of this study are available upon request from the corresponding author.

References

[1] McPhetridge J, Scharf V, Regier P, Toth D, Lorange M, Tremolada G, et al. Distribution of histopathologic types of primary pulmonary neoplasia in dogs and outcome of affected dogs:340 cases (2010-2019). J Am Vet Med Assoc. 2021; 260(2):234-43. [DOI:10.2460/javma.20.12.0698] [PMID]

[2] Ogilvie GK, Haschek WM, Withrow SJ, Richardson RC, Harvey HJ, Henderson RA, et al. Classification of primary lung tumors in dogs: 210 cases (1975-1985). J Am Vet Med Assoc. 1989; 195(1):106-8. [PMID]

[3] Tavakoli A, Vajhi A, Molazem M, Soroori S, Rostami A, Hassankhani M, et al. Comparison of computerized digital and analog radiography for detection of bronchial pattern in dogs. Iran J Vet Med. 2018; 12(2):145-51. [Link]

[4] Oliveira MC, Costa SZR, de Castro Pires AP, Gonçalves T, Fernandes JI, de Camargo RBP, et al. Primary solid pulmonary adenocarcinoma in a dog. Acta Sci Vet Sci. 2019; 47(Suppl 1):440. [DOI:10.22456/1679-9216.97395]

[5] Elahirad E, Sasani F, Gharagozlou MJ, Khosravi A, Khanbarari F. Evaluation of cytokeratin 7 expression in different mammary gland neoplasms. Iran J Vet Med. 2021; 15(1):56-67. [DOI:10.22059/ijvm.2020.295956.1005052]

[6] Molazem M, Amini E, Salimi A, Muhammadnejad A, Hasannejad H. Magnetic Resonance Imaging features of olfactory neuroendocrine carcinoma in a dog. Iran J Vet Med. 2024; 18(3):447-52. [Link]

[7] Liu P, Feng J, Yang M, Chen J, Fu L, Lu J. Pulmonary papillary adenoma with malignant potential: A case report and literature review. Diagn Pathol. 2022; 17(1):81. [DOI:10.1186/s13000-022-01259-8] [PMID]

[8] Inamura K. Update on immunohistochemistry for the diagnosis of lung cancer. Cancers (Basel). 2018; 10(3):72. [DOI:10.3390/cancers10030072] [PMID]

[9] Beck J, Miller M, Frank C, DuSold D, Ramos-Vara J. Surfactant protein A and Napsin A in the immunohistochemical characterization of canine pulmonary Ccarcinomas: Comparison with Thyroid transcription Factor-1. Vet Pathol. 2017; 54(5):767-74. [DOI:10.1177/0300985817712559] [PMID]

[10] Tan D, Zander DS. Immunohistochemistry for assessment of pulmonary and pleural neoplasms: A review and update. Int J Clin Exp Pathol. 2008; 1(1):19-31. [PMID]

[11] Lin XY, Han Q, Wang EH, Zhang Y. Pulmonary papillary adenoma presenting in central portion: A case report. Diagn Pathol. 2015; 10:190. [DOI:10.1186/s13000-015-0425-7] [PMID]

[12] Amoorahim S, Amniattalab A. Immunohistochemical expression of GDNF, P53 and Ki67 with Tunel assay in canine non-neoplastic esophageal nodules induced by Spirocerca lupi. Mac Vet Rev. 2025; 48(1):39-51. [DOI:10.2478/macvetrev-2025-0014]

[13] Marzban H, Sasani F. Canine mammary gland cancer stem cell and its potential role in malignant biologic behavior. Iran J Vet Med. 2020; 14(3):329-42. [DOI:10.22059/ijvm.2019.288591.1005019]

[14] Piercealla WE, Wolfea M, Suschaka J, Changa H, Chena Y, Sprotta KM, et al. Strategies for H-score normalization of preanalytical technical variables with potential utility to immunohistochemical-based biomarker quantitation in therapeutic response diagnostics. Anal Cell Pathol. 2011; 34:159-68. [DOI:10.1155/2011/583182]

[15] Ruengwanichayakun P. Histochemical scoring assessment (H-score). Asian Arch Pathol. 2021; 3(1):13-14. [Link]

[16] Burgess HJ, Kerr ME. Cytokeratin and vimentin co-expression in 21 canine primary pulmonary epithelial neoplasms. J Vet Diagn Invest. 2009; 21(6):815-20. [DOI:10.1177/104063870902100607] [PMID]

[17] Marcinowska A, Horta RDS, Queiroga F, Giuliano A. Canine lung carcinoma-A descriptive review. Front Vet Sci. 2025; 11:1464659. [DOI:10.3389/fvets.2024.1464659] [PMID]

[18] Baghkheirati AA, Shokrpoor S, Hassanzadeh M, Nezhad JJ, Razmyar J. Papillary cystadenocarcinoma in a Budgerigar (Melopsittacus undulatus). Iran J Vet Med. 2023; 17(4):409-14. [DOI:10.32598/IJVM.17.4.1005214]

[19] Schallenberg S, Dernbach G, Dragomir MP, Schlachtenberger G, Boschung K, Friedrich C, et al. TTF-1 status in early-stage lung adenocarcinoma is an independent predictor of relapse and survival superior to tumor grading. Eur J Cancer. 2024; 197:113474. [DOI:10.1016/j.ejca.2023.113474] [PMID]

[20] Ramos-Vara JA, Frank CB, DuSold D, Miller MA. Immunohistochemical detection of Pax8 and Napsin A in canine thyroid tumours: Comparison with thyroglobulin, calcitonin and thyroid transcription factor 1. J Comp Pathol. 2016; 155(4):286-98. [DOI:10.1016/j.jcpa.2016.07.009] [PMID]

[21] Ren X, Wen X, Ren YJ, Liu X, Wang J, Hao M, et al. Significance of thyroid transcription factor 1 and Napsin A for prompting the status of EGFR mutations in lung adenocarcinoma patients. J Thorac Dis. 2022; 14(11):4395-404. [DOI:10.21037/jtd-22-1265] [PMID]

[22] Georgakopoulou VE, Zygouris E, Damaskos C, Pierrakou A, Papalexis P, Garmpis N, et al. Prognostic value of the immunohistochemistry markers CD56, TTF-1, synaptophysin, CEA, EMA and NSE in surgically resected lung carcinoid tumors. Mol Clin Oncol. 2022; 16(2):31. [DOI:10.3892/mco.2021.2464] [PMID]

[23] Berr AL, Wiese K, Dos Santos G, Koch CM, Anekalla KR, Kidd M, et al. Vimentin is required for tumor progression and metastasis in a mouse model of non-small cell lung cancer. Oncogene. 2023; 42(25):2074-87. [DOI:10.1038/s41388-023-02703-9] [PMID]

[24] Zhang J, Chen X, Kent MS, Rodriguez CO, Chen X. Establishment of a dog model for the p53 family pathway and identification of a novel isoform of p21 cyclin-dependent kinase inhibitor. Mol Cancer Res. 2009; 7(1):67-78. [DOI:10.1158/1541-7786.MCR-08-0347] [PMID]

[25] Griffey SM, Kraegel SA, Madewell BR. Proliferation indices in spontaneous canine lung cancer: Proliferating cell nuclear antigen (PCNA), Ki-67 (MIB1) and mitotic counts. J Comp Pathol. 1999; 120(4):321-32. [DOI:10.1053/jcpa.1998.0281] [PMID]

[26] Tangchang W, Kim Y, Oh YI, Lee BW, Kim H, Yoon B. Critical diagnostic and cancer stem cell markers in neoplastic cells from canine primary and xenografted pulmonary adenocarcinoma. J Vet Sci. 2022; 23(6):e89. [DOI:10.4142/jvs.22124] [PMID]

This Page Intentionally Left Blank