Archives of Razi Institute Journal
"Arch. Razi Inst."

Journal Homepage: https://archrazi.areeo.ac.ir/

Review Paper

Etiological Diagnosis of Scabies Based on Laboratory, Non-laboratory and Imaging Techniques

Sri Wahdini[1, 2], Saleha Sungkar[2], Ika Puspa Sari[2], Sandra Widaty[3, 4*]

1. Doctoral Program of Biomedical Science, Faculty of Medicine, Universitas Indonesia, Jakarta, Indonesia.
2. Department of Parasitology, Faculty of Medicine, Universitas Indonesia, Jakarta, Indonesia.
3. Department of Dermatology and Venereology, Faculty of Medicine,Universitas Indonesia, Jakarta, Indonesia.
4. Dr. Cipto Mangunkusumo Hospital, Jakarta, Indonesia.

Use your device to scan and read the article online

How to cite this article Wahdini S, Sungkar S, Sari IP, Widaty S. Etiological Diagnosis of Scabies Based on Laboratory, Non-laboratory and Imaging Techniques. Archives of Razi Institute Journal. 2026; 81(4):801-816. https://doi.org/10.32598/ARI.81.4.3674

https://doi.org/10.32598/ARI.81.4.3674

Article info:
Received: 18 Feb 2026
Accepted: 15 Mar 2026
Published: 01 Jul 2026

Keywords:
Scabies, *Sarcoptes scabiei*, Noninvasive techniques, Laboratory examination, Imaging

ABSTRACT

Human scabies, caused mostly by the mite *Sarcoptes scabiei* var hominis, is a globally prevalent, contagious skin disease that remains a major public health concern, particularly in resource-limited and overcrowded settings. Clinically, it presents with intense pruritus, especially at night, and a polymorphic rash that may include burrows, papules, nodules, or vesicles. However, these manifestations often overlap with other dermatological conditions such as eczema, contact dermatitis, or fungal infections, complicating clinical diagnosis. Compounding this challenge is the low mite burden in many cases, which frequently leads to false negatives in conventional diagnostic tests. This review synthesizes current diagnostic strategies based on laboratory, non-laboratory, and imaging techniques, evaluating their diagnostic utility and limitations. The gold standard—microscopic identification of mites, eggs, or fecal pellets from skin scrapings—although specific, suffers from reduced sensitivity due to the typically low mite load. Molecular techniques like polymerase chain reaction (PCR) and loop-mediated isothermal amplification (LAMP) offer enhanced sensitivity and specificity by targeting mite DNA, yet their reliance on laboratory infrastructure limits their practicality in low-resource areas. Similarly, histopathological examination may reveal mite presence, but it is invasive and time-consumings. Non-laboratory technique such as the burrow ink test is easy to perform and cost-effective but lack diagnostic precision. Imaging modalities including dermoscopy, videodermoscopy (VD), reflectance confocal microscopy (RCM), and optical coherence tomography (OCT) represent significant advancements, allowing in vivo visualization of mites and burrows. These technologies enhance diagnostic accuracy and patient comfort, though their limited availability and high costs pose barriers to widespread implementation. Given the absence of a universally reliable single diagnostic tool, a more than one test approach that considers clinical presentation, resource availability, and patient factors is recommended. Standardizing such diagnostic pathways can reduce misdiagnosis, enhance treatment outcomes, and strengthen scabies control measures, especially in high-prevalence populations.

*** Corresponding Author:**
Sandra Widaty, Associate Professor.
Address: *Department of Dermatology and Venereology, Faculty of Medicine,Universitas Indonesia, Jakarta, Indonesia.*
E-mail: *sandra.widaty@gmail.com, sanwidaty@ui.ac.id*

Copyright © 2026 The Author(s);
This work is licensed under a Creative Commons Attribution-NonCommercial 4.0 International license (https://creativecommons.org/licenses/by-nc/4.0/).
Noncommercial uses of the work are permitted, provided the original work is properly cited.

1. Context

Scabies is a skin disease caused by infestation and sensitization to *Sarcoptes scabiei* and its products. It is prevalent in many countries, particularly tropical regions, densely populated areas, and places with poor hygiene. Scabies are commonly found in crowded communities, such as boarding schools, prisons, daycare centers, or shared public facilities used for extended periods, such as hospital care rooms or nursing homes [1, 2].

Scabies is estimated to affect 200 million people, with a prevalence ranging from 5–50%, particularly among children [3]. Based on findings from various global regions, scabies is most prevalent in East Asia, Southeast Asia, Oceania, tropical Latin America, and South Asia. The 10 countries experiencing the highest rates include Indonesia, China, Timor-Leste, Vanuatu, Fiji, Cambodia, Laos, Myanmar, Vietnam, and the Seychelles [4]. In Indonesia, the prevalence of scabies is notably high, particularly in overcrowded Islamic boarding schools (pesantren). The highest recorded prevalence was 76.9% among students in a pesantren [5].

Scabies spreads through direct skin-to-skin contact, such as sharing a bed, a mother caring for or breastfeeding her baby, and having multiple sexual partners. Indirect transmission occurs when mites adhere to clothing, towels, bed sheets, pillows, or other items used by an infected person and then by others [1, 2].

The diagnosis of scabies is established based on medical history, symptoms, and physical examination findings, supported by either non-laboratory or laboratory diagnostic tests. Early diagnosis is crucial to initiate treatment promptly. Misdiagnosis can lead to inappropriate treatment, preventing recovery and turning the affected person into a source of infection for others. Therefore, a post-treatment diagnosis is necessary to assess treatment success [1, 2].

In healthcare settings, diagnosing scabies clinically without additional examinations can be challenging, especially if the skin lesions appear in atypical areas or have an unusual morphology. Scabies lesions are typically symmetrical and commonly found between the fingers, wrists, elbows, axillae, areolae, and the skin surrounding the umbilicus, waist, groin folds, or genitalia [6]. Changes in lesion morphology may result from previous incorrect or inadequate treatment, self-medication with over-the-counter drugs, or immunocompromised patients [7]. Another issue is that scabies symptoms can resemble or be masked by other conditions, such as eczema, impetigo, contact dermatitis, or fungal infections making diagnosis difficult.

Due to inadequate treatment, persistent pruritus can arise after scabies treatment, requiring differentiation between immune-mediated pruritus and persistent mite infestation [8, 9]. Thus, additional examinations are needed to support the diagnosis. The gold standard for the laboratory diagnosis of scabies is a microscopic examination using a direct scraping technique on skin samples. However, improper sample collection or transportation can produce false-negative results [8]. Laboratory diagnosis of scabies is highly complex and requires good communication between physicians and laboratory analysts to ensure accurate reporting. If mites or their products are not detected, this does not necessarily rule out scabies, as the mites may be located in areas not sampled. To improve diagnostic sensitivity, supplementary examinations may sometimes combine multiple techniques [10]. This article presents the methods for diagnosing scabies based on laboratory and non-laboratory examinations, which can be selected according to the patient's condition.

2. Data Acquisition

This non-systematic review compared and summarized selected journal articles based on existing theories and the author's experience. We selected full-text articles from public databases such as PubMed/Medline and Google Scholar. All of the articles were published in publications related to human scabies. We included all articles, original research, case reports, case series, and reviews.

3. Results

3.1. Laboratory-based diagnostic examination

3.1.1. Microscopic examination

Microscopic examination, ranging from low to high magnification, aims to identify the morphology of eggs, mites (larval, nymph, and adult stages), and feces or scybala (Figure 1). However, according to research by Li et al. [11], mite fragments and eggshells can also be observed in skin scrapings and are often considered artifacts contaminating the sample. Positive cases confirmed by identifying mite fragments or eggshells account for 34.6% [11].

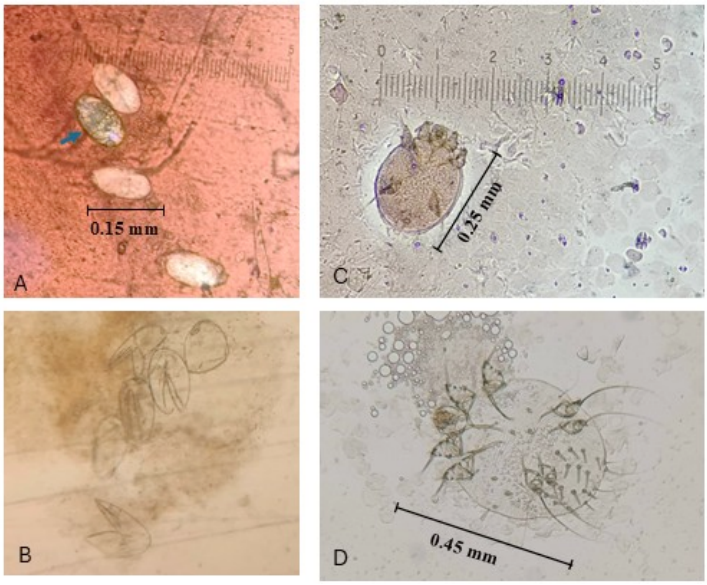

Figure 1. *S. scabiei* was observed from a skin scraping under a binocular light microscope at 40×10 magnification

A) Eggs and egg containing a larva (blue arrow), B) Eggshell fragment, C) Larvae with three pairs of leg, D) Adult mite (personal collection)

S. scabiei has an oval, flattened shape, with a convex dorsal surface and a flat ventral surface. Adult mites have four pairs of legs: two pairs in the front and two in the back, with the fourth pair covered in hair. Male mites are smaller than female mites, measuring 0.20–0.39 mm × 0.15–0.52 mm. A key difference between male and female mites is that the fourth pair of male mite legs have ambulacra for attachment. The nymph stage also has four pairs of legs but the size is smaller than adult mites (0.03–0.21 mm × 0.13–0.26 mm). Larvae measure 0.02–0.2 mm × 0.08–0.25 mm and possess only three pairs of legs: two in the front and one in the back. Eggs are slightly oval, measuring 0.15–0.19 mm × 0.09–0.12 mm, with a whitish-brown color and a shiny surface bordered by dark-brown lines [12].

In immunocompetent individuals, the mite burden peaks within three months of infestation, after which it gradually declines to an average of only one to five mites. This case necessitates repeated testing or sample collection from various areas to enhance diagnostic sensitivity. Samples can be collected using adhesive tape or skin scraping from lesion sites, such as papules or burrows [13, 14].

Microscopic examination of skin scrapings has a 100% positive predictive value and a short processing time. Still, its sensitivity varies and tends to be low due to its dependence on the quality and quantity of the skin scraping. A meta-analysis indicated that skin scraping had an average sensitivity of 56.3% (95% CI, 25.8%, 86.8%) and that the adhesive tape test had an average sensitivity of 68.4% (95% CI, 56%, 80.8%). The specificity of both samplings is consistently high, frequently reported as 100% (skin scraping 95% CI, 98.1%, 100% and adhesive tape 95% CI, 98.3%, 100%) [15]. The use of dermoscopy during skin scraping improves diagnostic sensitivity. A limitation of skin scraping is its potential to inflict physical trauma on mites, which may lead to the identification of nonviable or motionless specimens during examination [16].

3.1.2. Histopathological examination

Histopathological diagnosis of scabies requires skin tissue collection through punch biopsy or skin scraping, both invasive procedures. The tissue is fixed in physiological saline or 10% formalin, sectioned, and stained with hematoxylin and eosin (H&E) for microscopic identification [17]. Histopathological diagnosis is the most accurate test, but it takes 2–7 days to produce results. As with direct examination, selecting the appropriate lesion site for sampling is crucial, as it influences the interpretation of the specimen. Since histopathological examination is not included in a routine diagnostic test for scabies, it is primarily used to confirm difficult or atypical cases [10].

Histopathological examination can identify mite fragments or body parts, including immature eggs or scybala, inside mite body sections [18]. Additionally, pathological changes in the dermis and epidermis of

mite-infested skin can be observed, such as epidermal thickening, inflammatory cell infiltration (mononuclear cells, eosinophilic granulocytes, mast cells) in the perivascular and interstitial dermis, hyperkeratosis, acanthosis, spongiosis, edema, acantholysis, vasculitis, and superficial fibrin thrombus [17, 18]. Skin biopsies from scabies patients often show increased spongiosis and eosinophils, but further research is needed to determine the relationship between histopathological features and scabies severity [17].

3.1.3. Blood/serum examination

Detection of antibodies or antigens in serum or blood could be a faster and more accurate diagnostic option for scabies. However, this method is still in development due to the challenge that *S. scabiei* antigens cross-react with house dust mite antigens such as *Dermatophagoides farinae*, *D. pteronyssinus*, and *Euroglyphus maynei* [19].

The primary manifestations of scabies are mediated through hypersensitivity-like reactions and immune responses, which are not yet fully understood. Scabies patients show a significant increase in IgE and IL-10 levels. There is a positive correlation between IgE, IgG, and IL-6 and the severity of clinical manifestations. Conversely, there is a negative correlation between the anti-inflammatory cytokines interleukin 10 (IL-10), specific IgG, and interferon-gamma (IFN-γ) and clinical severity [20]. Jawad et al. [21] concluded that IL-4 and IgE levels in the serum of scabies patients were significantly higher than in healthy controls. Thus, further analysis is needed to understand the role of IL-10 regulation in inflammatory responses in scabies patients [20].

A complete blood count examination is not specific for detecting scabies but is useful in ruling out differential diagnoses. Nguyen et al. [22] investigated blood cell ratios and counts and found that leukocyte, monocyte, and eosinophil counts were significantly higher in scabies patients than in those with dermatophytosis or urticaria. The monocyte-to-lymphocyte ratio (MLR) and eosinophil-to-lymphocyte ratio (ELR) were significantly higher in scabies than in dermatophytosis and urticaria patients. The optimal thresholds for distinguishing scabies from dermatophytosis and urticaria were 0.094 for ELR (sensitivity: 74.85%; specificity: 70.7%) and 0.295 for MLR (sensitivity: 52.69%; specificity: 73.54%) [22].

3.1.4. Molecular detection

3.1.4.1. Polymerase chain reaction

One molecular detection method for scabies is polymerase chain reaction (PCR). The PCR process involves nucleic acid extraction from the sample, amplification, and gene detection. PCR requires specialized equipment, resources, and a dedicated laboratory, making it an expensive and not-yet-routine diagnostic method. Molecular detection can reduce false-negative results and distinguish *S. scabiei* var. hominis from zoonotic infestations, such as *S. scabiei* var. canis, which cannot be differentiated microscopically. This distinction is important for public health services in determining appropriate treatment and prevention programs [23].

Wong et al. [24] detected scabies using conventional PCR and real-time quantitative PCR (qPCR). The results showed that both techniques were more sensitive than microscopic examination, with positive and negative predictive values reaching 100%. PCR does not rely on mites, eggs, or scybala in skin scrapings, as mite excreta and cellular DNA can merge into stratum corneum cells, which PCR can detect. PCR could serve as an alternative scabies detection method in communities, especially during outbreaks, for diagnosis and post-treatment monitoring or clinical practice for patients with scabies symptoms but negative microscopic results. Samples for PCR can be collected using skin scraping or skin swabs, allowing early detection when parasite numbers are still low [10]. As an antigen detection test, PCR had an average sensitivity of 81.1% (95% CI, 52.7%, 100%) and specificity of 91.6% (95% CI, 81.5%, 100%) [15].

3.1.4.2. Loop-mediated isothermal amplification

Loop-mediated isothermal amplification (LAMP) represents an alternative molecular detection method that offers rapid results, simplified protocols, and enhanced cost-effectiveness, with reported improvements in both sensitivity and specificity relative to PCR. Unlike PCR, LAMP circumvents the need for thermal cycling by operating under isothermal conditions, thereby eliminating the denaturation and annealing steps and significantly reducing the assay duration. The reaction requires only a water bath or basic incubator, and the results can be assessed visually, obviating the need for gel electrophoresis. These operational advantages render LAMP particularly suitable for use in remote or resource-limited settings where access to advanced laboratory infrastructure may be restricted [25].

From a cost perspective, LAMP assays are generally more economical than PCR. Estimated at approximately USD 2–5 per test, LAMP benefits from inexpensive reagents and minimal equipment requirements. In contrast, PCR assays typically range from USD 10–25 per test due to the reliance on costly thermocyclers, specialized enzymes, fluorescent detection reagents, and more complex workflows, often requiring two to three hours to complete. Moreover, LAMP assays can be performed within 30–60 minutes and require limited technical training, whereas PCR protocols usually necessitate intermediate to advanced expertise. Although the polymerases used in LAMP may be relatively more expensive than conventional Taq polymerase, the overall simplicity and efficiency of the LAMP system often offset this difference [26].

Fraser et al. [27] reported that LAMP achieved a sensitivity of 100% (95% CI, 86%, 100%) and a specificity of 92.5% (95% CI, 80%, 98%) when compared to conventional PCR methods. These findings underscore the potential of LAMP as a reliable and scalable diagnostic modality across a wide range of clinical and epidemiological settings. Moreover, LAMP is increasingly recognized as a valuable tool for point-of-care testing, particularly in resource-limited environments where access to centralized laboratory infrastructure is constrained [25].

3.1.4.3 Primer design challenges for *S. scabiei* genetic diversity

Designing primers for *S. scabiei* is particularly challenging due to the species's considerable genetic diversity. Intraspecific variability complicates the development of universal primers, as significant genetic differences can exist even within the same species. Additionally, *S. scabiei* demonstrates host-specific adaptations, with genetically distinct strains infecting various hosts such as humans, dogs, and wombats, further hindering the creation of primers that are broadly effective. Effective primer design hinges on selecting conserved genomic regions; however, such regions may be limited or not sufficiently unique for reliable species identification. PCR primers are typically shorter and designed to target specific genetic regions. There are mitochondrial targets (e.g. cytochrome c oxidase subunit 1/cox1, 16S rRNA) and nuclear genes (e.g. second internal transcribed spacer/ITS-2), each presenting different obstacles regarding specificity and mutation rates [10]. In contrast, in LAMP involving six primers that recognize eight distinct regions of the target DNA, the comprising multiple primer sets, including forward outer primer (F3), backward outer primer (B3), forward inner primer (FIP), backward inner primer (BIP), loop forward primer (LF), and loop backward primer (LB) [27].

3.2. Non-laboratory diagnostic examination

3.2.1. Burrow ink test

The burrow ink test (BIT) uses Indian ink to visualize burrows rather than directly detecting mites or functioning as a definitive diagnostic tool. The procedure involves applying Indian ink onto a papule and leaving it for 20–30 minutes. The excess ink is then wiped off with an alcohol swab, allowing the ink to remain trapped within the burrow. A positive result is indicated if the ink penetrates burrows in the stratum corneum, forming a characteristic as an ink-filled line on the skin surface and forming a zigzag or S-shaped pattern. BIT is noninvasive, inexpensive, easy to perform, requires no specialized equipment or training, and is useful for screening a large number of patients. However, BIT cannot differentiate between resolved and active infestations or when lesions undergo efflorescence changes due to scratching [28, 29]. Abraham et al. [30] reported that the BIT demonstrated a specificity of 100% (95% CI, 100%, 100%) and a sensitivity of 23.53% (95% CI, 19.95%, 27.11%), indicating excellent ability to rule out non-scabies cases without yielding false-positive results. However, the wide variability in BIT sensitivity reported across studies can be attributed to a number of clinical and technical factors, including mite burden—which may be low in early-stage or previously treated cases—operator expertise, quality of sample collection and ink application, skin pigmentation and the form of scabies present, with crusted scabies typically producing higher diagnostic yields than classical forms [28–31].

This observed variability in sensitivity carries significant implications for the clinical utility of BIT. While it remains a useful, non-invasive, and low-cost screening tool—particularly in settings with limited resources—a negative result cannot reliably exclude scabies infestation. Accordingly, negative BIT findings should be interpreted with caution and, where clinical suspicion persists, supplemented with more definitive diagnostic approaches such as dermoscopy, skin scraping, or biopsy. In such cases, microscopic examination of skin scrapings may be particularly valuable in confirming the diagnosis and guiding appropriate management [32].

Table 1 describes the advantages and disadvantages of supporting examination methods for laboratory and non-laboratory diagnosis of scabies.

Table 1. The advantages and disadvantages of supporting examination methods for laboratory and non-laboratory diagnoses of Scabies

Examination Types	Characteristics	Detection Ability	Advantages	Disadvantages
Microscopic examination	Detects mites, eggs, and scybala	High specificity but low-moderate sensitivity Skin scraping (specificity of 100% (95% CI, 98%, 100%) and sensitivity of 56.3% (95% CI, 25.8%, 86.8%) Adhesive tape test (specificity of 100% (95% CI, 98.3%, 100%) (sensitivity of 68.4% (95% CI, 56%, 80.8%)	Sampling is ideal for mass identification, including skin scrapings and adhesive tape techniques. The examination can be repeated and read by different individuals, followed by molecular detection.	Proper sampling is required. The timing of sample collection and microscopic reading is crucial, with a minimum reading time of one hour. The test can count the number of mites and eggs per slide.
Histopathological examination	Detects pathological abnormalities in the skin and the structure of mite body sections	High specificity and sensitivity (no specific range)	The examination can be repeated and read by different individuals, and slides can be stored for a long time	Proper sampling is required. The process of sample collection, staining, and reading takes 7 days. Requires a specialized laboratory and expertise in staining and reading preparations. It cannot distinguish between mild and severe infections.
Blood/ serum examination	Identifies acute, chronic, and post-mite infestation infections	Detection capability has not yet been assessed, as it is still under development	It is more practical, especially if a rapid detection test can be developed	Detection capability has not yet been assessed.
Molecular detection	Identifies acute infections	High specificity and sensitivity LAMP achieved a specificity of 92.5% (95% CI, 80%, 98%) and sensitivity of 100% (95% CI, 86%, 100%) PCR achieved a specificity of 91.6% (95% CI, 81.5%, 100%) and sensitivity of 81.1% (95% CI, 52.7%, 100%)	It can be followed by phylogenetic detection. Samples can be obtained through skin scrapings, tape, or skin swabs, making it suitable for large-scale applications.	It cannot distinguish between mild and severe infections, requires a specialized laboratory, and necessitates specific reagents and primers.
Burrow Ink Test	Detects burrow lesions	Specificity high and sensitivity low. A specificity of 100% (95% CI, 100%, 100%) and a sensitivity of 23.53% (95% CI, 19.95%, 27.11%).	Practical and easy to apply	Sometimes, it needs to be reinforced by microscopic or molecular examination.

3.3. Imaging-based diagnostic examination

Imaging-based diagnostic techniques enable rapid diagnosis without tissue manipulation, helping to reduce the risks of foodborne infection and transmission to healthcare personnel (Table 2).

3.3.1. Dermoscopy

Dermoscopy, equipped with a 10x magnification lens and a light source, allows visualization of skin lesion morphology down to the superficial dermis. Initially used for diagnosing malignancies in pigmented lesions, it is now applied to detect infestations, infections, and hair or nail abnormalities. The accurate interpretation of scabies requires trained professionals [33, 34]. As a noninvasive, rapid, and sensitive method for diagnosing scabies, dermoscopy had an average sensitivity of 75.1% (95% CI, 54.5%, 95.8%) and specificity of 72.7% (95% CI, 51.8%, 93.7%) [15].

An intact burrow lesion is a pathognomonic sign of scabies. Its structure appears linear, whitish, slightly elevated from the skin surface, winding, and several millimeters long, with a reddish background (erythematous). Ueda et al. [35] observed 16 patients with burrow lesions, concluding that the burrow width is approximately 0.4 mm (equal to the width of the mite) and that burrow lengths exceed 5 mm. These lesions are difficult to identify macroscopically, as scratching can alter their shape, necessitating dermoscopy for proper detection. Dermoscopy identifies scabies' burrow lesions as mite-gallery units (MGU)—skin lesions composed of three morphologically and functionally distinct segments: head, body, and tail [36].

The first segment, known as the head of the MGU—also referred to as the kite sign or delta wing sign—appears as a dark triangular or "V"-shaped structure, black or brown. This segment represents the anterior portion of the mite, including the gnathosoma or two pairs of anterior legs. This segment position is at the end of the burrow, where the roof remains intact, marked by a whitish layer of skin. It indicates the current position of the mite within the skin [36, 37].

The second segment, called the body of the MGU, is the longest portion of the MGU. It is a serpiginous, S-shaped, whitish line, or translucent line trailing behind the delta wing. Clinically, it is defined as the burrow created by the mite as it tunnels through the stratum corneum, and it may contain eggs, air pockets, or fecal pellets (scybala). The borrow is often less pigmented, enhancing the visibility of the mite under dermoscopy. The roof of the burrow often becomes discontinuous due to scratching or natural skin desquamation. A hallmark visual feature is the "wake sign," where the burrow resembles the curved white trail left by a moving boat or jet on water.

Along the outer edge of the burrow, a darker or greyish line—termed the "grey-edged line sign"—may be observed. This pigmentation is attributed to melanin-rich fecal material deposited by the mite as it digests keratinocytes. The "jetliner with trail" sign describes the appearance of the translucent mite body at the terminal end of the burrow, followed by its winding path, mimicking a jet with a contrail.

These dermoscopic signs are critical for identifying scabies infestations, particularly in atypical or crusted cases [35, 36]. The final segment of the MGU, known as the tail, is structurally incomplete due to the absence of a roof and must be carefully distinguished from artifacts, such as excoriations, hemorrhagic crusts, or debris caused by scratching [36].

Low magnification dermoscopy may not adequately visualize eggs or scybala, and detecting the jetliner sign can be challenging in individuals with dark or densely hairy skin. Additionally, direct dermoscopic contact with the patient's skin poses a risk of mite transmission if proper disinfection is not performed, as mites can survive in the environment for up to 72 hours. The use of handheld dermoscopy in genital regions may also cause discomfort or embarrassment for the patient [37, 38].

Despite these limitations, the dermoscope offers several advantages: it is compact, portable, practical, and fast, making it a convenient clinical tool. It is noninvasive and can be used without direct contact with the skin, minimizing cross-contamination risks. Dermoscopy is a valuable alternative for diagnosing scabies, especially when high-quality imaging tools are unavailable. It facilitates the initial screening of suspected scabies lesions before skin scraping and aids in monitoring lesions after treatment. Furthermore, incorporating dermoscopy into skin scraping improves diagnostic accuracy and speeds up scabies identification compared to performing the procedure without it [33, 38].

3.3.2. Ultraviolet dermoscopy

Ultraviolet dermoscopy has emerged as a promising tool for diagnosing scabies, offering enhanced visualization of mite burrows and parasites compared to conventional methods. Traditional diagnostic techniques, such as polarized dermoscopy and Wood's lamp examination, have shown effectiveness, yet challenges remain in accurately detecting scabies signs across different skin tones. Various studies have evaluated the efficacy of ultraviolet-induced fluorescence (UVF) dermoscopy, Wood's light scanning, and combined polarized and UV dermoscopic imaging in improving diagnostic accuracy [39–42].

Wood's light, which emits ultraviolet light at 365 nm, has been traditionally used for diagnosing conditions such as vitiligo and fungal infections. Recent research demonstrates that it can also highlight scabies tunnels as bright reflexes, referred to as "Scabies' Sign via Wood's Lamp," aiding in quick diagnosis and guiding physicians in targeted dermoscopic examinations. While the technique is practical and valuable for follow-up treatments, concerns arise regarding false positives caused by contact with fabrics and paper fibers. Experts recommend washing hands before reexamination to eliminate misleading results and emphasize the need to correlate Wood's lamp findings with clinical and dermoscopic evaluations [39, 43].

UVF dermoscopy has shown superior diagnostic capabilities, particularly in patients with dark skin where scabies burrows and eggs are more difficult to detect using traditional polarized dermoscopy. Studies examining different imaging techniques have confirmed that while polarized dermoscopy effectively visualizes mites in fair skin, UVF dermoscopy offers greater sensitivity in detecting burrows and eggs in darker skin tones [42]. Moreover, novel diagnostic markers such as the

Table 2. Imaging-based diagnosis of scabies

Examination Types	Characteristics	Detection Ability	Advantages	Disadvantages
Dermatoscopy	Identifies burrows and visualizes signs of mites, eggs, and scybala	Low specificity and high sensitivity (sensitivity of 75.1% (95% CI, 54.5%, 95.8%) and specificity of 72.7% (95% CI, 51.8%, 93.7%)	Noninvasive, portable	Close contact between the examiner and the patient is required, skin color affects the visualization of skin abnormalities, requires training
Ultraviolet dermatoscopy	Identifies skin abnormalities and visualizes the presence of mites, eggs, and scybala	High specificity (in darker skin tones) and low sensitivity	Noninvasive and resolution can be adjusted	Skin color affects the visualization of skin abnormalities
Videodermatoscopy	Visualizes burrows, mites and their movement, eggs, larvae, and scybala	High specificity and sensitivity	Noninvasive, fast examination results that can be stored, compared with previous ones, and helpful in the differential diagnosis	The equipment is more expensive
Reflectance confocal microscopy	Visualizes burrows, mites and their movement, eggs, larvae, and scybala through horizontal skin observation	High specificity and sensitivity (specificity of 100% and sensitivity of 92%)	Noninvasive, fast examination results that are excellent for cellular morphology, can be stored and compared with previous ones, and can help in the differential diagnosis	The equipment is more expensive and complex, requires training, limited penetration depth
Optical coherence tomography	Visualizes mite morphology and movements, egg deposition, and burrow through vertical and superficial observation	High specificity and low sensitivity	Noninvasive, high-resolution, in situ, fast examination, results can be stored, compared with previous ones, and helpful in the differential diagnosis	The equipment is more expensive, less effective in pigmented/thick skin

"Ball Sign" have been introduced, where the entire parasite appears as a bright reflex, improving identification compared with conventional methods [44]. Additional findings include distinctive fluorescence patterns, such as bluish-white luminescent scabies galleries, green and white dots, and the "Rocket sign," highlighting inflammatory halos around burrows [41].

In case studies, UV dermoscopy has proven to be a valuable tool for detecting mites and tunnels when polarized dermoscopy falls short. Research involving scabies patients has revealed that UV imaging allows non-contact visualization of scabies lesions, making the diagnostic process faster and more efficient. This approach reduces reliance on skin scraping techniques and improves treatment follow-up by providing clearer, more accessible images of mite burrows and parasite structures. The findings collectively suggest that UV-based techniques significantly enhance diagnostic performance, particularly when integrated with polarized dermoscopy, for a comprehensive approach to scabies detection across diverse skin types [36].

Ultraviolet dermoscopy represents a major advancement in dermatology, refining scabies diagnosis through improved lesion visualization, new fluorescence markers, and increased efficiency in detection. While further validation and refinement of techniques are necessary, existing studies highlight the potential for UV imaging tools to complement traditional diagnostic methods, ultimately making scabies detection more accurate and reliable worldwide.

3.3.3. Videodermoscopy

A videodermoscope combines a digital video camera capable of magnifying skin surfaces 40–1000x, integrated with computer software for monitoring and data storage. Videodermoscopy (VD) is a noninvasive examination method that allows superficial dermis observation and in vivo visualization of mites [37].

Compared to microscopic detection using skin scraping, VD offers several advantages. It is a painless and noninvasive procedure that causes no physical or psychological discomfort. With 100% specificity, VD provides highly detailed images of mites, even in motion,

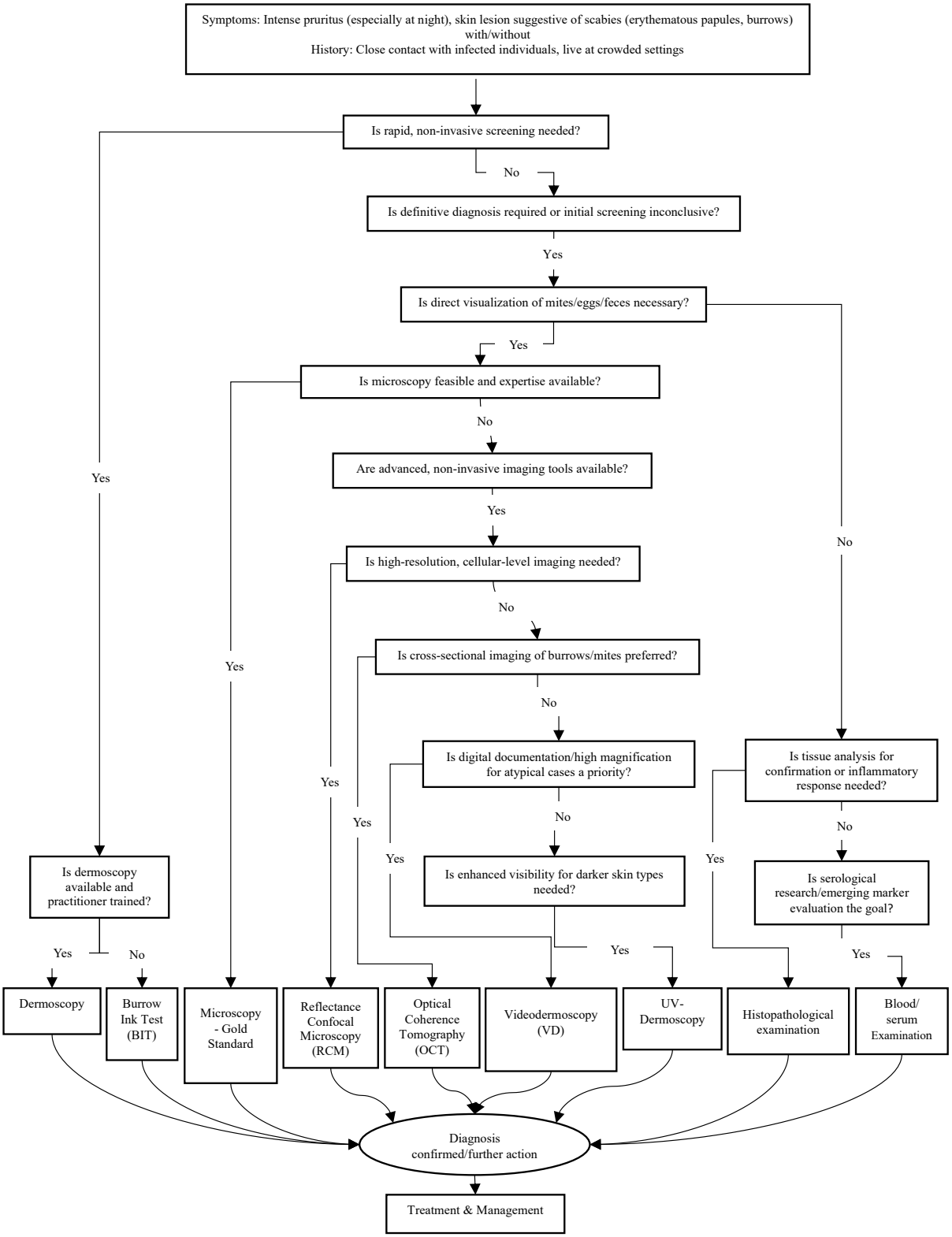

Figure 2. Scabies diagnostic method decision tree

reducing false-negative results, particularly in cases where scabies present with nonspecific clinical features. The procedure can be performed in consultation rooms, allowing for rapid diagnosis and applicability to all body areas within minutes and improving patient compliance, especially in children [45].

Under 400x magnification, VD reveals burrow lesions that are not visible to the naked eye. These burrows contain round-shaped mites, transparent oval eggs, and scybala (feces). VD is highly effective for the early detection of asymptomatic individuals with a history of contact with scabies patients. Additionally, it is useful in diagnosing mites that are resistant to treatment, as it enables direct visualization of live mites [46].

A major drawback of VD is its high cost, particularly when using a high-resolution camera with a large memory capacity. However, early investment in expensive diagnostic tools may prove cost-effective in certain countries, reducing the financial burden associated with outbreaks due to misdiagnosis or delayed treatment, particularly in settings such as schools, prisons, nursing homes, and hospital wards. Using VD in populations with high scabies prevalence or those at risk of blood-borne infections (e.g. HIV, hepatitis C) can reduce infection risks, as it eliminates the need for invasive skin scraping samples [47].

3.3.4. Reflectance confocal microscopy

Reflectance confocal microscopy (RCM) is a real-time, noninvasive, in vivo diagnostic technology. Its principle is based on laser light reflection, which varies according to the refractive index of different skin layers. RCM can visualize skin horizontally, creating serial cross-sectional images within the skin layers at various depths. This process produces black-and-white microscopic images that reveal the detailed structures of the examined area [37].

RCM effectively detects tissue changes surrounding lesions, including focal epidermal edema, burrow lesions with distinct layer-by-layer structures, and mite morphology comparable to direct microscopic examination. It can also identify round or oval-shaped scabies eggs with well-defined borders and scybala (fecal matter), which typically appear as regular round or oval shapes, sometimes clustered in the superficial epidermis. A scabies diagnosis via RCM can be confirmed if mites, eggs, or scybala are detected. RCM is recommended for patients with uncertain lesions or persistent pruritus after initial treatment [48]. RCM enables the observation of mite mobility and gastrointestinal peristaltic movements, differentiates live and dead mites post-treatment, and aids in therapy monitoring [16].

It also helps identify and distinguish mite developmental stages, such as larva versus adult, based on size and movement speed while predicting mite population density per unit of skin surface area. With high specificity (100%) and sensitivity (92%) compared to dermoscopy, RCM offers rapid diagnosis, a painless procedure, without contrast agents, and horizontal views of multiple skin layers without causing tissue damage. However, RCM requires expensive equipment, leading to limited availability, and demands specialized training for accurate interpretation. Its penetration depth is also restricted, allowing observation only up to the superficial dermis (200–300 µm) [49, 50].

3.3.5. Optical coherence tomography

Optical coherence tomography (OCT) is a noninvasive imaging technique that enables morphological assessment of biological tissues by capturing backscattered infrared light with micrometer-scale resolution. Widely used in ophthalmology for retinal diagnostics, OCT has recently gained more traction in dermatology, especially in the evaluation of cutaneous tumors and parasitic infestations. The system operates via an interferometer that provides vertical sectional images of skin structures analogous to ultrasound but with a substantially higher spatial resolution [45].

OCT is an emerging, noninvasive imaging modality that offers high-resolution visualization of skin architecture and has demonstrated significant utility in the diagnosis of scabies. By utilizing light-based interferometry, OCT allows for in vivo imaging of *S. scabiei* within the skin without the need for skin preparation. It enables real-time evaluation of mite morphology, egg deposition, and burrow formation, thereby facilitating accurate and rapid diagnosis. With an axial resolution of approximately 8 µm and a lateral resolution between 10 and 15 µm, OCT can resolve fine structural features of the epidermis and superficial dermis to a depth of 1 to 2.0 mm—adequately encompassing the regions most affected by scabies infestation. Mites are typically identified as hyporeflective ovoid bodies located beneath the stratum corneum and are frequently accompanied by serpiginous, linear hyporeflective tracts that correspond to burrows. Additionally, reflective foci within these structures may represent ova and fecal pellets. OCT imaging can be performed in both vertical (cross-sectional) and horizontal (en face) planes, with vertically imaged mites often appearing almond- or mango-shaped and one end

presenting a sharp contour. While OCT cannot resolve fine anatomical features such as legs or setae, this does not compromise its diagnostic accuracy. Beyond diagnosis, OCT facilitates the longitudinal assessment of lesion morphology and mite response to therapy, underscoring its potential role in both clinical practice and research settings focused on parasitic skin disorders [45, 51].

Idoudi et al. [52] provided the first in vivo description of *S. scabiei* using line-field confocal optical coherence tomography (LC-OCT), a novel hybrid imaging modality that integrates the axial depth penetration of OCT with the cellular resolution of confocal microscopy. LC-OCT allowed clear visualization of the mite as an ovoid hyporeflective structure located within the stratum corneum, along with serpiginous hyporeflective tunnels indicative of burrows. Reflective dots suggestive of scabetic ova or fecal matter were also noted within these tracts. Inflammatory changes, including spongiosis and acanthosis in the surrounding epidermis, were discernible, enhancing diagnostic confidence. Histopathological correlation with hematoxylin-eosin–stained skin sections confirmed the imaging findings, supporting the accuracy and relevance of LC-OCT in diagnosing scabies. The ability of LC-OCT to provide real-time, noninvasive, high-resolution imaging of mite morphology and its microenvironment positions it as a promising adjunctive tool for early diagnosis, particularly in ambiguous or clinically challenging cases [52, 53].

3.4. A scabies protocol for institutional settings

The diagnostic approach to suspected scabies in institutional settings should follow a structured, stepwise protocol that emphasizes accessibility, accuracy, and timely intervention (Figure 2). The process begins with clinical suspicion based on signs such as nocturnal pruritus, burrows, papules, and secondary lesions. If diagnostic resources are unavailable, empirical treatment may be initiated based on clinical judgment and local epidemiology. When resources are accessible, the first step involves less invasive bedside tools such as the BIT, dermoscopy, or UV dermoscopy, which are especially useful for rapid, noninvasive screening. Positive findings—such as visible mites or characteristic burrows—confirm the diagnosis and prompt immediate treatment and contact tracing [54, 55].

If these tools yield inconclusive results, the next step is confirmatory testing via microscopy of skin scrapings, which remains the gold standard for visualizing mites, eggs, or scybala. In cases where microscopy is negative or unavailable, advanced imaging methods such as VD, RCM, or OCT may be employed. These allow for in vivo visualization of mite morphology and burrow architecture with high resolution and minimal discomfort and are particularly beneficial in atypical or crusted scabies cases. When advanced imaging is not feasible, or when diagnostic uncertainty persists, clinicians should consider histopathological examination or molecular methods (e.g. LAMP assays) to support final diagnosis [56, 57].

Once scabies is confirmed or deemed highly likely, management proceeds with appropriate scabicide therapy, hygiene measures, contact prophylaxis, and environmental decontamination [58, 59]. This hierarchical, resource-sensitive diagnostic pathway ensures that patients receive timely, accurate diagnosis and treatment while minimizing unnecessary interventions and supporting public health efforts to contain transmission, particularly in vulnerable and overcrowded institutional environments [60].

Early and accurate diagnosis of scabies is critical to controlling outbreaks in high-density institutional environments such as prisons and boarding schools where overcrowding and frequent physical contact facilitate rapid transmission. The earlier diagnostic tools—including the BIT, dermoscopy, and skin scraping play foundational roles in initial screening and confirmation, offering cost-effective and accessible options [54]. However, their limitations in sensitivity, user expertise, and discomfort in certain populations can delay diagnosis and management. The adoption of noninvasive technologies such as VD, UV dermoscopy, RCM, and OCT has substantially improved diagnostic accuracy, enabling real-time visualization of mites, burrows, eggs, and feces [41]. These methods support prompt diagnosis and treatment initiation, disrupting transmission cycles and shifting public health strategies from reactive response to proactive containment.

Enhanced diagnostic precision also strengthens contact tracing and isolation practices, which are essential to limiting the spread of scabies within institutional settings. Rapid identification of confirmed cases and their close contacts allows for timely targeted interventions, including simultaneous treatment and, where appropriate, isolation [59, 61]. Diagnostic delays—often due to misidentification or reliance on symptomatic presentation—can result in unnecessary exposure, undertreatment, and continued transmission. High-resolution tools such as RCM and OCT not only confirm active infestation but also enable treatment monitoring, ensuring therapeutic success and reducing reinfestation. Effective diagnostic-led contact tracing optimizes resource alloca-

tion and ensures that public health interventions are precise, timely, and impactful [16].

Emerging technologies such as LAMP and UV-enhanced dermoscopy present scalable, field-friendly options for early detection in resource-limited institutional environments. LAMP provides rapid and sensitive molecular detection of *S. scabiei* DNA, making it suitable for screening asymptomatic carriers and supporting surveillance programs [25, 62]. UV dermoscopy, which enhances visualization of burrows and mites using a 365 nm light source, increases diagnostic reliability without invasive procedures. These tools align with the operational needs of schools and correctional facilities by offering low-cost, portable, and easy-to-use alternatives that can be deployed by trained non-specialists [36]. Their integration into screening protocols complement existing diagnostic hierarchies, reinforcing early detection, improving outbreak containment, and enhancing the overall cost-effectiveness of scabies management strategies in vulnerable populations [39].

3.5. Limitations of the study

The current research on the etiological diagnosis of scabies is constrained by several methodological and contextual limitations that affect the reliability and external validity of its findings. A key concern is publication bias, where in studies with statistically significant or favorable outcomes are more likely to be published, potentially leading to an inflated perception of diagnostic efficacy. Additionally, there is a marked underrepresentation of data from rural and low-resource settings—regions where scabies prevalence is typically higher thereby limiting the generalizability of diagnostic insights to global populations. Operational issues such as inconsistent or substandard sample collection and transport procedures can further compromise diagnostic accuracy, especially in microscopy-dependent studies [32]. The availability of advanced diagnostics, such as molecular assays and imaging-based modalities, is often restricted to well-resourced laboratories, making these tools inaccessible in many scabies-endemic areas [10]. Compounding these limitations is the clinical variability of scabies, which can manifest differently depending on host factors, co-infections, or infestation burden, making prompt and accurate diagnosis challenging in atypical or subclinical cases [4, 63].

To address these challenges and improve diagnostic reliability, future studies should prioritize increased sample diversity by incorporating data from underrepresented and high-burden settings. Establishing standardized protocols for sample collection and transportation is essential to minimize false-negative results and ensure consistency across studies. Expanding the diagnostic toolbox to include molecular techniques (e.g. LAMP), advanced imaging (e.g. OCT or RCM), and point-of-care innovations can enhance both diagnostic sensitivity and specificity [25, 26]. Longitudinal studies observing the progression and resolution of scabies over time may also provide insight into atypical or early-stage diseases. Furthermore, training healthcare workers in varied practice environments is vital for ensuring diagnostic accuracy and procedural integrity [64, 65]. Finally, integrating cost-effectiveness analyses into diagnostic evaluations will guide the selection of feasible, high-impact tools for low-resource implementation. Collectively, these improvements can bridge existing gaps in diagnostic performance and foster a more equitable approach to scabies detection and control.

4. Conclusion

There is no standardized diagnostic algorithm for scabies yet, although the gold standard remains to identify mites, eggs, or scybala through microscopic examination of skin scrapings. Each diagnostic approach has its advantages and limitations, which can be selected based on diagnostic objectives, healthcare provider capabilities, and the diagnostic tools available. To establish a diagnosis effectively, it is necessary to combine multiple diagnostic approaches.

Compliance with ethical guidelines

This article is a review and does not involve human or animal samples.

Funding

This study was supported in part by grant PUTI Q2 No. PKS-338/UN2.RST/HKP.05.00/2025 from the Universitas Indonesia, Jakarta, Indonesia.

Authors' contributions

Conceptualization: Sri Wahdini and Sandra Widaty; Writing the original draft: Sri Wahdini and Saleha Sungkar; Review and editing: Sri Wahdini and Sandra Widaty, and Ika Puspa Sari.

Conflict of interest

The authors declared no conflict of interest.

Data availability

No datasets were generated or analyzed during this study. Therefore, data sharing is not applicable.

References

[1] Thomas C, Coates SJ, Engelman D, Chosidow O, Chang AY. Ectoparasites: Scabies. J Am Acad Dermatol. 2020; 82(3):533-48. [DOI:10.1016/j.jaad.2019.05.109] [PMID]

[2] Widaty S, Miranda E, Cornain EF, Rizky LA. Scabies: Update on treatment and efforts for prevention and control in highly endemic settings. J Infect Dev Ctries. 2022; 16(2):244-51. [DOI:10.3855/jidc.15222] [PMID]

[3] Yajima A, Lin Z, Mohamed AJ, Dash AP, Rijal S. Finishing the task of eliminating neglected tropical diseases (NTDs) in WHO South-East Asia Region: promises kept, challenges, and the way forward. Lancet Reg Health Southeast Asia. 2023; 18:100302. [DOI:10.1016/j.lansea.2023.100302] [PMID]

[4] Aždajić MD, Bešlić I, Gašić A, Ferara N, Pedić L, Lugović-Mihić L. Increased scabies incidence at the beginning of the 21st century: What do reports from Europe and the world show? Life. 2022; 12(10):1598. [DOI:10.3390/life12101598] [PMID]

[5] Schneider S, Wu J, Tizek L, Ziehfreund S, Zink A. Prevalence of scabies worldwide-An updated systematic literature review in 2022. J Eur Acad Dermatol Venereol. 2023; 37(9):1749-57. [DOI:10.1111/jdv.19167] [PMID]

[6] Chung HC, Kim YJ, Chun EJ, Kim SS, Kim CW. Hands and wrists are the best sites for diagnosing scabies through dermoscopy and microscopy. Ann Dermatol. 2025; 37(1):46-8. [DOI:10.5021/ad.23.101] [PMID]

[7] Arlian LG, Morgan MS. A review of Sarcoptes scabiei: Past, present and future. Parasit Vectors. 2017; 10(1):297. [DOI:10.1186/s13071-017-2234-1] [PMID]

[8] Walton SF, Currie BJ. Problems in diagnosing scabies, a global disease in human and animal populations. Clin Microbiol Rev. 2007; 20(2):268-79. [DOI:10.1128/CMR.00042-06] [PMID]

[9] Bhat SA, Mounsey KE, Liu X, Walton SF. Host immune responses to the itch mite, Sarcoptes scabiei, in humans. Parasit Vectors. 2017; 10(1):385. [DOI:10.1186/s13071-017-2320-4] [PMID]

[10] Siddig EE, Hay R. Laboratory-based diagnosis of scabies: A review of the current status. Trans R Soc Trop Med Hyg. 2022; 116(1):4-9 [DOI:10.1093/trstmh/trab049] [PMID]

[11] Li W, Li X, Song L, Li H, Wu Y, Li J. Optical microscopic study on a novel morphological classification method of multiple diagnostic features of Sarcoptes scabiei var. hominis. Parasitology. 2023; 150(11):1070-5. [DOI:10.1017/S0031182023000938] [PMID]

[12] Wahdini S, Sungkar S. Aspek parasitologi Sarcoptes scabiei var. hominis. Parasitological aspects of Sarcoptes scabiei var. hominis. J Entomol Indones. 2024; 20(3):275-84. [DOI:10.5994/jei.20.3.275]

[13] Abdel-Latif AA, Elshahed AR, Salama OA, Elsaie ML. Comparing the diagnostic properties of skin scraping, adhesive tape, and dermoscopy in diagnosing scabies. Acta Dermatovenerol Alp Pannonica Adriat. 2018; 27(2):75-8. [DOI:10.15570/actaapa.2018.17] [PMID]

[14] Katsumata K, Katsumata K. Simple method of detecting sarcoptes scabiei var hominis mites among bedridden elderly patients suffering from severe scabies infestation using an adhesive-tape. Intern Med. 2006; 45(14):857-9. [DOI:10.2169/internalmedicine.45.1707] [PMID]

[15] Shoukat Q, Rizvi A, Wahood W, Coetzee S, Wrench A. Sight the mite: A meta-analysis on the diagnosis of scabies. Cureus. 2023; 15(1):e34390. [DOI:10.7759/cureus.34390]

[16] Fustà-Novell X, Morgado-Carrasco D, Alejo B, Riera-Monroig J, Puig S. Diagnosis and treatment response monitoring of scabies with reflectance confocal microscopy: A diagnostic pearl. Indian J Dermatol Venereol Leprol. 2020; 86(1):101-3. [DOI:10.4103/ijdvl.IJDVL_482_18] [PMID]

[17] Keser Şahin HH. Examination of histopathological findings in scabies cases: A retrospective analysis of five years of experience. Eur Rev Med Pharmacol Sci. 2023; 27(21):10240-6. [DOI:10.26355/eurrev_202311_34299] [PMID]

[18] Al-Musawi ND, Al-Bayati NY, Al-Kadhemi MH. Histological changes resulting from parasitic infestation (scabies). Diyala J Pure Sci. 2018; 14(2):250–61. [Link]

[19] Arlian LG, Feldmeier H, Morgan MS. The potential for a blood test for scabies. PLoS Negl Trop Dis. 2015; 9(10):e000418 [DOI:10.1371/journal.pntd.0004188] [PMID]

[20] Abd El-Aal AA, Hassan MA, Gawdat HI, Ali MA, Barakat M. Immunomodulatory impression of anti and pro-inflammatory cytokines in relation to humoral immunity in human scabies. Int J Immunopathol Pharmacol. 2016; 29(2):188-94. [DOI:10.1177/0394632015627464] [PMID]

[21] Jawad AT, Hadi NA. Role of interleukin-4 and IgE antibody in scabies infected patients of Thi-Qar province. Int J Health Sci (Qassim). 2022; 6(S5):10973-6. [DOI:10.53730/ijhs.v6nS5.11361]

[22] Nguyen HTG, Le HLH, Nguyen HV, Le HM, Vu HL, Inaoka PT, et al. Exploring blood cell count-derived ratios as practical diagnostic tools for scabies in vulnerable populations. J Pers Med. 2024; 14(4):373. [DOI:10.3390/jpm14040373] [PMID]

[23] Angelone-Alasaad S, Min AM, Pasquetti M, Alagaili AN, D'Amelio S, Berrilli F, et al. Erratum: Universal conventional and real-time PCR diagnosis tools for Sarcoptes scabiei. Parasit Vectors. 2015; 8:622. [DOI:10.1186/s13071-015-1238-y] [PMID]

[24] Wong SS, Poon RW, Chau S, Wong SC, To KK, Cheng VC, et al. Development of conventional and real-time quantitative PCR assays for diagnosis and monitoring of scabies. J Clin Microbiol. 2015; 53(7):2095-102. [DOI:10.1128/JCM.00073-15] [PMID]

[25] Avendaño C, Patarroyo MA. Loop-mediated isothermal amplification as point-of-care diagnosis for neglected parasitic infections. Int J Mol Sci. 2020; 21(21):7981. [DOI:10.3390/ijms21217981] [PMID]

[26] Augustine R, Hasan A, Das S, Ahmed R, Mori Y, Notomi T, et al. Loop-mediated isothermal amplification (lamp): a rapid, sensitive, specific, and cost-effective point-of-care test for coronaviruses in the context of COVID-19 pandemic. Biology (Basel). 2020; 9(8):182. [DOI:10.3390/biology9080182] [PMID]

[27] Fraser TA, Carver S, Martin AM, Mounsey K, Polkinghorne A, Jelocnik M. A Sarcoptes scabiei specific isothermal amplification assay for detection of this important ectoparasite of wombats and other animals. PeerJ. 2018; 6:e5291. [DOI:10.7717/peerj.5291] [PMID]

[28] Del Barrio-Díaz P, Vera-Kellet C. The burrow ink test: A simple method to improve the diagnosis of scabies. J Gen Intern Med. 2022. [DOI:10.1007/s11606-020-06522-6]

[29] Balak DMW, Rauwerdink D. Diagnosing scabies in a patient with skin of colour using the burrow ink test. Clin Exp Dermatol. 2024; 49(12):1758-9. [DOI:10.1093/ced/llae358] [PMID]

[30] Abraham M, Kizito Mirembe S, Mulyowa Kitunzi G, Onguti AG, Awino E. Role of scabies detection methods in diagnosis of scabies in patients attending Mbarara regional referral hospital skin clinic in western Uganda. Int J Innov Sci Res Technol. 2025; 10(3):2458-67. [DOI:10.38124/ijisrt/25mar1103]

[31] Marcuse EK. The burrow ink test for scabies. Pediatrics. 1982; 69(4):457. [DOI:10.1542/peds.69.4.457]

[32] Leung V, Miller M. Detection of Scabies: A systematic review of diagnostic methods. Can J Infect Dis Med Microbiol. 2011; 22(4):143-6. [DOI:10.1155/2011/698494] [PMID]

[33] Li FZ, Chen S. Diagnostic accuracy of dermoscopy for scabies. Korean J Parasitol. 2020; 58(6):669-74. [DOI:10.3347/kjp.2020.58.6.669] [PMID]

[34] Park JH, Kim CW, Kim SS. The diagnostic accuracy of dermoscopy for scabies. Ann Dermatol. 2012; 24(2):194-9. [DOI:10.5021/ad.2012.24.2.194] [PMID]

[35] Ueda T, Katsura Y, Sasaki A, Minagawa D, Amoh Y, Shirai K. Gray-edged line sign of scabies burrow. J Dermatol. 2021; 48(2):190-8. [DOI:10.1111/1346-8138.15650] [PMID]

[36] Scanni G. The Mite-Gallery Unit: A new concept for describing scabies through entodermoscopy. Trop Med Infect Dis. 2019; 4(1):48. [DOI:10.3390/tropicalmed4010048] [PMID]

[37] Micali G, Lacarrubba F, Verzì AE, Chosidow O, Schwartz RA. Scabies: Advances in noninvasive diagnosis. PLoS Negl Trop Dis. 2016; 10(6):e0004691. [DOI:10.1371/journal.pntd.0004691] [PMID]

[38] Nie YL, Yi H, Xie XY, Fu GL, Zheng YQ. Dermoscopic features of children scabies. Front Med (Lausanne). 2023; 10:1097999. [DOI:10.3389/fmed.2023.1097999] [PMID]

[39] Yürekli A, Can İ, Oğuz M. Using ultraviolet light in diagnosing scabies: Scabies' Sign via Wood's Lamp. J Am Acad Dermatol. 2023; 89(5):e195-6. [DOI:10.1016/j.jaad.2023.07.006] [PMID]

[40] Meduri AR, Ciccarese G, Viola R, Sbarra G, Cazzato G, Romita P, et al. Role of ultraviolet dermoscopy in detecting scabies signs. Skin Res Technol. 2024; 30(10):e70080. [DOI:10.1111/srt.70080] [PMID]

[41] Bhat YJ, Ul Islam MS, Errichetti E. Ultraviolet-induced fluorescence dermoscopy, a novel diagnostic technique in dermatological practice: A systematic review. Indian Dermatol Online J. 2024; 16(1):25-39. [DOI:10.4103/idoj.idoj_299_24] [PMID]

[42] Errichetti E, Plozner N, Enechukwu NA, Bhat YJ, Pietkiewicz P, Salwowska N, et al. Dermoscopy of scabies: utility of polarised and ultraviolet-induced fluorescence examination in fair and dark skin. Australas J Dermatol. 2025; 66(2):69-74. [DOI:10.1111/ajd.14406] [PMID]

[43] Arbache S, Hirata SH. Comment on "Using ultraviolet light in diagnosing scabies: Scabies' sign via Wood's lam. J Am Acad Dermatol. 2024; 91(3):e83. [DOI:10.1016/j.jaad.2024.03.055] [PMID]

[44] Yürekli A. A new sign with UV dermoscope in the diagnosis of scabies: Ball sign. Skin Res Technol. 2023; 29(5):e13336. [DOI:10.1111/srt.13336] [PMID]

[45] Sunderkötter C, Wohlrab J, Hamm H. Scabies: Epidemiology, diagnosis, and treatment. Dtsch Arztebl Int. 2021; 118(41):695-704. [DOI:10.3238/arztebl.m2021.0296] [PMID]

[46] Lacarrubba F, Micali G. Videodermatoscopy and scabies. J Pediatr. 2013; 163(4):1227-1227.e1. [DOI:10.1016/j.jpeds.2013.04.019] [PMID]

[47] Micali G, Lacarrubba F, Verzi AE, Nasca MR. Low-cost equipment for diagnosis and management of endemic scabies outbreaks in underserved populations. Clin Infect Dis. 2015; 60(2):327-9. [DOI:10.1093/cid/ciu826] [PMID]

[48] Lupu M, Voiculescu VM, Vajaitu C, Orzan OA. In vivo reflectance confocal microscopy for the diagnosis of scabies. BMJ Case Rep. 2021; 14(1):e240507. [DOI:10.1136/bcr-2020-240507] [PMID]

[49] Guan Z, Bi T, Li Q. Dermoscopic and reflectance confocal microscopic features of children scabies. Skin Res Technol. 2023; 29(9):e13459. [DOI:10.1111/srt.13459] [PMID]

[50] Morgado-Carrasco D, Fustà-Novell X, Rizo D, Alsina M. Slowly spreading scabies with a diagnosis confirmed by confocal reflectance microscopy: New technologies for diagnosis. Actas Dermosifiliogr. 2021; 112(3):271-3. [DOI:10.1016/j.adengl.2021.01.005]

[51] Banzhaf CA, Themstrup L, Ring HC, Welzel J, Mogensen M, Jemec GB. In vivo imaging of Sarcoptes scabiei infestation using optical coherence tomography. Case Rep Dermatol. 2013; 5(2):156-62. [DOI:10.1159/000352066] [PMID]

[52] Idoudi S, Battistella M, El Zeinaty P, Tavernier C, Lebbe C, Baroudjian B. Line-field confocal optical coherence tomography in vivo description of Sarcoptes scabiei and histological correlation. J Eur Acad Dermatol Venereol. 2024; 38(10):e874-6. [DOI:10.1111/jdv.19972] [PMID]

[53] Ruini C, Schuh S, Pellacani G, French L, Welzel J, Sattler E. In vivo imaging of Sarcoptes scabiei infestation using line-field confocal optical coherence tomography. J Eur Acad Dermatol Venereol. 2020; 34(12):e808-9. [DOI:10.1111/jdv.16671] [PMID]

[54] Walter B, Heukelbach J, Fengler G, Worth C, Hengge U, Feldmeier H. Comparison of dermoscopy, skin scraping, and the adhesive tape test for the diagnosis of scabies in a resource-poor setting. Arch Dermatol. 2011; 147(4):468-73. [DOI:10.1001/archdermatol.2011.51] [PMID]

[55] Cheng TA, Mzahim B, Koenig KL, Alsugair A, Al-Wabel A, Almutairi BS, et al. Scabies: Application of the novel identify-isolate-inform tool for detection and management. West J Emerg Med. 2020; 21(2):191-8. [DOI:10.5811/westjem.2020.1.46120] [PMID]

[56] Bae M, Kim JY, Jung J, Cha HH, Jeon NY, Lee HJ, et al. Diagnostic value of the molecular detection of sarcoptes scabiei from a skin scraping in patients with suspected scabies. PLoS Negl Trop Dis. 2020; 14(4):e0008229. [DOI:10.1371/journal.pntd.0008229] [PMID]

[57] Nasution AA, Putra IB, Sari MI. Identification of Sarcoptes scabiei by Clinical Examination and Follow-up Examination in Medan City, Indonesia. Open Access Maced J Med Sci. 2021; 9(B):1633-6. [DOI:10.3889/oamjms.2021.7692]

[58] Yulfi H, Zulkhair M, Yosi A. Scabies infection among boarding school students in Medan, Indonesia: Epidemiology, Risk Factors, and Recommended Prevention. Trop Parasitol. 2022; 12(1):34-40. [DOI:10.4103/tp.tp_57_21] [PMID]

[59] Uzun S, Durdu M, Yürekli A, Mülayim MK, Akyol M, Velipaşaoğlu S, et al. Clinical practice guidelines for the diagnosis and treatment of scabies. Int J Dermatol. 2024; 63(12):1642-56. [DOI:10.1111/ijd.17327] [PMID]

[60] Marksid M, McVernon J, McCarthy JS, Enbiale W, Hanna C, Chosidow O, et al. Diagnostics to support the control of scabies- Development of two target product profiles. PLoS Negl Trop Dis. 2022; 16(8):e0010556. [DOI:10.1371/journal.pntd.0010556] [PMID]

[61] Özdemir Y, Özdemir N, Topal İO. Clinical diagnosis and dermatological clues in scabies. Eur Arch Med Res. 2024; 40(1):1-6. [DOI:10.4274/eamr.galenos.2024.75547]

[62] García-Bernalt Diego J, Fernández-Soto P, Muro A. Lamp in neglected tropical diseases: A focus on parasites. Diagnostics. 2021; 11(3):521. [DOI:10.3390/diagnostics11030521] [PMID]

[63] Lugović-Mihić L, Aždajić MD, Bešlić I. Scabies cases misdiagnosed and treated as allergic diseases: itch as alarm. Acta Clin Croat. 2022; 61(2):349-53. [DOI:10.20471/acc.2022.61.02.22] [PMID]

[64] Widaty S, Kekalih A, Friska A. Empowering nonmedical personnel to detect scabies in endemic area using DeSkab instrument: A diagnostic study. J Gen Proced Dermatol Venereol Indones. 2024; 8(1):5-10. [DOI:10.7454/jdvi.v8i1.1170]

[65] Furnival-Adams J, López V, Mundaca H, Houana A, Macucha A, Elobolobo E, et al. Training of field-workers for rapid assessment of scabies prevalence: A diagnostic accuracy study in Mozambique. Am J Trop Med Hyg. 2024; 111(6):1320-5 [DOI:10.4269/ajtmh.24-0204] [PMID]

This Page Intentionally Left Blank