Archives of Razi Institute Journal
"Arch. Razi Inst."

Journal Homepage: https://archrazi.areeo.ac.ir/

Research Paper

Gastrointestinal Parasitic Infection of Ostriches From Breeding Farms in Tehran Province, Iran

Ahmadreza Mohammadi[1], Abdolhossein Dalimi[2*], Gholamreza Motamedi[3], Ali Motamedi[4]

1. Department of Poultry Vaccines Research and Production, Razi Vaccine and Serum Research Institute, Agriculture Research, Education and Extension Organization (AREEO), Karaj, Iran.
2. Department of Parasitology, Faculty of Medical Sciences, Tarbiat Modares University, Tehran, Iran.
3. Department of Parasitic Diseases, Razi Vaccine and Serum Research Institute, Agriculture Research, Education and Extension Organization (AREEO), Karaj, Iran,
4. Faculty of Veterinary Medicine, Karaj Ka.C., Islamic Azad University, Karaj, Iran.

Use your device to scan and read the article online

How to cite this article Mohammadi A, Dalimi A, Motamedi Gh, Motamedi A. Gastrointestinal Parasitic Infection of Ostriches From Breeding Farms in Tehran Province, Iran. Archives of Razi Institute Journal. 2026; 81(4):865-870. https://doi.org/10.32598/ARI.81.4.3555

https://doi.org/10.32598/ARI.81.4.3555

Article info:
Received: 21 Jan 2026
Accepted: 18 May 2026
Published: 01 Jul 2026

Keywords:
Gastrointestinal parasites, Libiostrongylus, Ostrich, Tehran

ABSTRACT

Introduction: Parasites are a significant health threat and an obstacle to the development of the ostrich farming industry. Therefore, identification of parasitic infections in breeding farms is essential.

Materials & Methods: This study examined 311 fecal samples from 10 farms in Tehran Province for parasitic infection using sedimentation and flotation methods.

Results: Results revealed that 33.44% of both adult and immature ostriches were infected with eight types of helminthic and protozoan parasites. *Eimeria* spp. was the only infection found in immature ostriches, while five helminthic and three protozoan genera were identified in adults. *Libyostrongylus douglassi* had the highest prevalence at 11.25%, and *Codiostomum struthionis* had the lowest at 0.64%.

Conclusion: Overall, the prevalence of these infections serves as a warning for this emerging industry. Insufficient breeder knowledge about parasitic diseases, inadequate health management, and a lack of preventive measures may worsen the infection risks.

*** Corresponding Author:**
Abdolhossein Dalimi, Professor.
Address: *Department of Parasitology and Entomology, Faculty of Medical Sciences, Tarbiat Modares University, Tehran, Iran.*
Tel: *+98 (21) 82883568*
E-mail: *dalimi_a@modares.ac.ir*

Copyright © 2026 The Author(s);
This work is licensed under a Creative Commons Attribution-NonCommercial 4.0 International license (https://creativecommons.org/licenses/by-nc/4.0/).
Noncommercial uses of the work are permitted, provided the original work is properly cited.

Introduction

The ostrich (*Struthio camelus*) is a bird native to Africa and a member of the ratite order. It is the world's largest bird, with correspondingly large eggs. Ostriches have long necks and legs, and can run at speeds of up to 70 km/h, making them the fastest bird on land, but they cannot fly [1]. Their diet primarily consists of plants, though they also consume invertebrates. Living in groups of 5 to 50, ostriches hide by lying flat on the ground when threatened or, if cornered, will defend themselves with powerful kicks. Some are domesticated for ornamental feathers, clothing, leather, and meat. Males have black feathers with white tips, while females are brown. Both sexes have featherless, bald heads and necks. Ostriches often coexist with herbivorous mammals like zebras, buffaloes, and wildebeests [1].

Ostriches are prone to various infectious diseases, including yolk sac infection, foot deformities, inflammatory bowel disease, Newcastle disease, smallpox, influenza, angina pectoris, necrotizing edema, coccidiosis, eye infections, mycoplasmosis, and fungal and parasitic diseases [2]. Parasitic diseases in ostriches are categorized into external and internal parasites. Key internal parasites include the worms *Libyostrongylus douglassi* (ostrich stomach worm), *Houttuynia struthionis* (pumpkin cestode), *Codiostomum struthionis*, *Phyllophtalmus grali*, and protozoa such as *Toxoplasma*, *Histomonas*, *Cryptosporidium*, and *Eimeria*. Both internal and external parasites can impact ostriches, often exacerbated by poor management, high bird density, and inadequate hygiene [3].

Reports of parasitic infections in ostriches have emerged globally, including studies in Botswana [4], Spain [5], and Nigeria [6]. In Iran, research has been sporadic and limited. Given the establishment of ostrich farming over the past decade and the centralized breeding methods in the country, further studies are warranted. Eslami et al. (2007) reported the prevalence of certain internal parasites in ostriches imported from Europe in 2002-2003 [7]. Subsequent studies were conducted in Mashhad [8], Fars Province [9], and Saveh in ostrich farms [10].

Ostrich breeding is increasingly recognized as a viable industry worldwide, but like other livestock, ostriches face threats from internal and external parasites, which can lead to significant economic losses. Thus, there is an urgent need for health research and development to support this industry. This study represents the first comprehensive assessment of both helminthic and protozoan parasite diversity and prevalence in ostrich breeding farms within Tehran Province, highlighting critical gaps in current health management practices and emphasizing the urgent need for targeted prevention strategies in Iran's growing ostrich farming sector.

Materials and Methods

This study was conducted in 2015 at the Razi Institute as a research project. The Agricultural Organization of Tehran Province reports that there are 48 active ostrich breeding and fattening farms in the area. Following clinical examinations, fecal samples were collected from 10 farms in Varamin, Malard, Pakdasht, Shahr-e-Rey, Kahrizak, Zarandieh, Shahriar, and Robat Karim. The farm selection and sampling method were random, and no clinical examination was performed on the ostriches. Sampling occurred three times at intervals of one to three months, and the samples were sent to the parasitology laboratory following standard protocols. They were analyzed using sedimentation and flotation tests, with parasites identified based on the morphological characteristics of worm eggs, trophozoites, cysts, and oocysts, with reference to reliable parasitology sources. The gathered data were then statistically analyzed.

Is the materials and methods section complete? How about statistical analysis

Results

Among 311 adult and immature ostriches examined in various regions of Tehran Province, 104(33.44%) were infected with eight types of helminthic and protozoan parasites. *Eimeria* spp. infection was found only in immature ostriches, while adult ostriches had five genera of worms and three genera of protozoa. *Libyostrongylus douglassii* showed the highest prevalence at 11.25%, while *C. struthionis* had the lowest at 0.64% (Table 1).

Images of worm eggs and trophozoites, cysts, and oocysts of protozoa identified in this study are shown in Figure 1.

Discussion

The ostrich farming industry in Iran, particularly in Tehran Province, is growing in areas such as meat, leather, and other by-products. The history of ostrich farming in Iran began in 1994 with the arrival of breeding flocks, fertilized eggs, and day-old chicks from South Africa, Zimbabwe, Canada, the Netherlands, Belgium, Turkey,

Table 1. Parasitic infection rates in 311 immature and adult ostriches from Tehran Province

Parasites	Genus	No. (%) Infected
Helminthes	*L. douglassii*	35(11.25)
	Capillaria spp.	5(1.6)
	Ascaridia spp.	5(1.6)
	C. struthionis	2(0.64)
	Trematode egg	11(3.53)
Protozoan	*Eimeria* spp. oocysts	17(5.46)
	Entamoeba spp. trophozites	23(7.39)
	Iodamoeba spp. cysts	6(1.92)
Total		104(33.44)

and Spain. Today, five combined ostrich farming units (meat and breeding) with a capacity of 7,870 birds (in the cities of Pishva, Shahriar, Rey, and Varamin) and six fattening ostrich farming units with a capacity of 910 birds (in the cities of Mallard, Varamin, Qarchak, and Robat Karim) are operating in Tehran Province. In the present study, 311 (48 immature and 263 adult) ostriches from 10 breeding ostrich farming units were sampled to investigate parasitic infection. All these farms are managed with an outdoor system. However, parasitic infections pose a significant threat to this emerging sector. The outdoor farming methods, inadequate hygiene, and the lack of preventive measures against parasitic diseases on some farms increase the risk of infection. Additionally, the prevalence of parasitic infections in older ostriches and their relatively advanced age may contribute to the persistence of these infections. Addressing parasitic infections is essential due to their negative effect on overall efficiency. In total, 311 samples from 10 farms in Tehran Province showed a 33.44% infection rate in chicks and adult ostriches. This aligns with Eslami et al. (2007) findings of a 25-55% nematode infection preva-

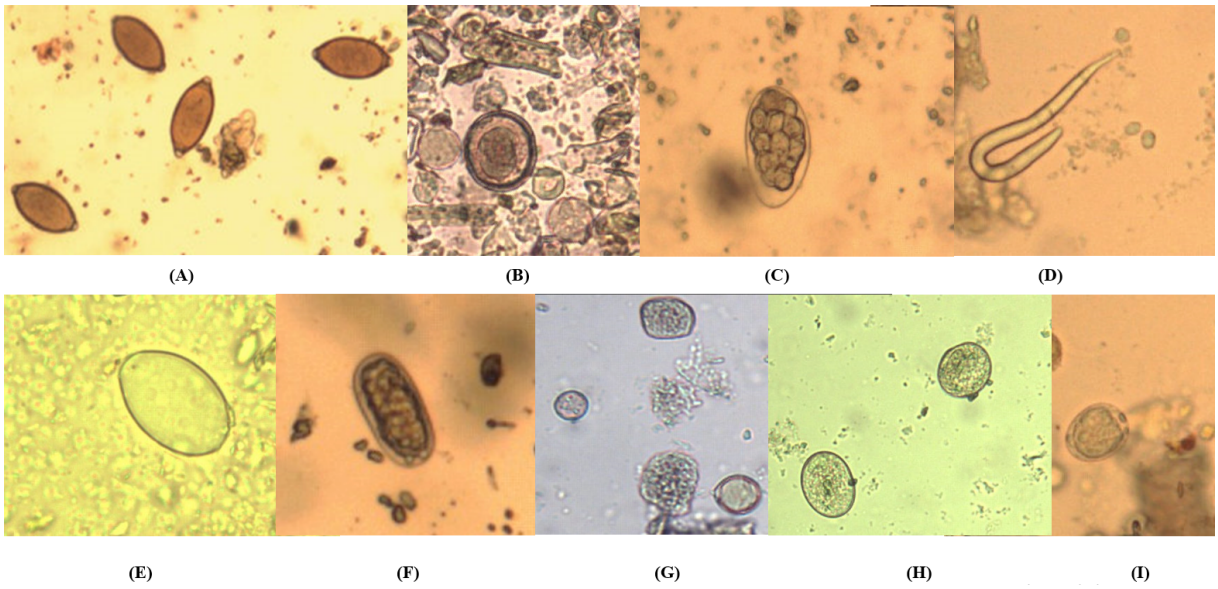

Figure 1. Images of worm eggs and trophozoites, cysts, and oocysts of protozoa identified in this study, including: (A) Capillaria eggs; (B) *Ascaridia* egg; (C) *Libyostrongylus* egg; (D) Nematode larvae; (E) Trematode egg; (F) *Codiostomum* egg; (G) *Entamoeba* trophozoites; (H) *Eimeria* oocysts; (I) *Iodamoeba* cyst

lence in imported flocks [7]. While Masoudi Rad et al. (2008) reported no infections in Mashhad [8], Behzadi et al. (2009) found a 28% *Cryptosporidium* infection rate in Fars Province [9]. Additionally, Nabatiyan Javan et al. (2012) identified parasitic infections in ostrich farms near Saveh, with 23% of samples testing positive for Eimeria oocysts [10].

In the present study, ostriches were infected with eight types of helminthic and protozoan parasites. In immature ostriches, only Eimeria infection was detected. However, in adult ostriches, five genera of worms and three genera of protozoa were detected. Among them, the highest rate of infection was caused by *L. douglassii* (11.25%).

L. douglassii is a gastrointestinal parasite belonging to the family Trichostrongylidae [11]. The parasite consists of very small, round, reddish-yellow worms about 3 mm long, with males measuring 4-6 mm long and females measuring 5-6 mm long [11]. Due to their small size, they are not visible to the naked eye. Infection with this parasite causes libyostrongylosis, where the fully mature worm impairs the secretion of gastric glands. The stomach lining becomes infected and swollen, and a thick, protective mucous layer surrounds the parasite, preventing the gastric juice needed for preliminary digestion of food from reaching the interior of the proventriculus, resulting in spoilage of its contents. Signs of the disease are similar to those of constipation, such as lethargy (paralysis), loss of appetite (apathy), hard and pellet-like feces, and dull feathers. The urine is thick, and the bird has foul-smelling breath. Young ostrich chicks are particularly susceptible to this parasite [12]. However, in the present study, it was not found in immature ostriches. Ostrich chicks grow poorly if infected, are anemic, and mortality can be high. Severe infection can cause proventricular occlusion and may result in high mortality [12]. Mortality in young ostriches less than 8 months of age may be as high as 80%. Severe infection may kill chicks within a few days. The adult worms and late larval stages live in the crypts of the glandular portion of the proventriculus wall and gizzard [1]. In adult ostriches, the infection typically leads to gastrointestinal issues such as diarrhea, weight loss, poor feed conversion, and reduced growth rates. In more severe cases, heavily infected birds can experience anemia, dehydration, weakness, and even increased mortality if left untreated. Chronic infections can impair overall health and productivity, making parasite control crucial in ostrich farming operations. Each bird can shed up to 3 million parasite eggs per day [13]. The parasite eggs are extremely resistant and can survive outside the host for up to 3 years. The parasite may be spread by infective larvae in pastures, by droppings containing parasite eggs, or on shoes or vehicle tires [13]. Diagnosis is based on the detection of *Libiostrongylus* in the proventriculus or the detection of Trichostrongylus eggs in the host's feces [1]. It is the most economically important gastrointestinal parasite of ostriches, causing serious losses. *Libiostrongylus* has been reported in ostriches in various regions of Africa, North America, and Europe [11]. This parasite has been reported in Spain [5], Scotland [14], Italy [15], and Nigeria [6]. It has been reported at a rate of 25-55% in ostriches imported from Europe to a farm in northern Iran [7]. In the present study, 13.30% of adult ostriches were infected with this parasite, but no infection was observed in immature ostriches.

Ascaridia and *Capillaria* can infect all birds, including ostriches. Since most of these parasites have multiple hosts, it is almost impossible to eradicate them if the flock is infected. The parasites have been reported in 2% of Nigerian ostriches [6]. In the present study, 1.90% of adult ostriches were infected with these two parasites, but no infection with these parasites was observed in immature ostriches.

C. struthionis is reported for the first time in ostriches reared in Iran. *C. struthionis* is a parasitic nematode of the Strongylidae family and is specific to ostriches [12]. It is relatively large (about 1-1.5 cm long) and white in color [11]. It is usually found in the large intestine and cecum of ostriches, feeds on mucus and disrupts water absorption [16]. This parasite is prevalent in African ostriches [11]. This parasite has also been reported in ostriches in Italy [15]. In the present study, 0.76% of adult ostriches were infected with this parasite, but no infection with this parasite was observed in immature ostriches.

Eimeria spp. are common and dangerous coccidian protozoan of poultry. Different species of *Eimeria* cause loss of appetite, weakness, ruffled feathers, and bloody feces. Symptoms are usually mild in ostriches and the severity of the infection can only be accurately diagnosed by postmortem examination [12]. If diarrhea is observed, even if mild, coccidial agents should be considered. In young birds, especially those kept in wet litter or open environments, coccidiosis can cause extensive damage. It has been reported in 3% of ostriches in Nigeria [6] and in 34% of apparently healthy ostrich chicks in Botswana [4]. Young chicks were most frequently infected, while ostriches older than 9 weeks of age did not have oocysts in their feces. Since these chicks develop normally, without any signs of diarrhea, these coccidia appear to be non-pathogenic [3]. This parasite was reported in a four-year study of 500 ostriches in Spain [5]. *Eimeria* species

were also reported in Argentine ostriches [3], in ostriches in Italy [15] and Iraq [17]. In the present study, 32.5% of adult ostriches and 25.6% of immature ostriches were infected with this parasite.

Amoebae include parasitic and commensal species from all vertebrate classes and some invertebrates. They have a direct life cycle, usually with cysts serving as the stage of transmission from one host to another [18]. Only two species of *Entamoeba* have been described in birds: *E. gallinarum,* from the *E. coli* group, in chickens, turkeys, seagulls, ducks and geese, and *E. anatis*, from the *E. histolytica* group, in ducks [18]. No *Entamoeba* species has been reported in ostriches, although there have been several observations of the presence of amoebas in this bird. These include reports from Spain [19], Greece [20], and England [14]. Some researchers believe that more than 80% of the samples contain cysts (and sometimes trophozoites) similar to amoebae belonging to the *E. bovis* group [19]. In the present study, 74.8% and 28.2% of adult ostriches were infected with *Entamoeba* and Iodamoeba-like cysts, respectively. However, the precise identification of the genus and species of these parasites requires molecular studies, which can be considered a recommendation for future studies.

In conclusion, the prevalence of parasitic infections can be a warning sign for this nascent industry. The breeders' lack of sufficient knowledge about parasitic diseases, poor health management, and the lack of preventive medication can exacerbate the risk of these infections.

The study emphasizes the importance of targeted parasite control strategies considering the age-related susceptibility and parasite diversity. The higher prevalence of *L. douglassi* suggests a need to focus on controlling this specific nematode through appropriate anthelmintic usage and pasture management. The absence of helminth infections in immature ostriches, coupled with the sole presence of *Eimeria* spp., points to the importance of coccidiosis control in young birds. Implementing strict biosecurity measures, regular fecal examinations, and strategic deworming programs is crucial.

Furthermore, educating ostrich farmers on parasite life cycles, transmission routes, and best management practices for parasite prevention is vital for sustainable ostrich farming in Tehran Province and potentially other similar regions. A comprehensive approach combining improved farm management with strategic parasite control will contribute to enhanced ostrich health, reduced economic losses, and overall growth of the industry. Further research should investigate the specific risk factors associated with *L. douglassi* infection, such as pasture conditions, stocking densities, and deworming practices employed on different farms. Evaluating the efficacy of commonly used anthelmintics against *L. douglassi* and other prevalent parasites in Iranian ostriches is also critical, given the potential for anthelmintic resistance. Moreover, exploring alternative parasite control methods, such as the use of biological control agents or herbal remedies, could offer a more sustainable and environmentally friendly approach to parasite management in ostrich farming.

The economic impact of parasitic infections on ostrich production in Tehran Province warrants further investigation. Quantifying the losses associated with reduced growth rates, decreased egg production, and increased mortality rates due to parasitic infections can provide a strong economic justification for implementing proactive parasite control programs. This data can also be used to advocate for increased investment in research, extension services, and farmer education related to ostrich health management.

Finally, longitudinal studies are needed to monitor the prevalence and diversity of parasitic infections in ostriches over time and to assess the effectiveness of different control strategies. Such studies should also consider the impact of environmental factors, such as temperature and rainfall, on parasite transmission and survival. By gaining a deeper understanding of the epidemiology of parasitic infections in ostriches, more effective and sustainable strategies van be developed to protect the health and productivity of these valuable birds. These efforts will ultimately contribute to the long-term viability and success of the ostrich farming industry in Tehran Province and beyond.

Acknowledgements

The authors would like to thank the staff of the Department of Parasitology of the Razi Vaccine and Serum Research Institute, as well as the Department of Parasitology of Faculty of Medical Sciences, Tarbiat Modares University, for their assistance.

Compliance with ethical guidelines

There were no ethical considerations to be considered in this research.

Funding

This study was financially supported by the Agriculture Research, Education and Extension Organization (AREEO), Karaj, Iran (Project No.: 2-41-18-89028).

Authors' contributions

Conceptualization and study design: Ahmadreza Mohammadi and Gholamreza Motamedi. Data collection: Ahmadreza Mohammadi, Abdolhossein Dalimi, and Gholamreza Motamedi. Writing the original draft: Abdolhossein Dalimi and Gholamreza Motamedi. Statistical analysis, formal analysis, data interpretation, review and editing: Abdolhossein Dalimi; Administrative, technical, and material support: Ahmadreza Mohammadi, Abdolhossein Dalimi, Gholamreza Motamedi, and Ali Motamedi.

Conflict of interest

The authors declared no conflict of interest.

Data availability

All data generated during this study are included in this article.

References

[1] Deeming DC. The Ostrich - Biology, Production and Health. London: CABI Publishing; 1999. [DOI:10.1079/9780851993508.0000]

[2] Cooper RG. Bacterial, Fungal and Parasitic Infections in the Ostrich (Struthio camelus var. domesticus). Anim Sci J. 2005; 76(2):97-106. [DOI:10.1111/j.1740-0929.2005.00243.x]

[3] Chang Reissig E, Olaechea F, Robles CA. Parasitological Findings of Lesser Rhea, Pterocnemia Pennata in Faeces from Northern Patagonia, Argentina. Arch Med Vet. 2001; 33(2):247-51. [DOI:10.4067/S0301-732X2001000200014]

[4] Mushi EZ, Binta MG, Chabo RG, Toto PA. A note on endoparasites of wild ostriches (Struthio camelus) in the Mokolodi Nature Reserve, Gaborone, Botswana. J S Afr Vet Assoc. 2003; 74(1):22-3. [DOI:10.4102/jsava.v74i1.494] [PMID]

[5] Ponce Gordo F, Martínez Díaz RA, Herrera S. Entamoeba struthionis n.sp. (Sarcomastigophora: Endamoebidae) from ostriches (Struthio camelus). Vet Parasitol. 2004; 119(4):327-35. [DOI:10.1016/j.vetpar.2003.10.022] [PMID]

[6] Ibrahim UI, Mbaya AW, Geidam YA, Geidam AM. Endoparasites and associated worm burden of captive and free-living ostriches (Struthio camelus) in the semi-arid region of northeastern Nigeria. Inter J Poultry Sci. 2006; 5(12):1128-32. [DOI:10.3923/ijps.2006.1128.1132]

[7] Eslami A, Rahmat H, Meshgi B, Ranjbar-Bahadori S. Gastrointestinal Parasites of Ostrich (Struthio camelus domesticus) Raised in Iran. Iran J Vet Res. 2007; 8(1):80-2. [DOI:10.22099/ijvr.2007.2712]

[8] Masoudi Rad R, Pakzadeh Shahabi M, Barji H, Razmi Gh. [Investigating Parasitic Contamination of the Digestive System of Ostriches in Breeding Flocks Around the City of Mashhad (Persian)]. Paper presented at: 15th Iranian Veterinary Congress. 26 Aprl 2008,Tehran, Iran. [Link]

[9] Behzadi MA, Razavi SM, Yazdanpoor H, Mirzaei A, Tamadon A, Javdani Gandomani M. Epidemiology of Cryptosporidium infection in ostriches (Struthio camelus) in Iran. Bulg J Vet Med. 2009; 12(1):55−61. [Link]

[10] Nabatiyan Javan R. [The parasitic infections in ostriches at farms around Saveh, Iran (Persian)] [DVM thesis]. Garmsar: Islamic Azad University, Garmsar Branch; 2012. [Link]

[11] Taylor MA, Coop RL, Wall RL. Veterinary Parasitology. Oxford: Blackwell Publishing; 2007. [Link]

[12] Shanawany MM, Dingle J. Ostrich Production Systems. Rome: FAO; 1999. [Link]

[13] Mukaratirwa S, Cindzi ZM, Maononga DB. Prevalence of Libyostrongylus douglassii in commercially reared ostriches in the highveld region of Zimbabwe. J Helminthol. 2004; 78(4):333-6. [DOI:10.1079/JOH2004246]

[14] Pennycott TW, Patterson T. Gastrointestinal parasites in ostriches (Struthio camelus). Vet Rec. 2001; 148(5):155-6. [PMID]

[15] Porcu F, Pintori A, Varcasia A, Gaglio G, Scala A. An epidemiological investigation on parasites in ostriches (Struthio camelus reared in Sardinia. Riv Avic. 2003; 72(2):43-7. [Link]

[16] Ederli NB, de Oliveira FC, Rodrigues Mde L. Further study of Codiostomum struthionis (Horst, 1885) Railliet and Henry, 1911 (Nematoda, Strongylidae) parasite of ostriches (Struthio camelus Linnaeus, 1758) (Aves, Struthioniformes). Vet Parasitol. 2008; 157(3-4):275-83. [DOI:10.1016/j.vetpar.2008.07.018] [PMID]

[17] Makawi ZA, Jasim SY. Isolation and identification of intestinal protozoa from ostriches in middle of Iraq. Plant Arch. 2020; 20(Supplement 2):1135-9. [Link]

[18] Levine ND. Veterinary Protozoology. Ames: Iowa State University Press; 1985. [Link]

[19] Martínez-Díaz RA, Herrera S, Castro A, Ponce F. Entamoeba sp. (Sarcomastigophora: Endamoebidae) from ostriches (Struthio camelus) (Aves: Struthionidae). Vet Parasitol. 2000; 92(3):173-9. [DOI:10.1016/S0304-4017(00)00314-9] [PMID]

[20] Symeonidou I, Diakou A, Papadopoulos E, Ponce-Gordo F. Endoparasitism of Greek ostriches: First report of Entamoeba struthionis and Balantioides coli. Vet Parasitol Reg Stud Reports. 2019; 18:100334. [DOI:10.1016/j.vprsr.2019.100334] [PMID]