Archives of Razi Institute Journal
"Arch. Razi Inst."

Journal Homepage: https://archrazi.areeo.ac.ir/

Research Paper

Application of Cryotherapy in the Treatment of Cutaneous Leishmaniasis in BALB/c Mice Compared With Commercial Injectable Treatments

Sayed Kamyab Sajadi[1], Ghazaaleh Adhami[1], Yahya Maroufi[2*]

1. Department of Veterinary Pathobiology, Sa.C., Islamic Azad University, Sanandaj, Iran.
2. Department of Parasitology and Mycology, Faculty of Medicine, Kurdistan University of Medical Sciences, Sanandaj, Iran.

Use your device to scan and read the article online

How to cite this article Sajadi SK, Adhami Gh, Maroufi Y. Application of Cryotherapy in the Treatment of Cutaneous Leishmaniasis in BALB/c Mice Compared With Commercial Injectable Treatments. Archives of Razi Institute Journal. 2026; 81(3):599-604. https://doi.org/10.32598/ARI.81.3.3494

https://doi.org/10.66224/ARI.81.3.3494

Article info:
Received: 01 Feb 2026
Accepted: 22 Mar 2026
Published: 01 May 2026

Keywords:
Amphotericin B, Cryotherapy, Cutaneous leishmaniasis (CL), Glucantime, *Leishmania major*

ABSTRACT

Introduction: Cutaneous leishmaniasis (CL), caused by *Leishmania* species, is a parasitic disease prevalent in tropical and subtropical regions. Currently, pentavalent antimonial compounds such as pentostam (sodium stibogluconate) and glucantime (meglumine antimoniate) are considered first-line treatments for CL.

Materials & Methods: In this study, the efficacy of cryotherapy administered alone and in combination with commercial drugs for treating CL, compared with monotherapy using commercial treatments (glucantime and amphotericin B), in BALB/c mice was investigated. Following lesion development, glucantime was administered daily via direct intralesional injection, while amphotericin B was administered intraperitoneally as a single daily dose for three weeks. Cryotherapy was performed six times over a maximum period of three weeks.

Results: The results demonstrated a significant reduction in lesion size and accelerated wound healing in groups treated with cryotherapy combined with glucantime or amphotericin B compared with the control group. In the cryotherapy-glucantime group, complete wound closure was achieved by the third week, with no residual nodules or lesion expansion, as observed in the untreated control group. Notably, at the end of the treatment period, no parasites were detected in the spleens of any treatment group.

Conclusion: This study supports cryotherapy as an effective adjunctive strategy for enhancing the efficacy of conventional drugs in cutaneous leishmaniasis.

*** Corresponding Author:**
Yahya Maroufi, Associate Professor.
Address: *Department of Parasitology and Mycology, Faculty of Medicine, Kurdistan University of Medical Sciences, Sanandaj, Iran.*
Tel: *+98 (918) 3755825*
E-mail: *maroofi.y@gmail.com*

Copyright © 2026 The Author(s);
This work is licensed under a Creative Commons Attribution-NonCommercial 4.0 International license (https://creativecommons.org/licenses/by-nc/4.0/).
Noncommercial uses of the work are permitted, provided the original work is properly cited.

1. Introduction

Leishmaniasis represents a significant parasitic disease affecting various tropical and subtropical regions worldwide, including Iran. The World Health Organization (WHO) estimates that 350 million people are at risk of infection, with approximately 12 million people currently infected and an additional 1.5 million new cases occurring annually [1]. Over time, several treatment modalities have been employed for cutaneous leishmaniasis (CL), including localized radiation therapy, lesion cauterization, cryotherapy, and local drug injections [2-4]. Currently, pentavalent antimonial compounds such as pentostam (sodium stibogluconate) and glucantime (meglumine antimoniate) are considered first-line therapies for CL treatment [5]. However, the use of these compounds presents several limitations, including prolonged treatment duration, high drug costs, treatment failure in approximately 10-15% of cases, and severe toxicity affecting the heart, liver, and kidneys [6]. Consequently, extensive research continues in the development of alternative treatment strategies for leishmaniasis.

Various therapeutic approaches have been employed, typically based on host and parasitic factors, although current treatment data remain variable and often provide limited guidance for specific protocols. Given the thermosensitivity of *Leishmania* [7], cryotherapy has emerged as a viable therapeutic option, demonstrating high efficacy, particularly in CL cases caused by *Leishmania tropica*, *Leishmania aethiopica*, *Leishmania infantum*, and *Leishmania braziliensis* [8, 9]. By destroying amastigotes and triggering the host's immune response through antigenic release, cryotherapy promotes cryonecrosis [10]. Meta-analyses have demonstrated that cryotherapy exhibits similar efficacy to sodium stibogluconate for smaller lesions while producing fewer adverse effects [11]. However, this method is limited to lesions under 4 cm in diameter and fewer than four lesions per patient. Combination therapy utilizing cryotherapy and sodium stibogluconate appears to yield superior outcomes, with evidence supporting synergistic effects [8, 11, 12].

The increasing incidence of therapeutic failure, recurrence, and drug resistance in *Leishmania* species indicates an urgent need to reassess current treatment protocols. Combination therapies utilizing synergistically active compounds could reduce treatment duration, dosage requirements, adverse effects, and costs while potentially mitigating the development of drug resistance [13]. Combination therapy incorporating antimonials and cryotherapy has demonstrated statistically significant improvement rates compared to monotherapy with either treatment modality for *L. tropica* or *L. major* infections across various geographic regions [9, 14, 15].

The objective of this study was to evaluate the efficacy of cryotherapy administered alone or in combination with commercial drugs for treating CL caused by *L. major* in BALB/c mice.

2. Materials and Methods

This experimental study was conducted in the Parasitology Laboratory of Kurdistan University of Medical Sciences and received approval from the Research Committees of Islamic Azad University, Sanandaj Branch.

2.1. Parasite

The *L. major* strain (MRHO/IR/75/ER) was obtained from the Education and Research Center for Skin Diseases and Leprosy of Tehran University of Medical Sciences. Parasites were cultured in RPMI 1640 medium supplemented with 10% fetal bovine serum (FBS) in culture flasks and incubated at 25 ˚C.

2.2. Animals

Thirty female BALB/c mice aged 6-8 weeks were randomly allocated into six groups: control (no treatment), cryotherapy alone, glucantime alone, amphotericin B alone, glucantime-cryotherapy combination, and amphotericin B-cryotherapy combination (n=5 per group).

2.3. Parasite inoculation

Stationary-phase parasites were utilized for inoculation. The culture medium containing stationary-phase parasites was centrifuged at 1500 rpm for 10 minutes, washed three times with sterile phosphate-buffered saline (PBS), and concentrated to 2×10^6 promastigotes/mL. Subcutaneous injections were administered at the tail base (0.2 mL). Lesions appearing after 3-5 weeks were recorded [16].

2.4. Drug administration

Following lesion development, glucantime (20 mg/kg) was administered daily via direct intralesional injection [17], while amphotericin B was administered intraperitoneally as a single daily dose (4 mg/kg/day) for three weeks [18]. For cryotherapy, a cotton swab saturated with liquid nitrogen was applied with gentle pressure to the lesion until the lesion and a 1-2 mm margin were blanched.

Treatment duration varied according to lesion size, thickness, and location (ranging from 10 to 30 seconds). For thicker lesions, the freeze-thaw cycle was repeated six times over a maximum period of three weeks [18]. Mouse weights were recorded before and after treatment. At the conclusion of the treatment period, two mice from each group were euthanized under sterile conditions, and their spleens were harvested. Spleen weights were recorded, after which samples were homogenized in 2 mL of RPMI medium containing 10% FBS. Seven serial 10-fold dilutions were prepared, and 200 µL of each dilution was added to 96-well plates in duplicate. Plates were sealed with parafilm and incubated at 26-28 ˚C for 7-15 days. Plates were examined periodically under an inverted microscope to detect promastigotes. Parasite load was calculated using the Equation 1 [19]:

1. *Parasite load* = $-\log_{10}$ *(dilution/spleen weight)*

2.5. Statistical analysis

Data were analyzed using SPSS software version 24. Descriptive statistics, including frequencies, percentages, Means±SD, are presented graphically where appropriate. Comparisons of quantitative data were performed using t-tests and Tukey's post hoc tests. Statistical significance was set at $P<0.05$ (95% confidence interval [CI]).

3. Results

3.1. Weight changes

Figure 1 displays the mean weights of mice before and after treatment. The mean weights in the glucantime treatment group (24.30 g) and the glucantime-cryotherapy group (24.88 g) exceeded their pre-treatment weights. This increase was more substantial than that observed in other treatment groups, indicating a beneficial effect on mouse health and recovery.

3.2. Lesion size

As demonstrated in Figure 2, treatment effectiveness was evaluated based on lesion size, induration, and location. Results revealed no significant differences in average lesion diameter among groups at baseline (day zero). During the first week, a decreasing trend in lesion diameter was observed across all treatment groups; however, these reductions were not statistically significant.

By the second week, a significant reduction in lesion diameter was observed in the cryotherapy group compared to the control group. Significant differences were also noted between the glucantime-only group and the glucantime-cryotherapy group compared to both the control and cryotherapy-only groups. For amphotericin B alone and amphotericin B combined with cryotherapy, lesion reduction was significant only when compared to the control group.

In the third week, lesions in treatment groups progressively resolved, leaving no residual nodules or lesions, whereas lesions in the control group continued to expand, ultimately resulting in animal mortality. Compared to the control group, wound healing in the cryotherapy group was significantly enhanced. Notably, the glucantime-only and glucantime-cryotherapy groups demonstrated significantly superior healing compared to both control

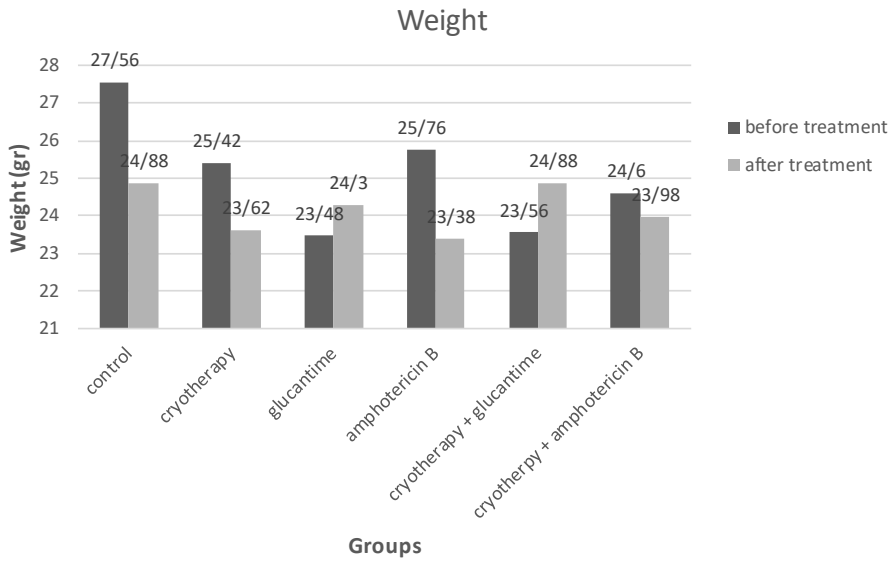

Figure 1. Mouse weights in different treatment groups during the study period

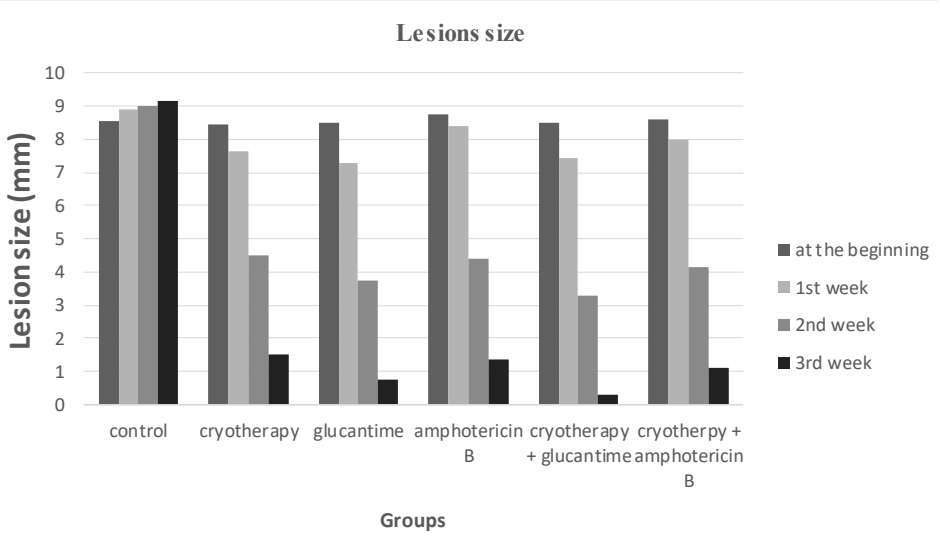

Figure 2. Average changes in lesion diameter (mm) among treatment groups during the study period

and cryotherapy-alone groups. Similarly, while amphotericin B alone or combined with cryotherapy resulted in decreased lesion size, this reduction was statistically significant only compared to the control group.

3.3. Parasite load in spleen

Study findings revealed a complete absence of parasites in the spleens of all treatment groups by study completion (Figure 3). A critical parameter in evaluating therapeutic system efficacy for treating and healing CL is the ability to prevent systemic spread and proliferation of *Leishmania* within the host. Examination of spleens from treated mice confirmed that none of the mice exhibited a detectable parasite burden.

4. Discussion

In the present study, mean weight in the glucantime-treated group (24.30 g) and the glucantime-cryotherapy-treated group (24.88 g) increased following treatment compared to baseline and other treatment groups. The

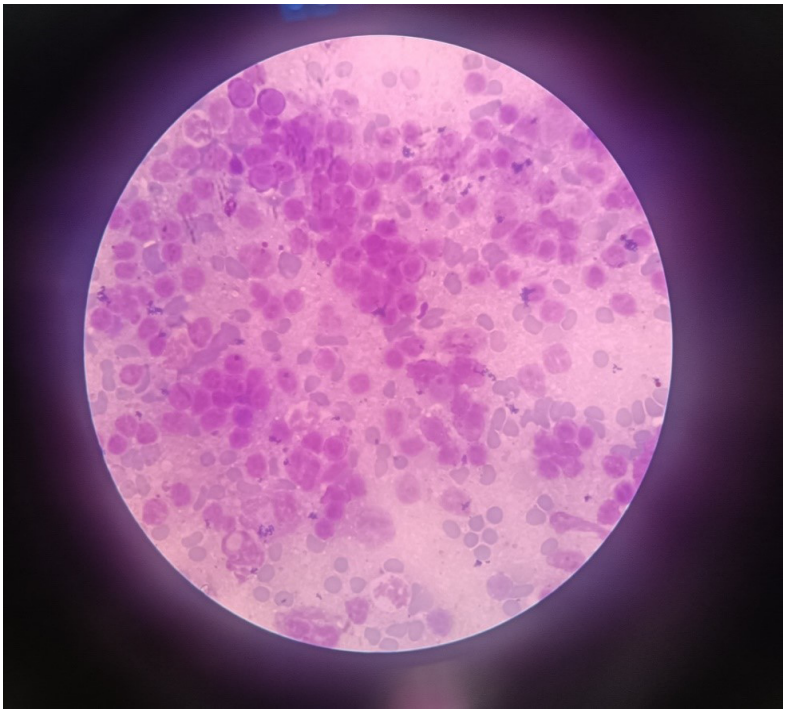

Figure 3. Microscopic examination of splenocytes using inverted microscopy demonstrating absence of amastigotes

weight gain was due to increased appetite in both groups post-treatment. No significant differences in mean lesion diameter were observed among groups at baseline or during the first week. By the second week, however, a statistically significant reduction in lesion size was observed in the cryotherapy group compared to the control group, with further improvement in the glucantime and glucantime-cryotherapy groups relative to control and cryotherapy groups. By the third week, lesions in all treated groups had completely healed without remaining nodules or lesions. Conversely, untreated lesions in the control group continued to expand, ultimately resulting in mortality.

Saghafipour reported that intralesional glucantime injections achieved 48.1% recovery, while cryotherapy combined with intralesional glucantime achieved 72.2% recovery after seven treatments, with 100% recovery after 12 treatments for the combination group and 91% recovery for glucantime monotherapy [20].

In summary, combining glucantime with cryotherapy improved weight gain and significantly reduced lesion diameter in BALB/c mice. Although no statistically significant differences were observed early in treatment, lesion size decreased substantially by the second week in cryotherapy- and glucantime-treated groups. By the third week, lesions in treated groups had completely healed, while those in the control group had deteriorated. Moreover, amphotericin B alone and combined with cryotherapy resulted in reduced lesion sizes, with significant differences only when compared to the control group. Importantly, spleen examination revealed that all treatments successfully prevented parasite dissemination to the spleen, underscoring the efficacy of these therapies in controlling systemic proliferation of *L. major*.

5. Conclusion

These findings emphasize the superior efficacy of combination therapies, particularly glucantime-cryotherapy, in promoting accelerated and more complete wound healing.

Acknowledgements

The researchers express their gratitude to Saber Habibi, animal facility supervisor, for his collaboration in conducting the experiments.

Compliance with ethical guidelines

This study was approved by the Research Ethics Committee of Sanandaj Branch, Islamic Azad University, Sanandaj, Iran (Code: IR.IAU.SDJ.REC.1402.112).

Funding

This research did not receive any grant from funding agencies in the public, commercial, or non-profit sectors.

Authors' contributions

Conceptualization and study design: Ghazaaleh Adhami; Data acquisition: Sayed Kamyab Sajadi; Data analysis, interpretation, and statistical analysis: Ghazaaleh Adhami and Yahya Maroufi; Writing the original draft: Yahya Maroufi and Sayed Kamyab Sajadi; Review and editing: Yahya Maroufi; Project administration, technical, and material support: Sayed Kamyab Sajadi and Ghazaaleh Adhami.

Conflict of interest

The authors declared no conflict of interest.

Data availability

Data supporting the findings of this study are available upon request from the corresponding author.

References

[1] Mann S, Frasca K, Scherrer S, Henao-Martínez AF, Newman S, Ramanan P, et al. A review of leishmaniasis: Current knowledge and future directions. Curr Trop Med Rep. 2021; 8(2):121-32. [DOI:10.1007/s40475-021-00232-7] [PMID]

[2] Linquest LA, Hickham LC, Richardson BJ, Hickham PR. Successful treatment of cutaneous leishmaniasis with cryotherapy. Cureus. 2023; 15(7):e41871. [DOI:10.7759/cureus.41871] [PMID]

[3] Saghafipour A, Mozaffari E, Rezaei F. The evaluation of intralesional glucantime and cryotherapy plus intralesional glucantime therapeutic efficacy on zoonotic cutaneous leishmaniasis: A randomized clinical trial. J Pediatr Perspect, 2017; 5(12): 6689-97. [DOI:10.22038/ijp.2017.24545.2069]

[4] Chakravarty J, Sundar S. Current and emerging medications for the treatment of leishmaniasis. Expert Opin Pharmacother. 2019; 20(10):1251-65. [DOI:10.1080/14656566.2019.1609940] [PMID]

[5] Solomon M, Ollech A, Pavlotsky F, Barzilai A, Schwartz E, Baum S, et al. Comparison of intralesional sodium stibogluconate versus intralesional meglumine antimoniate for the treatment of leishmania major cutaneous leishmaniasis. Acta Derm Venereol. 2024; 104:adv35089. [DOI:10.2340/actadv.v104.35089] [PMID]

[6] Copeland NK, Aronson NE. Leishmaniasis: Treatment updates and clinical practice guidelines review. Curr Opin Infect Dis. 2015; 28(5):426-37. [DOI:10.1097/QCO.0000000000000194] [PMID]

[7] Sacks DL, Barral A, Neva FA. Thermosensitivity patterns of old vs. new world cutaneous strains of Leishmania growing within mouse peritoneal macrophages in vitro. Am J Trop Med Hyg. 1983; 32(2):300-4. [DOI:10.4269/ajtmh.1983.32.300] [PMID]

[8] Layegh P, Pezeshkpoor F, Soruri AH, Naviafar P, Moghiman T. Efficacy of cryotherapy versus intralesional meglumine antimoniate (glucantime) for treatment of cutaneous leishmaniasis in children. Am J Trop Med Hyg. 2009; 80(2):172-5. [DOI:10.4269/ajtmh.2009.80.172] [PMID]

[9] Asilian A, Sadeghinia A, Faghihi G, Momeni A. Comparative study of the efficacy of combined cryotherapy and intralesional meglumine antimoniate (Glucantime) vs. cryotherapy and intralesional meglumine antimoniate (Glucantime) alone for the treatment of cutaneous leishmaniasis. Int J Dermatol. 2004; 43(4):281-3. [DOI:10.1111/j.1365-4632.2004.02002.x] [PMID]

[10] Panagiotopoulos A, Stavropoulos PG, Hasapi V, Papakonstantinou AM, Petridis A, Katsambas A. Treatment of cutaneous leishmaniasis with cryosurgery. Int J Dermatol. 2005; 44(9):749-52. [DOI:10.1111/j.1365-4632.2005.02628.x] [PMID]

[11] Mosleh IM, Geith E, Natsheh L, Schönian G, Abotteen N, Kharabsheh S. Efficacy of a weekly cryotherapy regimen to treat Leishmania major cutaneous leishmaniasis. J Am Acad Dermatol. 2008; 58(4):617-24. [DOI:10.1016/j.jaad.2007.12.032] [PMID]

[12] López-Carvajal L, Cardona-Arias JA, Zapata-Cardona MI, Sánchez-Giraldo V, Vélez ID. Efficacy of cryotherapy for the treatment of cutaneous leishmaniasis: Meta-analyses of clinical trials. BMC Infect Dis. 2016; 16:360. [DOI:10.1186/s12879-016-1663-3] [PMID]

[13] Sundar S, Chakravarty J. An update on pharmacotherapy for leishmaniasis. Expert Opin Pharmacother. 2015; 16(2):237-52. [DOI:10.1517/14656566.2015.973850] [PMID]

[14] Brito NC, Rabello A, Cota GF. Efficacy of pentavalent antimoniate intralesional infiltration therapy for cutaneous leishmaniasis: A systematic review. PLoS One. 2017; 12(9):e0184777. [DOI:10.1371/journal.pone.0184777] [PMID]

[15] Salmanpour R, Razmavar MR, Abtahi N. Comparison of intralesional meglumine antimoniate, cryotherapy and their combination in the treatment of cutaneous leishmaniasis. Int J Dermatol. 2006; 45(9):1115-6. [DOI:10.1111/j.1365-4632.2006.02822.x] [PMID]

[16] Maroufi Y, Ghaffarifar F, Dalimi A, Sharifi Z. Interferon-gamma and interlukin-4 patterns in BALB/c mice suffering from cutaneous leishmaniasis treated with cantharidin. Jundishapur J Microbiol. 2014; 7(6):e10907. [DOI:10.5812/jjm.10907] [PMID]

[17] Esfandiarpour I, Alavi A. Evaluating the efficacy of allopurinol and meglumine antimoniate (Glucantime) in the treatment of cutaneous leishmaniasis. Int J Dermatol. 2002; 41(8):521-4. [DOI:10.1046/j.1365-4362.2002.01526.x] [PMID]

[18] Farajzadeh S, Ahmadi R, Mohammadi S, Pardakhty A, Khalili M, Aflatoonian M. Evaluation of the efficacy of intralesional Glucantime plus niosomal zinc sulphate in comparison with intralesional Glucantime plus cryotherapy in the treatment of acute cutaneous leishmaniasis, a randomized clinical trial. J Parasit Dis. 2018; 42(4):616-20. [DOI:10.1007/s12639-018-1044-5] [PMID]

[19] Lima HC, Bleyenberg JA, Titus RG. A simple method for quantifying Leishmania in tissues of infected animals. Parasitol Today. 1997; 13(2):80-2. [DOI:10.1016/S0169-4758(96)40010-2] [PMID]

[20] Saghafipour A, Rassi Y, Norooze M. [Comparison of efficacy of intercessional injection of glucantime and cryotherapy with intralesional injection in the treatment of zoonotic cutaneous Leishmaniasis: A randomized clinical trial (Persian)]. J Knowl Health Basic Med Sci. 2013; 8(2):62-6. [Link]