Archives of Razi Institute Journal
"Arch. Razi Inst."

Journal Homepage: https://archrazi.areeo.ac.ir/

Research Paper

Antidiabetic Properties of the Chitosan Nanoparticles Loaded *Hypericum perforatum* L. and *Trigonella gracum* Seeds in Rats

Mahboubeh Mansourian[1], Fatemeh Noroozi[2], Mehrorang Ghaedi[2], Amirhossein Doustimotlagh[1], Hassan Bardania[1], Mahdokht Azizi[1], Hossein Kargar Jahromi[3*]

1. Medicinal Plants Research Center, Yasuj University of Medical Sciences, Yasuj, Iran.
2. Department of Chemistry, Faculty of Basic Sciences, Yasouj University, Yasouj, Iran.
3. Research Center for Non-communicable Diseases, Jahrom University of Medical Sciences, Jahrom, Iran.

Use your device to scan and read the article online

How to cite this article Mansourian M, Noroozi F, Ghaedi M, Doustimotlagh A, Hassan Bardania H, Azizi M, et al. Antidiabetic Properties of the Chitosan Nanoparticles Loaded *Hypericum perforatum* L. and *Trigonella gracum* Seeds in Rats. Archives of Razi Institute Journal. 2026; 81(1):127-136. https://doi.org/10.66224/ARI.81.1.3298

https://doi.org/10.66224/ARI.81.1.3298

Article info:
Received: 09 Sep 2025
Accepted: 11 Nov 2025
Published: 01 Jan 2026

Keywords:
Metformin, Streptozocin, Rats, Chitosan, Nanoparticles, *Hypericum perforatum* L., *Trigonella gracum*

ABSTRACT

Introduction: This study was performed to compare the effects of metformin, *Hypericum perforatum* L., and *Trigonella gracum* seeds, both alone and combined with chitosan nanoparticles, on streptozotocin-induced diabetes in rats.

Materials & Methods: 96 adult male Wistar were divided into 12 groups: Control, diabetic, diabetic mellitus receiving buffer, pure chitosan nanoparticles, metformin (250 mg/kg), hydroalcoholic extracts of *H. perforatum* (200 mg/kg) and *T. gracum* seeds (100 mg/kg), and nano-extract of *H. perforatum*, and *T. gracum* seed, alone and in combination. The healthy group received extracts of both plants at a dose of 300 mg/kg. The biochemical parameters, including liver enzymes, blood glucose, rat weight, malondialdehyde (MDA), ferric reducing ability of plasma (FRAP), and superoxide dismutase (SOD), as well as histopathological changes in liver tissue, were determined.

Results: The diabetic groups treated with metformin and nanoparticles containing two extracts (alone and in combination) showed significantly improved rats weight, alkaline phosphatase (ALP), MDA, and SOD levels ($P \leq 0.05$). Chitosan nanoparticles containing the combined extracts showed a more significant improvement in glucose levels than the diabetic groups treated with the extracts alone ($P \leq 0.05$).

Conclusion: The livers of diabetic rats treated with the extract alone, and nano-extract of *T. gracum* seeds, and with a combination of the selected extracts (alone and in combination with nanoparticles) showed significant improvement in histopathological changes. It seems that chitosan nanoparticles containing combined extracts of *H. perforatum* and *T. gracum* seeds are good candidates for further evaluation as effective factors for the control of diabetes.

*** Corresponding Author:**
Hossein Kargar Jahromi, Assistant Professor.
Address: *Research Center for Non-communicable Diseases, Jahrom University of Medical Sciences, Jahrom, Iran.*
Tel: *+98 (71) 54475021*
E-mail: *hossein.kargarjahromy@gmail.com*

Copyright © 2026 The Author(s);
This work is licensed under a Creative Commons Attribution-NonCommercial 4.0 International license(https://creativecommons.org/licenses/by-nc/4.0/).
Noncommercial uses of the work are permitted, provided the original work is properly cited.

1. Introduction

The number of people with diabetes mellitus worldwide has increased significantly over the last two decades. The International Diabetes Federation (IDF) predicts there will be 578 million more adults with diabetes by 2030 and as many as 700 million by 2045. Based on World Health Organization (WHO) reports in 2020, the overall prevalence of diabetes in Iran is 10.3%. Individuals, societies, and economies are heavily impacted by diabetes, which costs 760 billion USD annually in healthcare expenses [1]. Multiple pathogenic processes play a role in the development of diabetes. Insulin deficiency can be caused by autoimmune destruction of pancreatic β -cells or abnormalities leading to insulin resistance. The lack of insulin action in target tissues is responsible for the abnormalities in carbohydrate, fat, and protein metabolism in diabetes [2].

There is increasing evidence that oxidative stress plays a role in the development of diabetes mellitus and its complications. The metabolic abnormalities associated with diabetes lead to mitochondrial superoxide overproduction [3]. There are several treatment options for this disease, such as lifestyle changes and medications, the most well-known approach involves using various drugs such as metformin and injectable insulin. Metformin or 1,1-dimethylbiguanide, is the most widely prescribed oral hypoglycaemic drug, functioning by improving insulin resistance [4]. Medicinal plants are widely used to treat and control diseases because they are less expensive and generally have fewer side effects than synthetic drugs. These include *Hypericum perforatum L.* [5] and *Trigonella gracum* (Fenugreek or Leguminosae) [6]. The bioactive compounds of *H. perforatum* include hypericin, pseudohypericin, hyperforin, adperforin, and phytoestrogens such as kaempferol, rutin, quercetin, luteolin, myristicin, and tannins. While the most common use of this plant is for its antidepressant properties, it also has anti-inflammatory, antimicrobial, anticancer, antiviral activities, and is used for obesityassociated complications such as type II diabetes [5, 7, 8]. The active components of *T. gracum* include steroidal saponins (such as diosgenin, gitogenin, alkaloids such as trigonelline, gentanin and carpaine choline, flavonoids such as quercetin, epigenin, orientin, isoorientin, kaempferol, vitexin, and tannic acid). The most common uses of this plant are for menstrual pain, relieving stomach problems, and as an antioxidant, antibacterial, antifungal, anti-inflammatory, antihyperlipidemic, antihypertensive and antidiabetes. Its seeds are rich in fibre and contain steroidal saponins and proteins comparable to those found in soybean [6, 9-11].

1.1. Objectives

Considering that the seeds of *T. gracum* [6, 12] and *H. perforatum* [7, 8, 12] are used alone in traditional medicine as antidiabetic agents and possess antioxidant properties, the main objective of this study was to evaluate and compare the effects of metformin, *H. perforatum* (herbal number: Hyu325B107), and *T. gracum* seeds (herbal number: Hju1142), both alone and in combination with low molecular weight chitosan nanoparticles, on streptozotocin (STZ)-induced diabetes in rats.

2. Material and Methods

2.1. Collection of plants

H. perforatum and *T. gracum* were collected in April 2019 from the highlands of Dena in Kohgiluyeh and Boyer-Ahmad Province, Iran. The samples were verified by Yasouj Agricultural and Natural Research Centre. After collection, the plants were cleaned, placed in the air, protected from direct light for drying, for several days. They were then crushed and prepared for extraction. Specifically, 100 grams of the dried plant was doused with 1000 mL of solvent (70% ethanol), which obtained 8.5 grams extract of *H. perforatum* and 2.4 grams of *T. gracum*. The resulting mixture was kept at 37 ˚C for 48 hours. The solution was then sifted using the Whatman No. 1 filter paper. A revolving gadget was used to concentrate the resulting mixture as much as possible under vacuum conditions. At that point, the extract was dried in an incubator at 50 ˚C and stored in a freezer at -20 ˚C [13].

2.2. Animals and their classification

Male Wistar rats, weighing 230–250 g and aged 84-91 days, were obtained from the Yasuj Animal Service Centre and maintained under the standard conditions (12 hours light–dark cycle; 23±1 ˚C; 45-55% humidity) with free access to water and conventional rat chow. Diabetes mellitus was induced in overnight fasting rats by a single intraperitoneal infusion of naturally arranged 55 mg/kg STZ in 0.01 M citrate buffer (pH 4.5) (CAS: 18883-66-4, Sigma-Aldrich, Germany) [14]. 24 hours after STZ administration, rats have received a glucose solution (2 mL/kg bw) to dodge hypoglycemic mortality. To confirm the induction of diabetes, blood samples were collected from the tail vein of fasted rats at 72, 120, 240, and 336 hours post-injection, and blood glucose was measured using a glucometere to affirm diabetes mellitus. Rats with a fasting blood glucose of >322 mg/dL were considered diabetic and utilized for this study [15]. Following the 14-day period to confirm diabetes, the drugs were administered to the animals via oral gavage for 14 consecutive days (on the fifteenth day).

2.3. Experimental design

Animals were randomly divided into control (n=8) and diabetic (n=88) groups, with four rats per cage. In this study, 96 adult male Wistar rats were usedand divided into 12 healthy control groups (control), diabetes mellitus receiving 55 mg/kg STZ (DM), diabetes mellitus with buffer (DM+Bufer), pure chitosan (Molecular Weight 50-190 kDa, deacitilation degree 75-85%, Sigma-Aldrich, Germany) nanoparticles (DM+Nano), metformin (CAS: 1115-70-4, molecular weight 165.62, Sigma-Aldrich) at a dose of 250 mg/kg (DM+Met) [4], *H. perforatum* flower extract at a dose of 200 mg/kg (DM+HP) [7], *T. gracum* seed extract at a dose of 100 mg/kg (DM+TG) [9], combined extracts of *H. perforatum* and *T. gracum* seeds at a dose of 300 mg/kg (DM+HP+TG), nano extract of *H. perforatum* at a dose of 200 mg/kg (DM+Nano HP), nano extract of *T. gracum* seeds at a dose of 100 mg/kg (DM+Nano TG), combined nano extracts of *H. perforatum* and *T. gracum* seeds at a dose of 300 mg/kg (DM+Nano HP+TG), and healthy recipients of *H. perforatum* and *T. gracum* extracts at a dose of 300 mg/kg (toxic). All treatments were administered by gavage daily between at 8-10 AM for 14 days. Gavage administration was performed on conscious animals using straight gavage needles (14 gauge, 7.6 cm length, 4 mm ball diameter). Body weight and blood glucose were measured on the first, seventh, and fourteenth days to monitor the changes.

2.4. Preparation method of chitosan nanoparticles

To prepare a clear chitosan solution, 10 mg of chitosan was dissolved in 5 mL of 2% acetic acid. Additionally, 7 mg of tripolyphosphate was dissolved in 1 mL of distilled water. Then, depending on the dose of the extract used (for example, for *T. gracum* seeds at a dose of 100 mg/kg), 100 mg of weighed extract powder was added to the clear chitosan solution. A magnetic stirrer bar was added, and the mixture was placed on a stirrer at 900 rpm for 3 minutes. After 3 minutes, the tripolyphosphate solution (7 mg/1 mL distilled water) was added dropwise, and the mixture remained on the stirrer for 30 minutes [16].

2.5. Biochemical assay

Twenty-four hours after the final treatment, animals were anesthetized with ether, blood serum was then isolated, and biochemical tests were performed. Serum liver enzymes, including alkaline phosphatase (ALP) (REF: 102400), alanine aminotransferase (ALT) (REF: 118400), and aspartate aminotransferase (AST) (REF: 118400), were determined using enzymatic colorimetric methods. All blood analyses were performed using Pars Azmoon kits (Pars Azmoon Inc., Tehran, Iran).

2.6. Measurement of oxidative stress indices

2.6.1. Lipid peroxidation assay

Enzyme linked immunosorbent assay (ELISA) kits from Crystal Day Company, China (Cat. N: E0156Ra) were used to measure serum level of MDA.

2.6.2. Superoxide dismutase (SOD) activity assay

ELISA kits manufactured by Crystal Day Company, China (Cat. N: E0168Ra), were used to measure serum levels of SOD.

2.6.3. Measurement of ferric reducing ability of plasma (FRAP)

One mL of plasma test was stored at -70 °C until use. The FRAP measure was performed according to the strategy developed by Benzie and Strain [17]. Briefly, 10 mL of plasma was added to 1.8 mL of a naturally arranged FRAP arrangement, and the absorbance was measured at 593 nm.

2.7. Histological analysis

For histopathologic examinations of rat liver by light microscopy, sample was kept in formalin to evaluate histological changes. Then Subsequently, 5-micron sections were prepared from the tissues and stained with hematoxylin and eosin method [18]. The prepared slides were examined for portal vein inflammation, sinusoidal dilatation, focal inflammation in the liver parenchyma, fibrosis, and steatosis.

2.8. Statistical analysis

Data are presented as Mean±SEM. Statistical differences between groups were analyzed by one-way ANOVA and Duncan test (post hoc). The significance level was set at a $P \leq 0.05$. This work used Smirnov's Cumulogenov test to determine whether the studied variables had a normal distribution; if not, nonparametric tests were used.

3. Results

3.1. Functional findings

The main functional parameters measured 15 days after treatment are summarized in Table 1. Compared with the

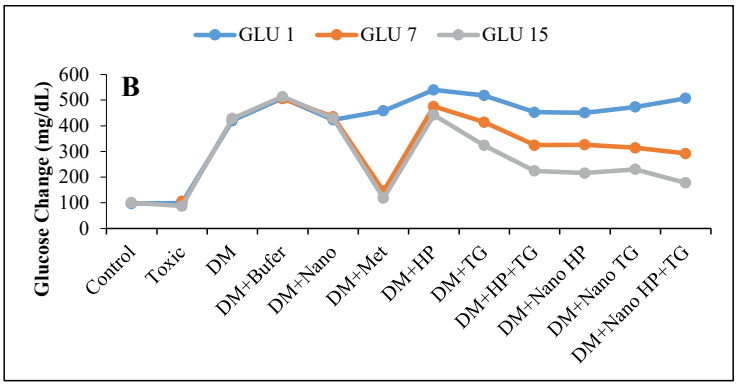

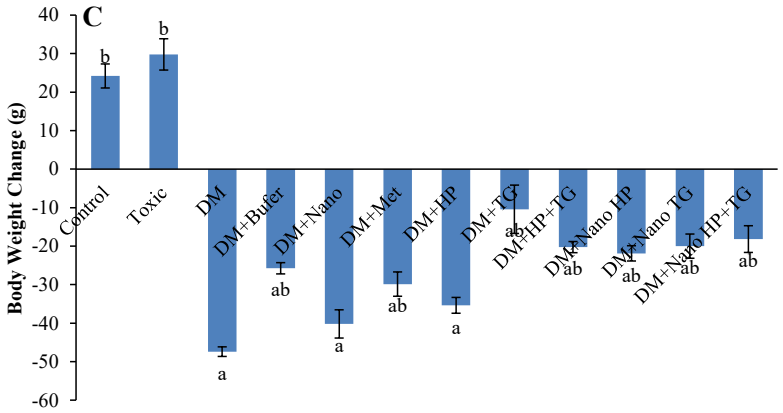

Figure 1. The effect of chitosan nanoparticles containing two hydroalcoholic extracts of *H. perforatum* and *T. gracum* seeds on blood glucose on the 15th day, changes in glucose during the study period (B), and comparison of the body weights in different groups based on the Duncan test during the study period (C)

Abbreviations: HP: Hypericum perforatum; TG: *T. gracum*; Nano: Chitosan nanoparticles; DM: Diabetic mellitus; Met: Metformin; mg/dL: Milligrams per deciliter; G: Gram; GLu1: Glucose of 1 day (mg/dL); GLu7: Glucose of 7 day (mg/dL); GLu15: Glucose of 15 day (mg/dL).

[a]Significant difference compared to the control group (P≤0.05), [b]Significant difference compared to the DM group (P≤0.05).

Note: According to Duncan's test, the columns with at least one common letter differ significantly.

control group, STZ-treated rats showed a significant increase in glucose levels. In addition, serum concentrations of glucose were significantly higher in all experimental groups compared with the control group. All diabetic rats showed a significant difference from the control group on the first day of the study. However, no significant difference was observed between the toxic and control groups. The control, toxic, DM+HP, and DM+TG groups showed a significant difference from the DM group on the first day. By the 15th day of the study, thecontrol, toxic, DM+Met, DM+TG, DM+HP+TG, DM+Nano HP, DM+Nano TG, and DM+Nano HP+TG groups showed a significant difference from the DM group. The combination of extracts, both alone and with chitosan nanoparticles, caused a decrease in blood glucose levels compared to the control group. Metformin and the extracts improved blood glucose levels on day 15 compared with day 7 (Figure 1B).

The result for body weight changes is shown in Figure 1C. Figure 1C shows that all diabetic rats differed significantly from the control group. In addition, no significant difference was found between the toxic and control groups. The control, toxic, DM+TG, DM+HP+TG, DM+Nano HP, DM+Nano TG, and DM+Nano HP+TG groups showed a significant difference from the DM group on the 15th day of the study, whereas the DM+Met and DM+HP groups showed no significant difference. Figure 1C also shows that the changes in glucose levels on days 1 and 15 in all diabetic rats, except the toxic, DM+Nano, DM+HP, and DM+Buffer groups, showed a significant difference compared with the DM and control groups.

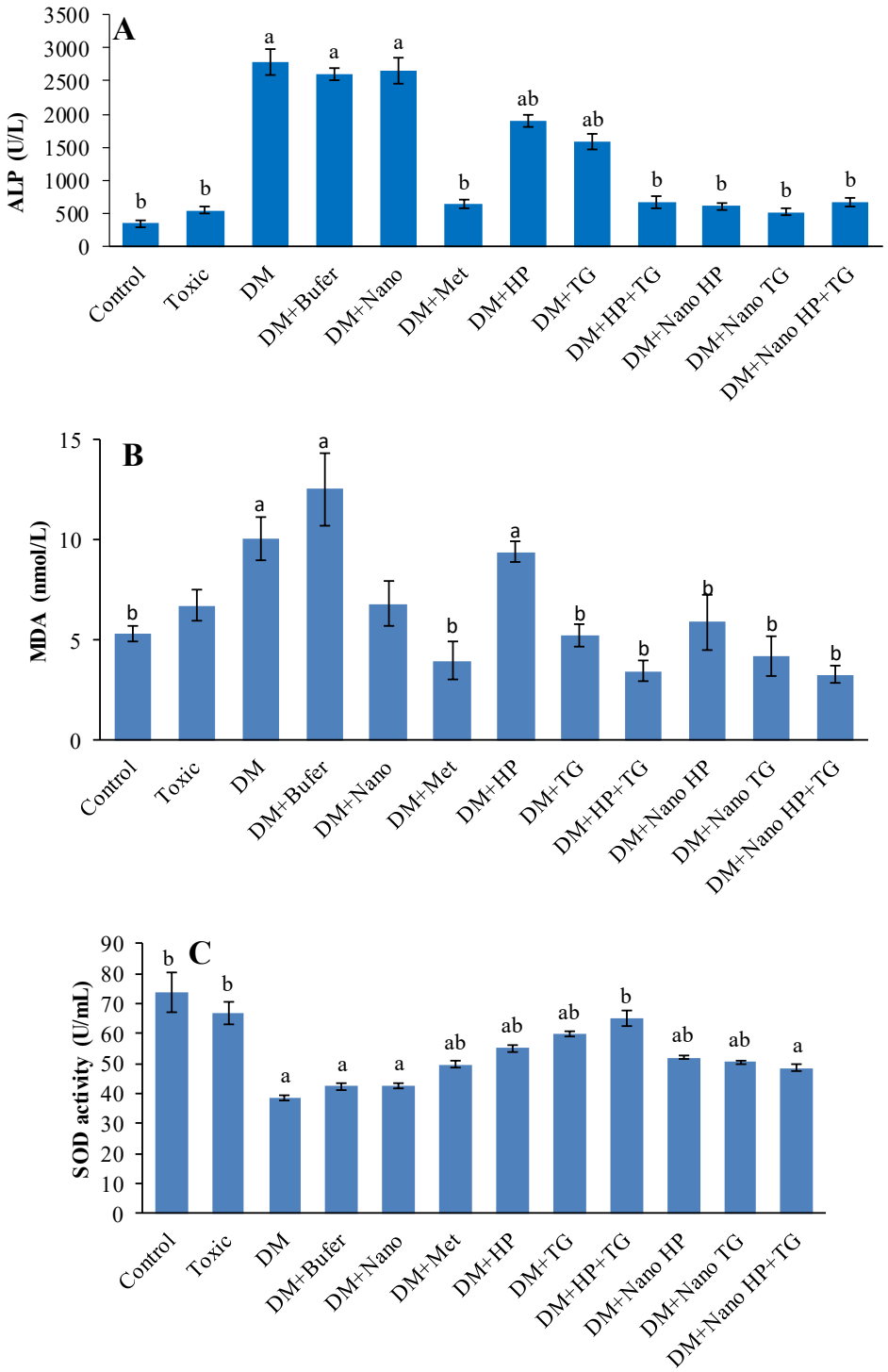

Figure 2. The effect of chitosan nanoparticles containing two hydroalcoholic extracts of *H. perforatum* and *T. gracum* seeds on liver enzymes ALP (A), serum MDA level (B), antioxidant enzyme SOD in the studied groups (C)

Abbreviations: HP: *H. perforatum*; TG: *T. gracum*; Nano: Chitosan nanoparticles; DM: Diabetic mellitus; Met: Metformin. ALP: Alkaline phosphatase; MDA: Malondialdehyde; SOD: Superoxide dismutase; U/mL: Units per litre; nmol/L: Nanomoles per litre; U/mL: Units per milliliter.

[a]Significant difference compared to the control group (P≤0.05). [b]Significant difference compared to the DM group (P≤0.05).

Note: Comparison of the serum level of liver enzymes in different groups based on the Duncan test. According to Duncan's test, the columns with at least one common letter are not significantly different.

Table 1. The effect of chitosan nanoparticles containing hydroalcoholic extracts from the aerial part of *H. perforatum* and *T. gracum* seeds on rats' blood glucose levels on day 1, day 7, and day 15

Groups	Glucose of 1st Day (mg/dL)	Glucose of 7th Day (mg/dL)	Glucose of 15th Day (mg/dL)	Weight of 1st Day (g)	Weight of 15th Day (g)
Control	97±4[b]	-	101±4[b]	237±5	261±7[b]
Toxic	99±3[b]	106±22	88±2[b]	226±2	256±6[b]
DM	420±7[a]	-	429±12[a]	237±5	190±4[a]
DM+Bufer	508±27[a]	506±29	514±23[a]	244±5	219±6[ab]
DM+Nano	424±14[a]	435±25	430±21[a]	235±5	195±6[a]
DM+Met	458±19[a]	146±14	118±7[b]	232±3	203±4[a]
DM+HP	540±14[ab]	475±20	442±21[a]	234±5	198±5[a]
DM+TG	518±19[ab]	414±19	324±26[ab]	240±4	230±5[ab]
DM+HP+TG	453±22[a]	325±19	224±12[ab]	241±3	221±4[ab]
DM+Nano HP	451±7[a]	326±21	216±15[ab]	240±3	218±4[ab]
DM+Nano TG	473±16[a]	314±19	231±16[ab]	243±3	223±3[ab]
DM+Nano HP+TG	507±20[a]	292±15	178±9[b]	240±5	222±3[ab]

Abbreviations: HP: Hypericum perforatum; TG: *T. gracum*; Nano: Chitosan nanoparticles; DM: Diabetic mellitus; Met: Metformin; mg/dL: Milligrams per deciliter; g: Gram.

[a]Significant difference compared to the control group (P≤0.05), [b]Significant difference compared to the DM group (P≤0.05).

3.2. Evaluation of oxidative/antioxidant status and biochemical parameters

Liver injury was assessed by determining the serum levels of liver enzymes. The average serum concentrations of biochemical parameters and oxidative stress markers in the studied groups were determined and compared in Table 2. As shown in Figure 2A, the serum level of the enzyme ALP significantly increased in the DM group (P≤0.05). However, the serum level increase was insignificant for the enzymes ALT and AST (Table 2). Injection of two hydroalcoholic extracts of *H. perforatum* and *T. gracum*, alone and in combination with chitosan nanoparticles, to diabetic rats resulted in a significant decrease in the serum level of ALP enzyme compared with the DM group (P≤0.05).

As shown in Figure 2B, the MDA level in the DM group was significantly increased compared with the control group (P≤0.05). Figure 2B also indicates that administration of metformin and chitosan nanoparticles containing two hydroalcoholic extracts of *H. perforatum* and *T. gracum*, both alone and in combination, to diabetic rats significantly reduced MDA levels compared with the DM group (P≤0.05). In addition, the MDA levels in the DM+TG and DM+HP+TG groups showed a significant decrease compared with the DM group (P≤0.05).

As shown in Table 2, the FRAP level in the DM group was significantly decreased compared with the control group (P≤0.05). However, the level of FRAP showed a non-significant reduction following the administration of chitosan nanoparticles containing the combined extracts compared to the DM group.

As shown in Figure 2C, SOD activity in the DM group was significantly decreased compared with the control group (P≤0.05). The administration of chitosan nanoparticles containing the combination of the two hydroalcoholic extracts *H. perforatum* and *T. gracum* seeds to diabetic rats insignificantly reduced SOD enzyme activity in the DM+Nano HP+TG group compared with the DM group. However, SOD activity in other groups (those receiving metformin, extracts alone, or in combinationwith chitosan nanoparticles showed a significant increase compared with the DM group [P≤0.05]).

3.3. Histological examination

The dissected slides were examined for portal vein inflammation, sinusoidal dilatation, focal inflammation in

Table 2. The effect of chitosan nanoparticles containing hydroalcoholic extracts of aerial part of the *H. perforatum* and *T. gracum* seeds on biochemical parameters and serum oxidative stress markers in the studied groups

Groups	ALP (U/L)	ALT (U/L)	AST (U/L)	MDA (nmol/L)	FRAP (µmol/L)	SOD (U/mL)
Control	346.6±43.07[b]	7.4±3.75	155±9.12	5.29±0.39[b]	1468.37±105.28[b]	73.74±6.83[b]
Toxic	554.6±42.73[b]	65±5.9	130±8.4	6.74±0.78	1196.5±187.54	66.71±3.76[b]
DM	2781.6±199.2[a]	132.8±88.86	278.4±173.12	10.05±1.05[a]	808±19.02[a]	38.49±1.07[a]
DM+Bufer	2609.88±88.28[a]	73.13±7.36	114.88±10.91	25.55±3.82	1149.71±125.64	42.41±1.11[a]
DM+Nano	2655.6±198.76[a]	183.4±48.09	455.4±210.94	6.80±1.12	1103.5±89.92	42.49±1.05[a]
DM+Met	640.29±64.22[b]	178.8±24.71	318.6±38.37	3.98±0.93[b]	1319.42±119.19	49.63±1.30[ab]
DM+HP	1897±102.29[ab]	171.75±35	306.88±95.83	9.39±0.52[a]	979.31±54	55.13±1.1[ab]
DM+TG	1589.75±113.87[ab]	163.5±47.75	348.88±135.01	5.25±0.55[b]	1056.19±118.93	59.70±0.96[ab]
DM+HP+TG	675.13±87.32[b]	113.25±9.54	187.13±24.71	3.47±0.5[b]	959.94±102.64	65.04±2.35[b]
DM+Nano HP	617±50.82[b]	102.38±17.26	196.38±27.89	5.88±1.37[b]	1070.88±96.81	51.99±0.69[ab]
DM+Nano TG	523±47.04[b]	88.2±18.88	208.8±59.22	4.20±0.98[b]	1327.21±174.07	50.46±0.72[ab]
DM+Nano HP+TG	671.±76.67[b]	107±6.4	222±11.41	3.26±0.44[b]	739.83±118.89[a]	48.47±1.04[a]

Abbreviations: HP: *H. perforatum*; TG: *T. gracum*; Nano: Chitosan nanoparticles; DM: Diabetic mellitus; Met: Metformin; ALP: Alkaline phosphatase; ALT: Alanine aminotransferase; AST: Aspartate aminotransferase; MDA: Malondialdehyde; FRAP: Fluoride-resistant acid phosphatase; SOD: Superoxide dismutase U/L: Units per litre; nmol/L: Nanomoles per liter; µmol/L: Micromoles per litre; U/mL: Units per millilitre.

[a]Significant difference compared with the control group (P≤0.05), [b] Significant difference compared with DM group (P≤0.05).

the liver parenchyma, fibrosis, and steatosis, as shown in Figure 3. Histological examinations of the rats in the healthy group revealed no specific pathological findings (Figures 3A and 3B). Liver sections of the diabetic rats showed sinusoidal enlargements around the portal tract (PT) and the central vein (CV) (Figure 3C). The livers of diabetic rats treated with the hydroalcoholic extract of Hypericum perforatum L alone and combined with chitosan nanoparticles showed no significant improvement in histopathological changes, and sinusoidal dilatation around the CV was still observed (Figures 3G and 3J). However, examination of liver tissue showed that the livers of diabetic rats treated with (DM+TG), (DM+Nano TG), (DM+HP+TG), (DM+Nano HP+TG) showed significant improvement in histopathological changes (Figures 3H, 3I, 3K, and 3L). No signs of steatosis, fibrosis, or specific pathology were observed in any of these studied groups. Similarly, no specific pathology was observed in the healthy rats receiving the nanoparticle combination of two hydroalcoholic extracts of *H. perforatum* and *T. gracum* at a total dose of 300 mg/kg (Figure 3B). However, the group receiving a mild buffer solution and chitosan nanoparticles, focal inflammation of the portal vein and focal sinusoidal dilatation around the CV were observed (Figures 3D, and 3E).

4. Discussion

This study showed that STZ administration in adult male rats significantly increased blood glucose, MDA, and liver enzymes ALP, while it decreased body weight, FRAP, and serum SOD in the diabetic group compared to healthy rats (P≤0.05). Liver tissue in diabetic animals becomes necrotic, therefore, the increase in enzyme activity is probably the result of its leakage from the liver cytosol into the bloodstream and injection of two hydroalcoholic extracts of *H. perforatum* and *T. gracum* seeds, alone and in combination with nanoparticles. The results showed that metformin as well as extracts of *H. perforatum* and *T. gracum* seeds (individually and in combination), and chitosan nanoparticles, containing a combination of hydroalcoholic extracts of *H. perforatum* and *T. gracum* seeds at a dose of 300 mg/kg, significantly improved the aforementioned indicators compared with the diabetic

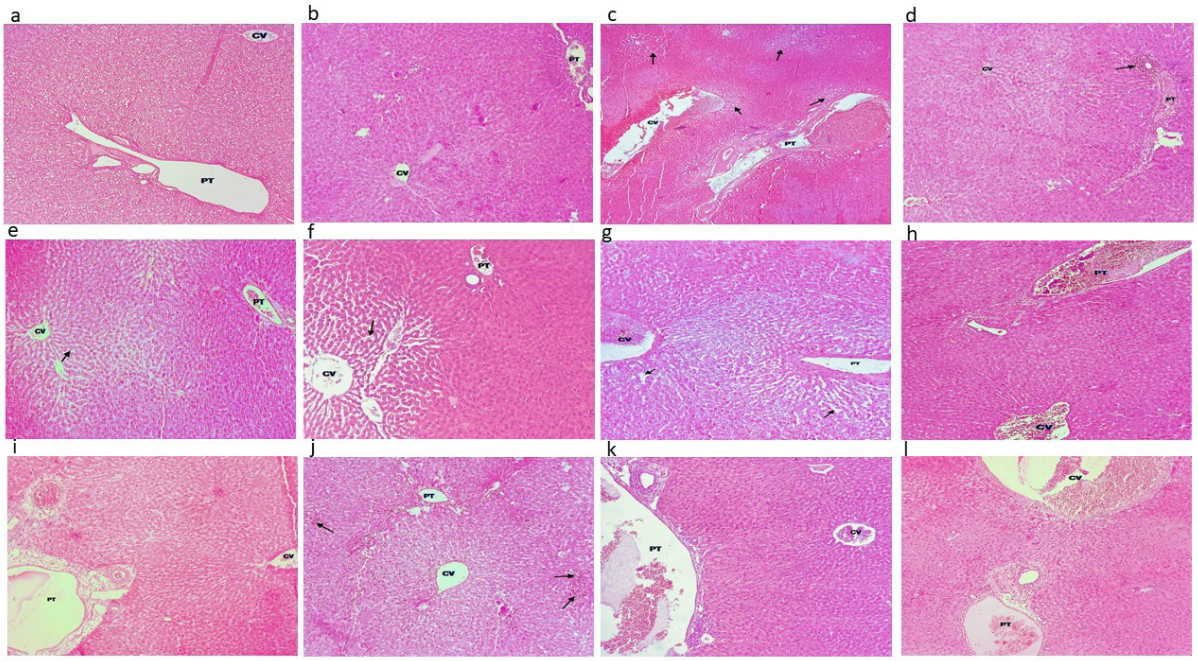

Figure 3. H&E tissue staining and scoring of hepatocytes

Abbreviations: HP: Hypericum perforatum; TG: *T. gracum*; Nano: Chitosan nanoparticles; DM: Diabetic mellitus; Met: Metformin.

Note: The animals were slaughtered at the end of the study, and the liver tissue was examined for the percentage of damaged cells. The study groups included a control group, a toxic group, and ten experimental groups. Group (a): Control; (b): Toxic; (c): Diabetic; (d): Diabetic rats received buffer; (e): DM+Nano; (f): DM+Met; (g): DM+HP; (h): DM+TG; (i): DM+HP+TG; (j): DM+Nano HP; (k): DM+Nano TG; (l): DM+Nano HP+TG.

group. Administration of chitosan to diabetic rats results in a significant decrease ($P \leq 0.05$) in blood glucose and serum biochemical tests such as ALP, MDA, and the antioxidant enzyme SOD and liver tissue improve the condition in diabetic rats. The reduction in these activities is likely the result of the inhibition of induced liver damage. In most patients with type II diabetes, treatment with oral antidiabetic agents is the first-line treatment when lifestyle measures fail. Metformin, sulfonylureas, and thiazolidinediones, the most commonly prescribed antidiabetic agents, can temporarily improve glycemic control. However, despite the continuous introduction of blood glucose-lowering drugs, managing diabetes, and its associated complications remains a major global medical challenge [19]. Since ancient times, traditional medicine has always paid special attention to medicinal plants, and today, through numerous research conducted on medicinal plants, the practical and valuable effects of many plants have been confirmed [6].

Trigonella foenum-graecum seeds are known for their carminative, tonic, and antidiabetic effects. Researchers have studied the hypoglycemic activities of the aqueous and methanolic extract of *T. foenum-graecum* seeds in normal mice via oral administration [6]. The current study, along with previous reports, indicate the therapeutic impact of *T. gracum* against diabetes by ameliorating diabetic hyperglycemia and associated metabolic abnormalities, as well as reducing oxidative stress [6, 9, 10, 20]. Diosgenin saponin, as one of the most bioactive substance of fenugreek, has antioxidative effects and plays a pivotal role in improving the diabetic status through several mechanisms [9, 10].

Several plant-derived chemical compounds, such as flavonoids and phytoestrogens, have inhibitory effects on insulin secretion in humans and animals [9, 21]. *H. perforatum* and *T. foenum-graecum* seeds contain various phytochemical constituents, including flavonoids such as rutin, kaempferol, quercetin and isoquercetin [5-10]. For instance, rutin has been reported to promote insulin emission and lower blood glucose levels in diabetic animals. In rats treated with an ethyl acetate extract of *H. perforatum*, a significant decrease in blood glucose levels and an increase in serum insulin levels were observed. The possible mechanism by which *H. perforatum* exerts its hypoglycemic effect in diabetic rats may be through the potentiation of plasma insulin action by increasing

insulin secretion from existing pancreatic beta cells or its release from the bound form [8]. It is also suggested that, besides phytoestrogens, other components from *H. perforatum* and *T. foenum-graecum* seeds, such as quercetin [21, 22], fisetin [23], kaempferol [24], and myricetin [25] may be a potential means of glycemic control by increasing the activity of the insulin-dependent kinase receptor. Consequently, they induce insulin signaling and increase glucose transporters (GLUT4) and glucose uptake [12]. Quercetin can stimulate glucose uptake in isolated cells without insulin, possibly due to the increased expression of GLUT4 in the plasma membrane. Furthermore, quercetin influences flag transduction and glucose utilization by controlling glucose transport and affront receptor signaling, which plays a comparable part to rosiglitazone as a PPARγ (peroxisome proliferator-activated receptor gamma) agonist, it may also inhibit alpha-glucosidase activity. Insulin sensitivity-increasing factors lead to the improvement of diabetes [12, 21]. In line with our study, the mentioned extracts proved useful and resulted in an antioxidant activity, characterized by an increase in SOD levels and a decrease in MDA formation [7, 11]. It appears that hydroalcoholic extracts of *H. perforatum* and *T. gracum* seeds, combined with chitosan nanoparticles, are good candidates for further evaluation as influential factors in controlling diabetes in the future.

5. Conclusion

The livers of diabetic rats treated with the extract alone, and nano-extract of *T. gracum* seeds, and with a combination of the selected extracts (alone and in combination with nanoparticles) showed significant improvement in histopathological changes. It seems that chitosan nanoparticles containing combined extracts of *H. perforatum* and *T. gracum* seeds are good candidates for further evaluation as effective factors for the control of diabetes.

Acknowledgements

The authors thank the Deputy of Research of Yasuj University of Medical Sciences and Yasouj University for their financial support.

Compliance with ethical guidelines

The Research Ethical Committee of Yasuj University of Medical Sciences approved this study. All experimental protocols, proposals, and methods followed relevant guidelines. They were approved by the Animal Ethics Committee at Yasuj University of Medical Sciences, Yasuj, Iran (Code: IR.YUMS.REC.1397.162).

Data availability

There are no additional data. All data generated or analyzed during this study are included in this published article.

Funding

This Research was supported Yasuj University of Medical Sciences, Yasuj, Iran.

Authors' contributions

Conceptualization and methodology: Mahboubeh Mansourian, Hossein Kargar Jahromi, and Mehrorang Ghaedi; Investigation: Fatemeh Noroozi, Hossein Kargar Jahromi, Mahboubeh Mansourian, Amirhossein Doustimotlagh, Hassan Badania, and Mahdokht Azizi; Data collection: Fatemeh Noroozi, Amirhossein Doustimotlagh, Hassan Badania, Mahdokht Azizi; Data analysis: Mahboubeh Mansourian, Hossein Kargar Jahromi, and Mehrorang Ghaedi; Writing: All authors; Supervision: Hossein Kargar Jahromi.

Conflict of interest

The authors declared no conflict of interest.

References

[1] Novelli M, Masiello P, Beffy P, Menegazzi M. Protective Role of St. John's Wort and Its Components Hyperforin and Hypericin against Diabetes through Inhibition of Inflammatory Signaling: Evidence from In Vitro and In Vivo Studies. Int J Mol Sci. 2020; 21(21):8108. [DOI:10.3390/ijms21218108] [PMID]

[2] Roep BO, Thomaidou S, van Tienhoven R, Zaldumbide A. Type 1 diabetes mellitus as a disease of the β-cell (do not blame the immune system?). Nat Rev Endocrinol. 2021; 17(3):150-61. [DOI:10.1038/s41574-020-00443-4] [PMID]

[3] Giacco F, Brownlee M. Oxidative stress and diabetic complications. Circ Res. 2010; 107(9):1058-70. [DOI:10.1161/CIRCRESAHA.110.223545] [PMID]

[4] Yu JW, Deng YP, Han X, Ren GF, Cai J, Jiang GJ. Metformin improves the angiogenic functions of endothelial progenitor cells via activating AMPK/eNOS pathway in diabetic mice. Cardiovasc Diabetol. 2016; 15:88. [DOI:10.1186/s12933-016-0408-3] [PMID]

[5] Tokgöz HB, Altan F. Hypericum perforatum L.: A medicinal plant with potential as a curative agent against obesity-associated complications. Mol Biol Rep. 2020; 47(11):8679-86. [DOI:10.1007/s11033-020-05912-7] [PMID]

[6] Zia T, Hasnain SN, Hasan SK. Evaluation of the oral hypoglycaemic effect of Trigonella foenum-graecum L. (methi) in normal mice. J Ethnopharmacol. 2001; 75(2-3):191-5. [DOI:10.1016/S0378-8741(01)00186-6] [PMID]

[7] Abd El Motteleb DM, Abd El Aleem DI. Renoprotective effect of Hypericum perforatum against diabetic nephropathy in rats: Insights in the underlying mechanisms. Clin Exp Pharmacol Physiol. 2017; 44(4):509-21. [DOI:10.1111/1440-1681.12729] [PMID]

[8] Arokiyaraj S, Balamurugan R, Augustian P. Antihyperglycemic effect of Hypericum perforatum ethyl acetate extract on streptozotocin-induced diabetic rats. Asian Pac J Trop Biomed. 2011; 1(5):386-90. [DOI:10.1016/S2221-1691(11)60085-3] [PMID]

[9] Baset ME, Ali TI, Elshamy H, El Sadek AM, Sami DG, Badawy MT, et al. Anti-diabetic effects of fenugreek (Trigonella foenum-graecum): A comparison between oral and intraperitoneal administration-an animal study. Int J Funct Nutr. 2020; 1(1):2. [DOI:10.3892/ijfn.2020.2]

[10] Bahmani M, Shirzad H, Mirhosseini M, Mesripour A, Rafieian-Kopaei M. A review on ethnobotanical and therapeutic uses of fenugreek (Trigonella foenum-graceum L). J Evid Based Complementary Altern Med. 2016; 21(1):53-62. [DOI:10.1177/2156587215583405] [PMID]

[11] Tewari D, Jóźwik A, Łysek-Gładysińska M, Grzybek W, Adamus-Białek W, Bicki J, et al. Fenugreek (Trigonella foenum-graecum L.) seeds dietary supplementation regulates liver antioxidant defense systems in aging mice. Nutrients. 2020; 12(9):2552. [DOI:10.3390/nu12092552] [PMID]

[12] AL-Ishaq RK, Abotaleb M, Kubatka P, Kajo K, Büsselberg D. Flavonoids and their anti-diabetic effects: Cellular mechanisms and effects to improve blood sugar levels. Biomolecules. 2019; 9(9):430. [DOI:10.3390/biom9090430] [PMID]

[13] Nadimi M, Zia M, Madani M. The effect of aqueous and ethanolic extracts of Teucrium polium on Candida albicans and two species of malassezia. Zahedan J Res Med Sci. 2013; 15(8):34-8. [Link]

[14] Singh R, Parasuraman S, Kathiresan S. Antioxidant and antidiabetic activities of methanolic extract of bark of Cinnamomum zeylanicum in diabetic rats. Free Radic Antioxid. 2020; 10(1):16-23. [DOI:10.5530/fra.2020.1.4]

[15] Chaudhry ZZ, Morris DL, Moss DR, Sims EK, Chiong Y, Kono T, et al. Streptozotocin is equally diabetogenic whether administered to fed or fasted mice. Lab Anim. 2013; 47(4):257-65. [DOI:10.1177/0023677213489548] [PMID]

[16] Khalili ST, Mohsenifar A, Beyki M, Zhaveh S, Rahmani-Cherati T, Abdollahi A, et al. Encapsulation of Thyme essential oils in chitosan-benzoic acid nanogel with enhanced antimicrobial activity against Aspergillus flavus. LWT - Food Sci Technol. 2015; 60(1):502-8. [DOI:10.1016/j.lwt.2014.07.054]

[17] Benzie IF, Strain JJ. The ferric reducing ability of plasma (FRAP) as a measure of "antioxidant power": The FRAP assay. Anal Biochem. 1996; 239(1):70-6. [DOI:10.1006/abio.1996.0292] [PMID]

[18] Doustimotlagh AH, Taheri S, Mansourian M, Eftekhari M. Extraction and identification of two flavonoids in Phlomoides hyoscyamoides as an endemic plant of Iran: The role of quercetin in the activation of the glutathione peroxidase, the improvement of the hydroxyproline and protein oxidation in bile duct-ligated rats. Curr Comput Aided Drug Des. 2020; 16(5):629-40. [DOI:10.2174/1573409915666190903163335] [PMID]

[19] Zhang M, Chen L. Berberine in type 2 diabetes therapy: A new perspective for an old antidiarrheal drug? Acta Pharm Sin B. 2012; 2(4):379-86. [DOI:10.1016/j.apsb.2012.06.004]

[20] Pradeep SR, Srinivasan K. Amelioration of oxidative stress by dietary fenugreek (Trigonella foenum-graecum L.) seeds is potentiated by onion (Allium cepa L.) in streptozotocin-induced diabetic rats. Appl Physiol Nutr Metab. 2017; 42(8):816-28. [DOI:10.1139/apnm-2016-0592] [PMID]

[21] Shi GJ, Li Y, Cao QH, Wu HX, Tang XY, Gao XH, et al. In vitro and in vivo evidence that quercetin protects against diabetes and its complications: A systematic review of the literature. Biomed Pharmacother. 2019; 109:1085-99. [DOI:10.1016/j.biopha.2018.10.130] [PMID]

[22] Jiang H, Yamashita Y, Nakamura A, Croft K, Ashida H. Quercetin and its metabolite isorhamnetin promote glucose uptake through different signalling pathways in myotubes. Sci Rep. 2019; 9(1):2690. [DOI:10.1038/s41598-019-38711-7] [PMID]

[23] Althunibat OY, Al Hroob AM, Abukhalil MH, Germoush MO, Bin-Jumah M, Mahmoud AM. Fisetin ameliorates oxidative stress, inflammation and apoptosis in diabetic cardiomyopathy. Life Sci. 2019; 221:83-92. [DOI:10.1016/j.lfs.2019.02.017] [PMID]

[24] Alkhalidy H, Moore W, Wang Y, Luo J, McMillan RP, Zhen W, et al. The flavonoid kaempferol ameliorates streptozotocin-induced diabetes by suppressing hepatic glucose production. Molecules. 2018; 23(9):2338. [DOI:10.3390/molecules23092338] [PMID]

[25] Ong KC, Khoo HE. Effects of myricetin on glycemia and glycogen metabolism in diabetic rats. Life Sci. 2000; 67(14):1695-705. [DOI:10.1016/S0024-3205(00)00758-X] [PMID]