

Synergistic Influences of Mentha Piperita and Clinoptilolite: A Study on Histologic and Morphometric Outcomes

Ghasemi, M¹, Parhizkar Roudsari, P¹, Ghasem Ahangari, M¹, Takzaree, N^{1*}

1. Department of Anatomy and Medicinal Plants Research Center, School of Medicine, Tehran University of Medical Sciences, Tehran, Iran.

How to cite this article: Ghasemi M, Parhizkar Roudsari P, Ghasem Ahangari M, Takzaree N. Synergistic Influences of Mentha Piperita and Clinoptilolite: A Study on Histologic and Morphometric Outcomes. *Archives of Razi Institute*. 2024;79(6):1197-1205. DOI: 10.32592/ARI.2024.79.6.1197



Copyright © 2023 by



Razi Vaccine & Serum Research Institute

ABSTRACT

The restoration of healthy human skin function in the early stages is contingent upon the effective healing of wounds. This process requires the highest quality of care. While previous research has examined the individual impacts of Mentha Piperita and clinoptilolite, this experiment demonstrates their synergistic effects, presenting a promising new approach to expedite wound recovery. The study employed a total of 60 male Wistar rats, which were randomly assigned to one of five experimental groups: a negative control group, a positive control group (phenytoin ointment), a clinoptilolite group, an M. Piperita group, and an M. Piperita + clinoptilolite group. All ethical considerations were upheld, and neck wounds were created. Histological examinations were conducted on days 4, 7, and 14. Additionally, collagen deposition, inflammation, and re-epithelialization scores were evaluated on day 14 using the scoring system developed by Abramov. Wound healing assays were conducted on days 4, 7, 10, and 14. A p-value of less than 0.05 was considered statistically significant. The M. Piperita + clinoptilolite group demonstrated a statistically significant increase in the number of fibroblasts and vessels, accompanied by a notable reduction in the inflammatory cell count, when compared to all other experimental groups within the wound site. Furthermore, all groups exhibited significantly elevated collagen deposition and re-epithelialization scores (P-value <0.05) and diminished inflammatory cell infiltration (though not reaching statistical significance) compared to the control group. Furthermore, the M. Piperita + clinoptilolite group exhibited a markedly reduced wound surface area and accelerated healing rate compared to all other groups on all experimental days. On day 14, the recovery percentage reached an impressive 99.75 ± 0.5 . The combination of clinoptilolite and M. piperita exerts a significant influence on wound healing, as evidenced by the histopathologic parameters and clinical outcomes. This combination is more effective than the separate usage of either substance or phenytoin.

Keywords: Wound Healing, Wounds, Injuries, Zeolites.

Article Info:

Received: 11 August 2023

Accepted: 4 February 2024

Published: 31 December 2024

Corresponding Author's E-Mail:
nasrintakzareetums@gmail.com

1. Introduction

Wound healing is a systematic and sequential process comprising various cells, growth factors, and mediators. Its objective is to restore normal skin integrity and functions (1, 2). Therapeutic strategies should therefore be devised to promote tissue repair (3-5). Wound healing represents a significant challenge in medical practice, given the potential for infection and the long-term complications that may arise (6). Furthermore, the increase in the elderly population and the growing number of individuals with diabetes has led to a higher prevalence of chronic wounds. Therefore, it is of great importance to focus on the development of novel therapeutic approaches that are of higher quality and more rapid in their efficacy. However, the associated adverse effects of the current therapeutic approaches have constrained their utilization and prompted researchers to identify and examine natural products (8-10). The use of medicinal plants in the context of wound healing represents a significant area of interest (11). In this context, *Mentha Piperita* (commonly known as peppermint) from the Lamiaceae family (12) has demonstrated a noteworthy capacity for tissue repair in a number of studies (8, 11). *Mentha Piperita* has been linked to a range of antioxidant, antimicrobial, and antitumorigenic properties, making it one of the most commonly used herbs globally, particularly in the context of traditional medicine (13). In addition to its established benefits in the treatment of digestive complaints, menstrual cramps, neuralgia, myalgia, the common cold, oral mucosa inflammation, and headaches (14), the wound-repairing influences of this product have also been investigated in some studies (15, 16). Conversely, zeolites are natural or synthetic products with a multitude of medical applications. Their distinctive properties, coupled with their microporous structure and high stability, render them exceptional materials for tissue engineering applications (17, 18). The natural zeolite clinoptilolite has been the subject of investigation by some studies for its potential use in wound treatment and kidney dialysis. These studies have demonstrated that it does not exert any toxic effects on the body system. The neutral natural basis of this mineral in association with its non-toxic usage has reinforced the prospect of its efficacious utilisation in wound treatment (19). The use of clinoptilolite-containing products has demonstrated superior efficacy in wound healing outcomes compared to synthetic zeolites, which have been shown to have potential applications in this field (20). To date, there have been only a limited number of studies that have investigated the wound healing functions of *M. Piperita* and clinoptilolite separately (16, 19). Furthermore, there are currently no studies that have explored the potential synergistic effects of these substances. Accordingly, this study has concentrated on demonstrating the reparative effects of *M. Piperita* and clinoptilolite in combination with one another in comparison to these substances alone, phenytoin, and the control group, due to the considerable capacities of these substances. To assess the effects of this combination on the

wound healing process, multiple macroscopic and microscopic evaluations have been performed.

2. Materials and Methods

2.1. Experimental design

This experimental research was conducted on 60 adult male Wistar rats (weight 200–240 g, age 3–4 months) with approval from the Ethics Committee of Tehran University of Medical Sciences. (Ethics code: IR.TUMS.MEDICINE.REC.1400.477). The authors have indicated that they have obtained approval from the relevant institutional review board or otherwise adhered to the principles set forth in the Declaration of Helsinki for all experiments. The rats were housed in individual cages with access to a proper source of food and water and maintained at a temperature of 20–25°C under 12/12-hour light/dark cycles. The rats were anesthetized prior to excision production via an intramuscular injection of Ketamine hydrochloride (5 mg/100 g body weight), Diazepam (0.45 mg/100 g body weight), and Pentazocine (0.04 mg/100 g body weight). In summary, the surgical site on the rats' necks was shaved and disinfected with povidone-iodine, and full-thickness wounds measuring 10 × 10 mm were created on each rat on the designated surgical day, which was identified as day zero. The rats were divided into five groups: a negative control group, a positive control group (phenytoin ointment), and three experimental groups. The first experimental group was treated with *M. Piperita*, the second with clinoptilolite, and the third with a combination of *M. Piperita* and clinoptilolite. Each group was further subdivided into three groups of four, seven, and 14 subjects, respectively, for the duration of the experimental period. On the first day of the experiment, the wounds were treated with one of four different combinations of topical medications: a 1% phenytoin ointment, a 5 mg clinoptilolite ointment, a 5 mg *M. piperita* essence, or a combination of these two. The negative control group was not subjected to any form of treatment.

2.2. *Mentha Piperita* Essence Preparation

The fresh leaves of *M. piperita* were obtained from the Kashan Medicinal Plants Garden in Iran in August 2021. Following confirmation of the pharmacognostic characteristics, the samples were washed and dried. One hundred grams of the obtained powder were mixed with four hundred milliliters of water in the Clevenger apparatus. The requisite essence was produced after a five-hour period and subsequently underwent dehydration (using sodium anhydride sulfate). Subsequently, the substance was placed in a dark container and refrigerated. Our expert colleagues have determined that menthol and menthone are the primary constituents.

2.3. Clinoptilolite Preparation

The clinoptilolite nanocomplex functions by trapping molecules within a molecular cage through the formation of hydrogen bonds with water. The clinoptilolite powder was solubilized in distilled water (at a proportion of 20 mg/1cc) and mixed for a period of three minutes at a temperature of

37°C. The resulting ointment is stored in a dark container to prevent light-induced degradation.

2.4. Wound healing assay

The wound healing rate was evaluated based on wound surface measurement and recovery rate on days 1, 4, 7, 10, and 14. The wound surface was measured by tracing it on a transparent, millimeter-scale sheet. The healing percentage is also calculated using the following formula:

$$\text{Healing percentage} = \left(\frac{\text{day 1 wound surface} - \text{day } x \text{ wound surface}}{\text{day 1 wound surface}} \right) \times 100$$

2.5. Histopathological examination

Samples were collected from the wound bed and surrounding healthy skin and underwent hematoxylin-eosin and Masson trichrome staining for microscopic evaluation using an Olympus CX31 binocular microscope (Tokyo, Japan). A histopathological examination was conducted on days 4, 7, and 14 to ascertain the histopathological characteristics, including the number of fibroblasts, vessels, and inflammatory cells. This was facilitated by the Image J application (Digital Image Processing for Medical Applications, Image J 1.46r, Java 1.6.0-20, Cambridge University). Additionally, the re-epithelization score, collagen deposition amount, and inflammation status were documented on day 14 in accordance with Abramov's histological scoring system for wound repair (21) (Table 1).

2.6. Data analysis

The statistical analyses and graphical representations were conducted using the SPSS software, version 25, and Prism 8.0. The quantitative data were expressed as mean \pm standard deviation (SD). The analysis of variance (ANOVA) test was employed to ascertain whether there were significant differences between the groups. To compare quantitative outcomes between the two study groups, either the independent t-test or its nonparametric equivalent, the Mann-Whitney test, was employed. A statistical significance level of $P < 0.05$ was employed.

3. Results

The histopathological examinations and ANOVA test analyses revealed a significant difference in the numbers of wound inflammatory cells, fibroblasts, and vessels between the study groups on days 4, 7, and 14 (Table 2). Additionally, post-hoc tests were conducted to perform pairwise comparisons (Figure 1). The M. Piperita + clinoptilolite group demonstrated a statistically significant increase in the number of fibroblasts and vessels, accompanied by a reduction in the inflammatory cell count, when compared to the control group within the wound site on all experimental days ($P < 0.001$). Furthermore, the M. Piperita + clinoptilolite group exhibited a statistically significantly higher number of fibroblasts and vessels and a lower number of inflammatory cells compared to all other experimental groups on all study days for fibroblasts and inflammatory cells, and on days 7 and 14 for vessels ($P < 0.001$). On day 14, the mean \pm SD of the combined group's inflammatory cells was reduced to 2.75 ± 0.95 , whereas the control group exhibited a mean \pm SD of 19.5 ± 1.29 . The number of vessels was observed to increase until day 7 in all groups, after which a decrease was noted on day 14. On day 7, the combined group exhibited the greatest increase in vessel number (36.75 ± 1.5), while the control group demonstrated a value approximately half that amount (18 ± 0.81). The calculated scores for re-epithelization, collagen deposition, and inflammation (using Abramov's histological scoring system) demonstrated statistically significant differences between the intervention groups and the control group (Figure 2). On the 14th day, the re-epithelialization and collagen deposition scores were significantly higher in all intervention groups than in the control group ($P < 0.05$). A comparison of the re-epithelialization scores with the control group in the combined group revealed a more significant outcome than in the other comparisons ($P < 0.01$). A reduction in the level of inflammation was observed in all intervention groups in comparison to the control group, although this was not statistically significant (Figure 2).

Table 1. Abramov's histological scoring system for wound repair.

Parameter	Score			
	0	1	2	3
Acute inflammation	None	Scant	Moderate	Abundant
Chronic inflammation	None	Scant	Moderate	Abundant
Amount of granulation tissue	None	Scant	Moderate	Abundant
Granulation tissue maturation	Immature	Mild maturation	Moderate maturation	Fully matured
Collagen deposition	None	Scant	Moderate	Abundant
Re-epithelialization	None	Partial	Complete but immature or thin	Complete and mature
Neovascularization	None	Up to five vessels per	6 to 10 vessels per HPF	More than 10 vessels per HPF

Table 2. Microscopic examination of wounds' histological parameters (fibroblasts, vessels, and inflammatory cell numbers) in the study groups on different days using Mean ± SD and ANOVA test.

Groups	Days	Day 4 Mean ± SD	Day 7 Mean ± SD	Day 14 Mean ± SD
	Parameters			
Control	Fibroblasts	62/25 ± 1/70	101 ± 1/41	101 ± 0/81
	New vessels	5/25 ± 0/95	18 ± 0/81	14/5 ± 0/57
	Inflammatory cells	46/75 ± 1/25	31/25 ± 1/70	19/5 ± 1/29
Clinoptilolite	Fibroblasts	84 ± 0/81	158 ± 0/81	133/5 ± 1/29
	New vessels	12 ± 1/41	28 ± 0/81	22/75 ± 2/21
	Inflammatory cells	22 ± 0/81	16/75 ± 1/5	8 ± 0/81
Mentha Piperita	Fibroblasts	78/5 ± 1/29	145/25 ± 0/5	124/5 ± 1/29
	New vessels	8/75 ± 0/5	24 ± 0/81	17/75 ± 0/95
	Inflammatory cells	21 ± 0/81	15 ± 0/81	7 ± 0/81
Mentha Piperita + Clinoptilolite	Fibroblasts	102/5 ± 1/29	186/75 ± 1/89	167/25 ± 1/5
	New vessels	2/38	36/75 ± 1/5	28/5 ± 0/57
	Inflammatory cells	12/75 ± 1/5	7/75 ± 1/70	2/75 ± 0/95
Phenytoin	Fibroblasts	78 ± 2/16	147/25 ± 1/25	122/25 ± 2/21
	New vessels	8/5 ± 0/57	22/75 ± 0/95	16 ± 0/81
	Inflammatory cells	23/75 ± 1/70	16 ± 1/82	6/75 ± 0/95
ANOVA p value	Fibroblasts	<0/001	<0/001	<0/001
	New vessels	<0/001	<0/001	<0/001
	Inflammatory cells	<0/001	<0/001	<0/001

Respectively. (*&= (P<0.05), **= (P<0.01), &&&= (P<0.001), ****/&&&&= (P<0.0001))

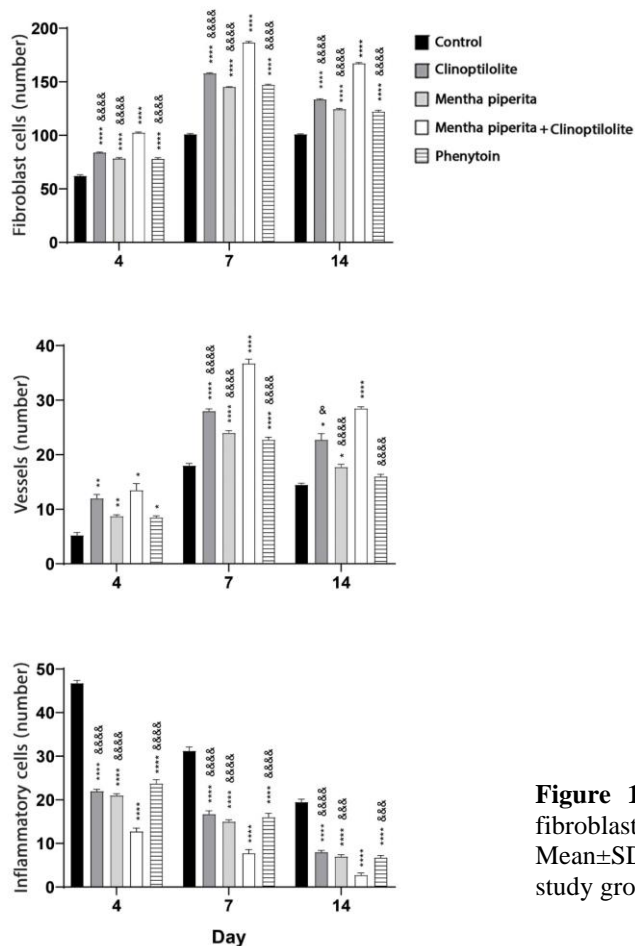


Figure 1. The comparison of numbers of inflammatory cells, vessels, and fibroblasts between different study groups. The columns are provided as Mean±SD for each group. * and & signs are indicated the comparison between the study group and the control group or the M. Piperita + clinoptilolite group,

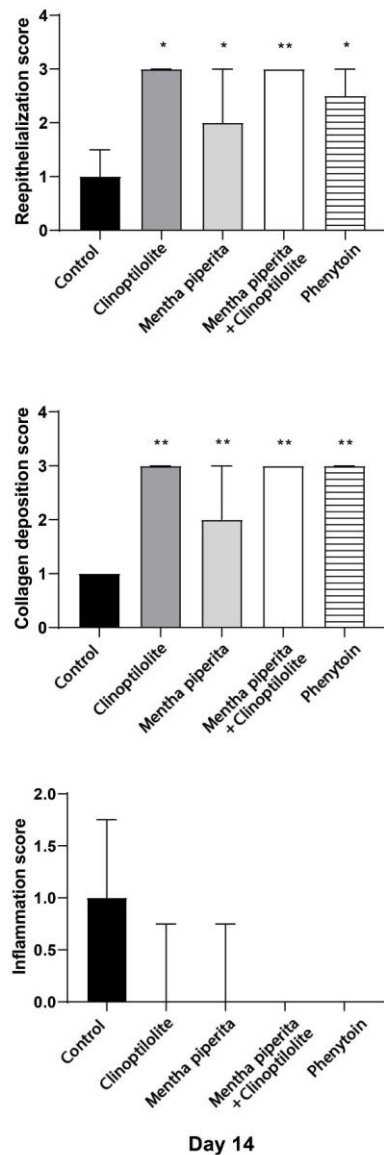


Figure 2. The comparison of re-epithelialization score, collagen deposition score, and inflammation score between different study groups. The columns are expressed as median (IQR). * is used to show significant differences between study group and the control group. (*= (P<0.05), **=(P<0.01))

The ANOVA test revealed significant differences in recovery percentage and wound surface results between the study groups ($P < 0.001$). In this regard, the M. Piperita + clinoptilolite group exhibited a significantly higher percentage of wound healing ($99.75 \pm 0.5\%$) on day 14 compared to the control group ($52.5 \pm 1.29\%$). Indeed, all groups exhibited significantly accelerated healing and a reduced wound surface area compared to the control group ($P < 0.0001$). The M. Piperita + Clinoptilolite group demonstrated superior outcomes in this regard. The M. Piperita + clinoptilolite intervention group demonstrated the most pronounced reduction in wound surface area, reaching

0.00 ± 0.00 on day 14 (Table 3). A post-hoc analysis also demonstrated a statistically significant difference between the M. Piperita + clinoptilolite group and all other intervention groups with regard to wound surface and recovery on all experimental days ($P < 0.0001$) (Figure 3 and 4).

4. Discussion

The objective of this study was to demonstrate the synergistic effects of the M. Piperita extract and clinoptilolite on the wound healing process, with a particular focus on histopathologic features and clinical outcomes. To this end, the effects of combining M. Piperita and clinoptilolite were compared to those of using M. Piperita and clinoptilolite alone, phenytoin, and a control group. The findings of our research indicate that the combination of M. Piperita and clinoptilolite can mitigate inflammation while also facilitating fibroblast proliferation, angiogenesis, re-epithelialization, and collagen deposition at the wound site. This results in an enhanced wound repair rate and a reduction in wound surface area when compared to other interventions. The inflammatory response represents a pivotal element in the wound healing process, as it is instrumental in combating infection and averting tissue injury and septicemia. However, in addition to this function, inflammatory cells can also impede the completion of the wound healing process. Indeed, an excess of inflammatory cells in the subsequent days can have a detrimental impact on the wound healing process (22). Our research indicates that the usage of M. Piperita + clinoptilolite can attenuate inflammation, as evidenced by a notable reduction in the number of inflammatory cells. While this was also observed in other intervention groups, the combination of M. Piperita and clinoptilolite resulted in a more pronounced reduction in inflammation (Figure 1). The results for the inflammation score were similar, although not statistically significant (Figure 2). The present study revealed that the number of inflammatory cells in the clinoptilolite and M. Piperita groups did not differ significantly in any of the time periods, despite the observed synergistic effect of the M. Piperita Linn and clinoptilolite combination in accelerating the reduction of inflammation. These findings are consistent with those of previous research studies that demonstrate the effects of M. Piperita or clinoptilolite in modulating wound inflammation. Zanganeh et al. conducted an in vivo study on rats, which demonstrated that a M. Piperita aqueous extract ointment resulted in a notable reduction in wound size. Furthermore, the study demonstrated a reduction in total cells, neutrophils, lymphocytes, and macrophages, accompanied by an increase in wound contracture due to the aforementioned therapy (2). Furthermore, the topical and high-dose application of M. piperita may potentially reduce the inflammatory stage and accelerate the wound healing process, as observed in the study by Modarresi et al. which investigated the effects of this treatment on infected wounds caused by *S. aureus* and *P. aeruginosa* bacteria strains.

Table 3: Comparison of wound surface and healing percentage on different study days regarding calculated Mean \pm SD for each group and ANOVA test

Groups	Days	Day 4 Mean \pm SD	Day 7 Mean \pm SD	Day 10 Mean \pm SD	Day 14 Mean \pm SD
	Parameters				
Control	Wound surface	0.96 \pm 0.00	0.88 \pm 0.00	0.68 \pm 0.00	0.47 \pm 0.01
	Wound recovery (%)	4 \pm 0.81	11.25 \pm 0.15	31.25 \pm 0.15	52.5 \pm 1.29
Clinoptilolite	Wound surface	0.74 \pm 0.00	0.65 \pm 0.01	0.48 \pm 0.00	0.10 \pm 0.00
	Wound recovery (%)	25.25 \pm 0.15	34.75 \pm 1.25	51.75 \pm 0.95	89.5 \pm 0.57
Mentha Piperita	Wound surface	0.76 \pm 0.00	0.69 \pm 0.00	0.51 \pm 0.00	0.12 \pm 0.01
	Wound recovery (%)	23.25 \pm 0.15	30.25 \pm 0.95	48.25 \pm 0.15	87.75 \pm 1.25
Mentha Piperita + Clinoptilolite	Wound surface	0.61 \pm 0.95	0.56 \pm 0.95	0.34 \pm 0.95	0.00 \pm 0.00
	Wound recovery (%)	38.5 \pm 1.29	42.5 \pm 2.08	65.25 \pm 0.15	99.75 \pm 0.15
Phenytoin	Wound surface	0.77 \pm 0.00	0.70 \pm 0.00	0.54 \pm 0.00	0.15 \pm 0.00
	Wound recovery (%)	22.25 \pm 0.15	29.75 \pm 0.15	45.25 \pm 0.95	84.5 \pm 0.57
ANOVA p value	Wound surface	<0.001	<0.001	<0.001	<0.001
	Wound recovery (%)	<0.001	<0.001	<0.001	<0.001

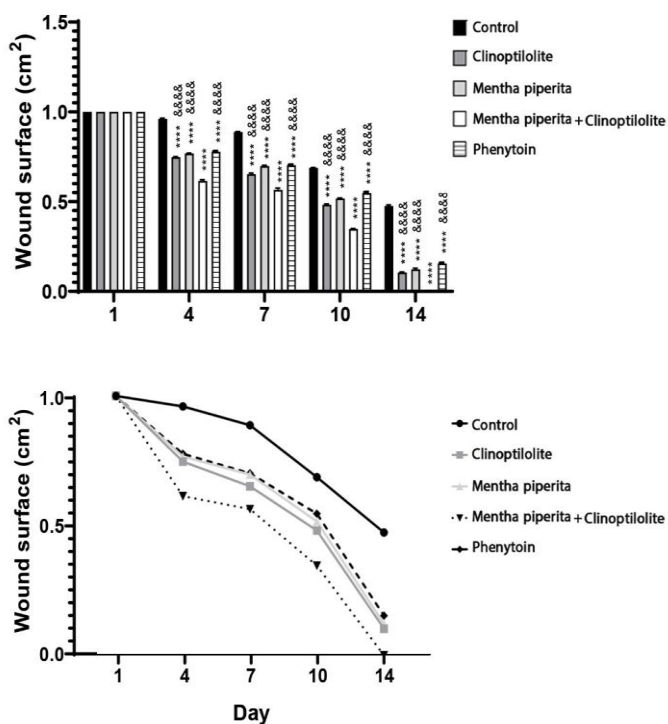


Figure 3. Wound surface evaluation. * and & indicate a significant difference between study group and the control group or the M. Piperita + clinoptilolite group, respectively (**** or &&&&= (P<0.0001).

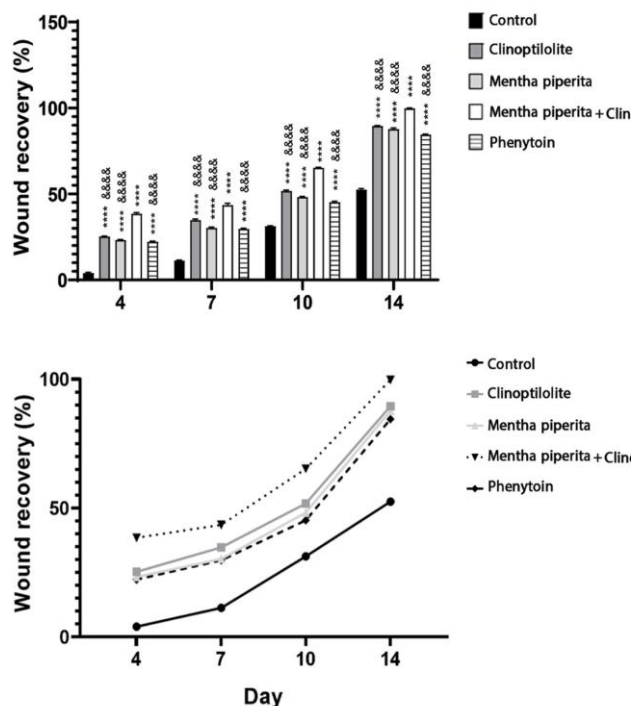


Figure 4. Healing percentage evaluation. * and & indicate a significant difference between study group and the control group or the M. Piperita + clinoptilolite group, respectively (**** or &&&&= (P<0.0001).

Topical application of *M. Piperita* has demonstrated efficacy in pathological and molecular phases (16). In the study by Javanmardi et al., the Zeolite-Ag/gelatin nanocomposite group exhibited a reduction in inflammatory cells, in addition to increased levels of angiogenesis, fibroblasts, and collagen fibres, in comparison to the control group. This indicates the capacity of nanocomposites to influence various parameters associated with wound healing. Angiogenesis plays a pivotal role in the restoration of hemostasis and the reestablishment of normal skin function. As a typical aspect of the wound healing process, the number of vessels initially increases and subsequently decreases due to the anticipated apoptosis (24). The present study observed the presence of this pathway in all experimental groups. Conversely, the combination of *M. Piperita* and clinoptilolite demonstrated superior angiogenic potential, exhibiting a significantly higher number of blood vessels on days 7 and 14 compared to the other groups (Figure 1). The re-epithelialization and collagen deposition scores on day 14 for the *M. Piperita* + clinoptilolite group were equivalent to those of the clinoptilolite group and surpassed those of the *Mentha* and phenytoin groups. However, the aforementioned differences were not statistically significant (Figure 2). The re-epithelialization process is regarded as a pivotal aspect of the wound healing cascade, as it establishes a protective barrier and creates an optimal environment for the subsequent stages of wound repair (25, 26). In the present study, the mean score for epithelialization in all groups was significantly higher than that observed in the control group. Nevertheless, no statistically significant difference was observed between the *M. Piperita* + clinoptilolite group and the other groups. These findings indicate that the combination of the two substances does not exert a notable synergistic effect on the re-epithelialization score. However, each of these compounds demonstrated an acceptable score for wound healing when administered individually. Additionally, no notable discrepancy was observed between the experimental groups with respect to the collagen deposition score. This indicates that the two compounds are not markedly superior to each other in terms of collagen deposition and do not exert a significant influence on one another. The number of fibroblasts was significantly higher in the *M. Piperita* + clinoptilolite group than in the other groups throughout the observation period. Fibroblasts synthesize collagen, facilitate the repair of the external matrix, and play a role in the process of wound contraction. One method of facilitating wound healing is the use of fibroblast growth stimulants. Furthermore, Zangeneh and colleagues demonstrated an elevated ratio of fibrocytes to fibroblasts following *M. Piperita* administration (2). Additionally, *M. Piperita* has demonstrated favorable outcomes in augmenting fibroblast infiltration, collagen deposition, and re-epithelialization in treated animals, as evidenced by the findings of the Modarresi et al. study (16). The combined product demonstrated notable effects at the

histopathological level, which were also evident in the clinical features. Indeed, the combination of *M. Piperita* and clinoptilolite has been demonstrated to expedite the reparative process, resulting in a notable reduction in wound size (Figure 3). Furthermore, other studies have corroborated the effects of either *M. Piperita* or clinoptilolite in accelerating wound healing. For example, the survey conducted by Amirzade-Iranaq and colleagues indicated that *M. Piperita* essence can promote wound healing and reduce wound size. The elevation of transforming growth factor (TGF)- β expression has been demonstrated to be a crucial element in this process. The essence has been demonstrated to stimulate the release of growth factors and create an optimal environment at the site of the wound. Furthermore, it has demonstrated antibacterial properties, which facilitate the control of skin infections, in addition to its established capacity for wound repair, including the promotion of angiogenesis and fibroblast proliferation (27). Boukeloua and colleagues additionally sought to demonstrate the efficacy of the daily application of *M. piperita* L. fatty oil in promoting wound healing. In this regard, the results demonstrated a statistically significant improvement ($p \leq 0.05$) in the healing rate and surgical wound contraction of rabbits, in addition to the promotion of hemostasis and the inflammatory phases of cicatrization. The efficacy of this product for wound healing is thought to be due to the synergistic effect of its fatty acids (28). Additionally, Algerian peppermint essential oil (PEO) was examined by Kehili et al. and demonstrated efficacy in inhibiting inflammatory responses and reducing wound size between days 6 and 9 of treatment (11). Furthermore, Hubner and colleagues have demonstrated the potential wound-healing effects and antimicrobial properties of gelatin/c clinoptilolite-Ag films (29). Additionally, natural zeolite granules from Jinyun, China (NZG-JY), which are primarily composed of clinoptilolite, have been demonstrated to enhance wound healing to a greater extent than synthetic zeolite products (20). *M. Piperita* extract and clinoptilolite bio-complex as natural products have demonstrated promising outcomes in facilitating wound healing, as evidenced by their distinctive characteristics and impacts on diverse wound healing constituents across multiple studies (11,16,29). Nevertheless, further investigation is required to ascertain the efficacy of these products in the treatment of diverse wound types on a larger scale, as well as in human clinical trials. Furthermore, the potential adverse effects and long-term complications associated with their use should be addressed. Furthermore, the results of our study indicate that the combination of these products may significantly enhance the wound healing process. Nevertheless, the paucity of research in this field necessitates further investigation.

Abbreviations

ANOVA: Analysis of Variance; NZG-JY: natural zeolite granules from Jinyun, China; PEO: Peppermint Essential

Oil; SD: Standard Deviation; TGF- β : Transforming Growth Factor

Acknowledgment

None

Authors' Contribution

Study concept and design: M. G. and Mr. Gh.
Conducting the experiment: M.G and P.P. and N. T.
Analysis and interpretation of data: M. G. and P. P.
Drafting of the manuscript: Mr. Gh and P. P.
Critical revision of the manuscript: M. G. and P. P and N. T.

Ethics

All experiments were conducted in accordance with the ethical standards set forth by the Tehran University of Medical Sciences Ethics Committee. The authors have indicated that they have obtained approval from the relevant institutional review board or otherwise adhered to the principles set forth in the Declaration of Helsinki for all experiments. The authors have observed the highest standards of ethical conduct in their work, including adherence to principles of academic integrity, such as those pertaining to plagiarism, informed consent, scientific misconduct, data fabrication and falsification, double publication and submission, redundancy, and other pertinent issues.

Conflict of Interest

The authors declare that there is no conflict of interest.

Funding

This study was funded by Tehran University of Medical Sciences.

Data Availability

The data that support the findings of this study are available on request from the corresponding author.

References

- Guo S, Dipietro LA. Factors affecting wound healing. *Journal of dental research*. 2010;89(3):219-29.
- Zangeneh MM, Zangeneh A, Moradi R, Seydi N. Pharmacological, biochemical, and histopathological evaluations of cutaneous wound healing property of *Mentha piperita* aqueous extract ointment. *Comparative Clinical Pathology*. 2019;28(4):1181-90.
- Mulkalwar S, Behera L, Golande P, Shah A. Evaluation of Wound Healing Activity of Topical Phenytoin in an Incision Wound Model in Rats. 2015.
- Ahmadnejad M, Tolouei M, Jarolmasjed SH, Rafinejad J. Evaluation of Maggot Therapy Effects on the Progression of Equine Sarcoid. *Iranian Journal of Veterinary Medicine*. 2022;16(1).
- Al-AHAOM, Iraqi LMA. The Effect of Autogenous Peritoneal Graft Augmented with Platelets-Plasma Rich Protein on the Healing of Induced Achilles Tendon Rupture, in Dogs. *Iranian Journal of Veterinary Medicine*. 2020;14(2).
- Takzaree N, Hadjiakhondi A, Hassanzadeh G, Rouini MR, Manayi A. Synergistic effect of honey and propolis on cutaneous wound healing in rats. 2016.
- McDermott K, Fang M, Boulton AJ, Selvin E, Hicks CW. Etiology, epidemiology, and disparities in the burden of diabetic foot ulcers. *Diabetes Care*. 2023;46(1):209-21.
- Amirzade-Iraniq MH, Tajik M, Takzaree A, Amirmohammadi M, Rezaei Yazdi F, Takzaree N. Topical *Mentha piperita* Effects on Cutaneous Wound Healing: A Study on TGF- β Expression and Clinical Outcomes. *World journal of plastic surgery*. 2022;11(1):86-96.
- DesJardins-Park HE, Gurtner GC, Wan DC, Longaker MT. From chronic wounds to scarring: the growing health care burden of under-and over-healing wounds. *Advances in Wound Care*. 2022;11(9):496-510.
- Khodabakhshi Rad A, Kazemi Mehrjerdi H, Pedram MS, Azizzadeh M, Amanollahi S. Clinical Evaluation of the effect of Methylprednisolone Sodium Succinate and Meloxicam in Experimental Acute Spinal Cord Injury. *Iranian Journal of Veterinary Medicine*. 2023;17(2):129-38.
- Kehili S, Boukhatem MN, Belkadi A, Ferhat MA, Setzer WN. Peppermint (*Mentha piperita* L.) essential oil as a potent anti-inflammatory, wound healing and anti-nociceptive drug. *European Journal of Biological Research*. 2020;10(2):132-49.
- Singh R, Shushni MAM, Belkheir A. Antibacterial and antioxidant activities of *Mentha piperita* L. *Arabian Journal of Chemistry*. 2015;8(3):322-8.
- Trevisan SCC, Menezes APP, Barbalho SM, Guiguer ÉL. Properties of *mentha piperita*: a brief review. *World J Pharm Med Res*. 2017;3(1):309-13.
- Balakrishnan A. Therapeutic uses of peppermint-a review. *Journal of pharmaceutical sciences and research*. 2015;7(7):474.
- Mojally M, Sharmin E, Alhindi Y, Obaid NA, Almaimani R, Althubiti M, et al. Hydrogel films of methanolic *Mentha piperita* extract and silver nanoparticles enhance wound healing in rats with diabetes Type I. *Journal of Taibah University for Science*. 2022;16(1):308-16.
- Modarresi M, Farahpour M-R, Baradaran B. Topical application of *Mentha piperita* essential oil accelerates wound healing in infected mice model. *Inflammopharmacology*. 2019;27(3):531-7.
- Kraljević Pavelić S, Simović Medica J, Gumbarević D, Filošević A, Pržulj N, Pavelić K. Critical Review on Zeolite Clinoptilolite Safety and Medical Applications in vivo. *Frontiers in Pharmacology*. 2018;9.
- Zarrantaj P, Mahmodi G, Manouchehri S, Mashhadzadeh AH, Khodadadi M, Servatan M, et al. Zeolite in tissue engineering: Opportunities and challenges. *MedComm*. 2020;1(1):5-34.
- Hubner P, Donati N, Quines LKdM, Tessaro IC, Marcilio NR. Gelatin-based films containing clinoptilolite-Ag for application as wound dressing. *Materials Science and Engineering: C*. 2020;107:110215.

20. Li Y, Li H, Xiao L, Zhou L, Shentu J, Zhang X, Fan J. Hemostatic efficiency and wound healing properties of natural zeolite granules in a lethal rabbit model of complex groin injury. *Materials*. 2012;5(12):2586-96.
21. Abramov Y, Golden B, Sullivan M, Botros SM, Miller JJ, Alshahrour A, et al. Histologic characterization of vaginal vs. abdominal surgical wound healing in a rabbit model. *Wound repair and regeneration : official publication of the Wound Healing Society [and] the European Tissue Repair Society*. 2007;15(1):80-6.
22. Martin P, Leibovich SJ. Inflammatory cells during wound repair: the good, the bad and the ugly. *Trends in Cell Biology*. 2005;15(11):599-607.
23. Javanmardi S, Moradi Arzlou M, Jarolmasjed SH. Healing effects of ion-exchanged zeolite nanocomposite on third-degree burn wound in mice. *Studies in Medical Sciences*. 2017;28(9):548-59.
24. Baum CL, Arpey CJ. Normal cutaneous wound healing: clinical correlation with cellular and molecular events. *Dermatologic surgery*. 2005;31(6):674-86.
25. Ousey K, Cutting K, Rogers AA, Rippon MG. The importance of hydration in wound healing: reinvigorating the clinical perspective. *Journal of wound care*. 2016;25(3):122-30.
26. Javadi SR, Afshar FS, Dehghan MM, Masoudifard M, Baghbaderani ET, Rabiei J, Banani S. Effects of Pulsed Electromagnetic Field as a Supplement to Topical Dimethyl Sulfoxide and Controlled Exercise in Treatment of Equine SDF Tendonitis. *Iranian Journal of Veterinary Medicine*. 2021;15(2).
27. Amirzade-Iranaq MH, Tajik M, Takzaree A, Amirmohammadi M, Yazdi FR, Takzaree N. Topical Mentha piperita Effects on Cutaneous Wound Healing: A Study on TGF- β Expression and Clinical Outcomes. *World journal of plastic surgery*. 2022;11(1):86.
28. Boukeloua A, Yilmaz MA, Temel H. Effect of Mentha piperita L. fatty oil on full thickness excised wound healing in rabbits. *Int J Biosci*. 2017;11:68-74.
29. Hubner P, Donati N, de Menezes Quines LK, Tessaro IC, Marcilio NR. Gelatin-based films containing clinoptilolite-Ag for application as wound dressing. *Materials Science and Engineering: C*. 2020;107:110215.