



Mini Review

Human Monkey Pox- Dental Implications and Public Health Emergency

Queen Alice Arul^{1*}, Rakshagan V², Padmapriya Mahalingam³, Dipanjan Debnath¹

1. Department of Dentistry, AIIMS (All India Institute of Medical Sciences), Kalyani, West Bengal.

2. Department of Prosthodontics, Saveetha Dental College, Chennai, Tamil Nadu, India.

3. Department of Conservative Dentistry & Endodontics, Government Dental College, Chennai, Tamil Nadu, India.

Article Info:

Received: 3 August 2024

Revised: 1 September 2024

Accepted: 3 September 2024

Keywords:

Monkeypox, Dental Practice,
Infection Control,
Public Health Emergency,
Non- endemic outbreak.

ABSTRACT

A viral disease that is mostly limited to African area is monkey pox (MPX). However, it has recently re-emerged in several places outside of nations where the disease is prevalent. Humans may acquire the virus through contact with infected individuals, contaminated materials, or diseased animals. Symptoms include fever, headache, and enlarged lymph nodes, followed by the development of painful skin sores. Typically, monkey pox is a self-limiting illness that gets better on its own without medical intervention. However, It can occasionally be dangerous, especially for those with compromised immune systems. An interprofessional team comprising physicians, nurses, virologists, dentists, veterinarians, and public health specialists who can quickly detect MPX infection in people and animals, implement preventative measures, and start public health reporting builds a strong defense against a potential catastrophic outbreak. An improved patient outcome will be facilitated by the interprofessional paradigm. Infection management in dentistry may face new difficulties as a result of the re-emerging global outbreak of monkey pox. Given the recent spread of MPXV in non-endemic areas where dentists are not accustomed to include this illness in the differential diagnosis, it is now expected that all dental healthcare providers be knowledgeable about the oral signs of MPX. This knowledge is essential for conducting adequate oral screening and implementing the necessary infection control measures within dental practices. As the dental setup is more prone for aerosol cross infection, strict infection control measures have to be followed. In this article we have focussed on the dental implications of MPX disease.

Corresponding Author:

drqueenalice@gmail.com

alice.dental@aiimskalyani.edu.in

<https://orcid.org/0000-0002-4314-2311>

How to cite this article: Arul QA, Rakshagan V, Mahalingam P, Debnath D. Human Monkey Pox- Dental Implications and Public Health Emergency. *Archives of Razi Institute*. 2025;80(3):549-553. DOI:10.66224/ARI.2025.80.3.549



1. Context

World Health Organization has described the spread of the human monkey pox virus (MPXV) as "emerging threat of moderate health concern (1). The high incidence of transmission makes it a serious issue for the healthcare authorities. Due to the potential of cross-infection or occupational contact, dental practitioners may be at risk during an outbreak of the viral infectious disease monkey pox. From the lessons we learnt from COVID-19 pandemic, the health care professionals need to be very cautious. As a result, we cannot overlook the re-emergence of monkey pox. Because dentists work closely with patients, they have the responsibility to watch for early symptoms in order to control the spread of the disease. Aerosols are commonly produced during dental procedures, making infection transmission more likely. The Centre for Disease Control and Prevention promote stringent airborne infection control protocols due to the risk of airborne transmission. It is also potentially important in dental settings to be aware that monkey pox can spread through close contact with an infected individual, contaminated objects and surfaces, droplets and possibly aerosols. This article addresses the importance of awareness of monkey pox infection among dental practitioners, as well as how it might affect infection prevention and control procedures and dental service delivery.

2. Evidence Acquisition

The double-stranded DNA virus MPXV, which is a member of the Poxviridae family and the genus Orthopoxvirus, is the causative agent of this zoonotic viral disease. This genus also includes the Variola virus, responsible for smallpox. This infection belongs to Hazard Group 3 and should only be treated in specialized facilities (2). MPXV is believed to have its natural reservoirs in small rodents and other species native to Central Africa (3). The main entry and inoculation sites are the nasopharynx, oropharynx, and damaged skin. The majority of the way that the virus spreads occurs through direct touch or secretions with infected patients, contaminated objects, animals, and respiratory droplets. The first report of a pox-like illness in confined monkeys in 1958 served as the basis for the virus's name (4). Historically, MPXV has been divided into two clades, genotypically separate groups, named after the region where they were initially discovered (5).

Modes of Spread

Figure 1 Modes of spread of monkeypox virus (6-8). The different modes of spread are shown in Figure 1. In the past, cases with limited human-to-human transmission, both inside and outside of these regions, were documented after interaction with infected animals in Central and West Africa. However, the rapid emergence of MPX among people who are not necessarily connected or who have not travelled to Africa in several cities outside of the virus's endemic region-coupled with recent evidence suggesting person-to-person transmission,-has been a major concern for many health authorities (9).

It is a self-limiting illness with a fatality rate of 3–6% and symptoms typically last for two to four weeks (10). This infectious condition affects the skin and soft tissues, including the oral cavity, and is characterized by a rash. An ulcerative rash on the tongue or other oral mucosal surfaces is frequently the first sign, as shown in Figure 2 (11). It has been shown to induce intraoral lesions on the tongue, cheeks, palate, gums, and even the neck. These lesions can have a wide range of characteristics just similar to their external counterparts. Additionally, only the prodromal or acute phase is considered infectious for MPX-positive individuals. While there is currently no vaccine for MPX, the smallpox vaccine that seems to be effective. Therefore, awareness must be raised among dental health care providers, who are expected to have knowledge about this relatively new threat.

3. Results

As a result, the dental care provider community has to be informed about the re-emergence details on MPX symptoms. By asking patients about mouth sores and physically examining the tongue, oral cavity, and cheeks for rashes and lesions, dentists can assist in the diagnosis of monkey pox. The fact that the initial lesions begin in the oropharynx before appearing on the skin is noteworthy from the perspective of dentistry. Periodically, oral ulcers can make it difficult for a patient to eat or drink, which can lead to malnutrition and dehydration (12). The current outbreak was first reported to have perioral papules that blistered and ulcerated (13).

Oral ulcers were found to be present in nearly one-quarter (23.5%) of MPX patients in one study (14, 15). Therefore, dental professionals may be the first to notice MPX's early warning signs in areas where the disease is

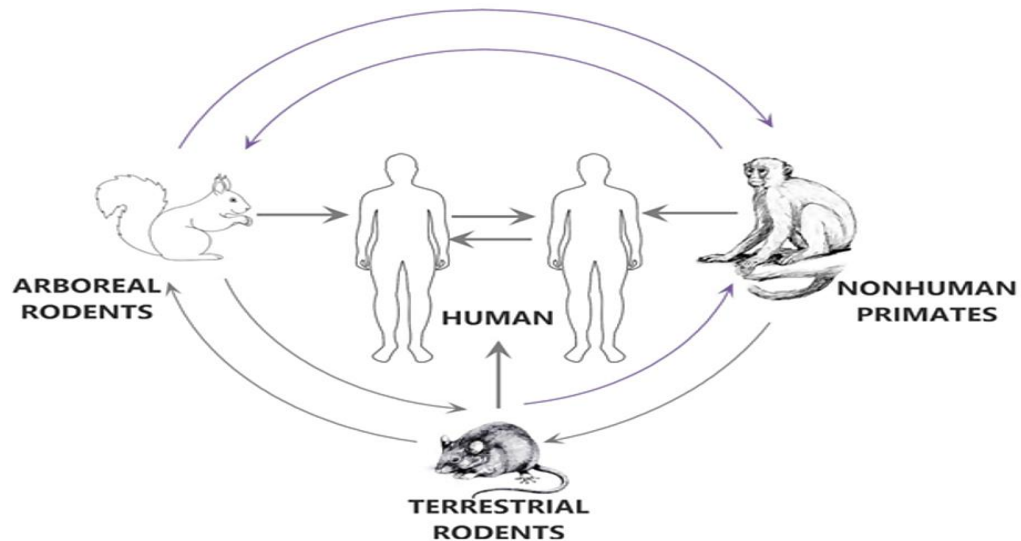


Figure 1. Modes of spread of monkeypox virus.

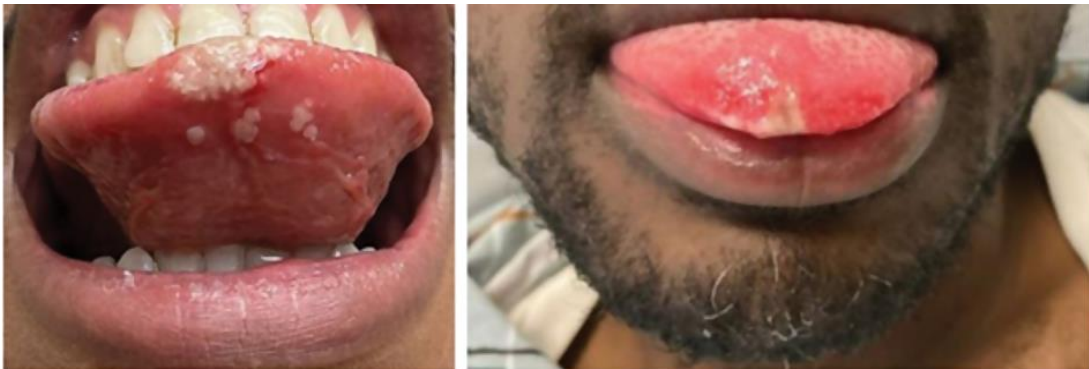

Figure 2. Oral lesions of monkey pox.

- Ventral surface and tip of the tongue affected by confluent vesicular and ulcerated lesions;
- Ulcerated lesion affecting the tip of the tongue with surrounding erythema

(Reprinted from Journal of Oral and Maxillofacial Surgery, Peters et al., 'Oral manifestations of monkeypox: a report of two cases', Copyright 2022, with permission from Elsevier)

endemic. As a result, dental professionals should exercise extreme caution when treating patients with lymphadenopathy, especially if they operate in a region where the condition is common or endemic. Early-stage oral lesions were described in almost 70% of cases with monkey pox, necessitating a differential diagnosis from other oral lesions. Ulcerated lesions are frequently observed on the tonsils, buccal mucosa, and tongue in the oral mucosa (16). The latter could be confused for tonsillitis or other illnesses with ease. Oral mucosal lesions may not proceed in the same way as cutaneous monkey pox lesions, which complicates the differential diagnosis even further. Although the itchy maculopapular lesions of chickenpox are unlikely to be umbilicated, as lesions from monkey pox frequently are, herpes zoster typically presents with a dermatomal distribution of

numerous vesicles that coalesce and crust. Lesions caused by the varicella-zoster virus, including chickenpox and herpes zoster (shingles), may be included in a differential diagnosis.

Similar symptoms can be seen in molluscum contagiosum, a disorder caused by the molluscum contagiosum virus, another member of the Poxviridae family. This virus causes elevated, pink lesions with a central dimple. When oral ulceration is the first symptom to appear, there are a few other possible causes to consider, including traumatic ulceration (11). It is imperative that all patients undergo a comprehensive evaluation of their oral mucosa for macular, papular lesions. The UK Health Security Agency has recommended the following precautions to avoid contracting MPXV infection.

- Strict adherence to standard, contact, and droplet infection control precautions in dentistry is necessary. These precautions include the use of FFP3 respirators, N95 masks, eye protection, and fluid-resistant clothing (17).

- Those who are pregnant or severely immunocompromised should not receive dental care if they are suspected of having an MPX infection.

- Necessary dental care should be postponed until the patient is no longer contagious in cases with probable or confirmed MPX. - Procedures for acute patients requiring emergency dental treatment will be performed in a private room rather than a shared treatment area.

- Adherence to proper hand hygiene procedures is required, such as cleansing with alcohol-containing hand sanitizer or hand washing with soap and water.

- Care should be used when handling towels, hospital gowns, and linens.

- Refrain from touching anything that has come into contact with an MPX patient. Equipment used in patient care needs to be adequately sterilized.

4. Conclusion

The aftereffects of the COVID-19 epidemic are already being felt by the healthcare systems, which are under unnecessary strain due to rising medical costs. More research is necessary to manage the hazards associated with newly and re-emerging viral infectious illnesses in dental settings. It is vitally important that dentistry, wider healthcare and research funding bodies continue to prioritize research into IPC to ensure that services remain resilient in future outbreaks of emerging and re-emerging infectious disease. We urge professional's to take note of the existing guidelines and recommendations. Moreover, it could be necessary to update the current IPC recommendations to maintain their resilience in the event of future viral illness outbreaks. The monkey pox outbreak has highlighted the critical need for reliable evidence to support IPC precautions against both established and newly emergent infectious diseases. Research must continue to ensure we are ready for whatever challenges lie ahead.

Acknowledgment

Not Applicable.

Authors' Contribution

Study concept and design: Q.A.A., R.A.V.

Acquisition of data: P.P.M., D.D.N.

Analysis and interpretation of data: Q.A.A., R.A.V.

Drafting of the manuscript: P.P.M., D.D.N.

Critical revision of the manuscript: Q.A.A., R.A.V.

Ethics

We hereby declare that all ethical standards have been respected in preparation of the submitted article.

Conflict of Interest

All the authors contributed equally in drafting the manuscript and the authors report there are no competing interests to declare.

Funding

Non-funded - The authors did not receive funds from any organization for the submitted work.

Data Availability

The data that support the findings of this study are available on request from the corresponding author.

References

1. Ranganath N, Tosh PK, O'Horo J, Sampathkumar P, Binnicker MJ, Shah AS. Monkeypox 2022: Gearing Up for Another Potential Public Health Crisis. *Mayo Clin Proc.* 2022; 97 (9) : 1694-1699. doi: 10.1016/j.mayocp.2022.07.011.
2. Tian D, Zheng T. Comparison and analysis of biological agent category lists based on biosafety and biodefense. *PloS one.* 2014;9(6):e101163.
3. Doty JB, Malekani JM, Kalemba LsN, Stanley WT, Monroe BP, Nakazawa YU, et al. Assessing monkeypox virus prevalence in small mammals at the human–animal interface in the Democratic Republic of the Congo. *Viruses.* 2017;9(10):283.
4. von Magnus P, Andersen EK, Petersen KB, Birch Andersen A. A pox-like disease in cynomolgus monkeys. 1959.
5. Likos AM, Sammons SA, Olson VA, Frace AM, Li Y, Olsen-Rasmussen M, et al. A tale of two

- clades: monkeypox viruses. *Journal of General Virology*. 2005;86(10):2661-72.
6. Petersen E, Kantele A, Koopmans M, Asogun D, Yinka-Ogunleye A, Ihekweazu C, et al. Human monkeypox: epidemiologic and clinical characteristics, diagnosis, and prevention. *Infectious disease clinics of North America*. 2019;33(4):1027.
 7. Fuller T, Thomassen HA, Mulembakani PM, Johnston SC, Lloyd-Smith JO, Kisalu NK, et al. Using remote sensing to map the risk of human monkeypox virus in the Congo Basin. *EcoHealth*. 2011;8:14-25.
 8. Guagliardo SAJ, Doshi RH, Reynolds MG, Dzabatou-Babeaux A, Ndakala N, Moses C, et al. Do monkeypox exposures vary by ethnicity? Comparison of Aka and Bantu suspected monkeypox cases. *The American journal of tropical medicine and hygiene*. 2019;102(1):202.
 9. Saxena SK, Ansari S, Maurya VK, Kumar S, Jain A, Paweska JT, et al. Re-emerging human monkeypox: a major public-health debacle. *Journal of medical virology*. 2023;95(1):e27902.
 10. Samaranayake L, Anil S. The monkeypox outbreak and implications for dental practice. *International dental journal*. 2022;72(5):589-96.
 11. Peters SM, Hill NB, Halepas S. Oral manifestations of monkeypox: a report of 2 cases. *Journal of Oral and Maxillofacial Surgery*. 2022;80(11):1836.
 12. WHO. Clinical management and infection prevention and control for monkeypox: interim rapid response guidance. <https://www.who.int/publications/i/item/WHO-MPX-Clinical-and-IPC-2022.1>.
 13. Heskin J, Belfield A, Milne C, Brown N, Walters Y, Scott C, et al. Transmission of monkeypox virus through sexual contact—A novel route of infection. *The Journal of infection*. 2022;85(3):334.
 14. Huhn GD, Bauer AM, Yorita K, Graham MB, Sejvar J, Likos A, et al. Clinical characteristics of human monkeypox, and risk factors for severe disease. *Clinical infectious diseases*. 2005;41(12):1742-51.
 15. Sookaromdee P, Wiwanitkit V. Mouth sores and monkeypox: a consideration. *Journal of stomatology, oral and maxillofacial surgery*. 2022;123(6):593.
 16. Thornhill JP, Barkati S, Walmsley S, Rockstroh J, Antinori A, Harrison LB, et al. Monkeypox virus infection in humans across 16 countries—April–June 2022. *New England Journal of Medicine*. 2022;387(8):679-91.
 17. Vivancos R, Anderson C, Blomquist P, Balasegaram S, Bell A, Bishop L, et al. Community transmission of monkeypox in the United Kingdom, April to May 2022. *Eurosurveillance*. 2022;27(22):2200422.