



## Mini Review

# *Echinococcus Granulosus*, a Parasite Producing Hydatid Cyst: A Review

Shahla Hashemi Shahraki<sup>1</sup>, Zahra Salari<sup>2\*</sup>

1. Department of Biology, Faculty of Science, University of Sistan and Baluchestan, Zahedan, Iran.

2. Department of Natural Resources, Baft Branch, Islamic Azad University, Baft, Iran.

### Article Info:

**Received:** 17 May 2024

**Revised:** 7 September 2024

**Accepted:** 8 September 2024

### Keywords:

Definitive Hosts,  
*Echinococcus Granulosus*,  
Hydatid Cysts.

### ABSTRACT

Echinococcosis is a parasitic disease caused by tapeworms of the genus *Echinococcus*, such as *Echinococcus granulosus*. It is characterized by the development of hydatid cysts, which tend to form particularly in the liver and lungs. *Echinococcus granulosus* has a complex life cycle involving dogs as definitive hosts and herbivores such as sheep, as intermediate hosts and can become infected by consuming contaminated food or water contaminated by *Echinococcus* eggs. Hydatid cysts are prevalent in rural areas of Africa, the Mediterranean region, South America, Central Asia, and Eastern Europe, where close contact between humans, dogs, and livestock is common. The clinical symptoms of hydatid cyst disease depend on the location and size of the cysts. Many people with hydatid cysts may have no symptoms for years. However, as the cysts grow, they can cause various symptoms, including abdominal pain, nausea and vomiting, chest pain, coughing, headaches, seizures, vision problems, and shortness of breath. The most effective treatments for hydatid cyst are surgery and chemotherapy. Chemotherapy has adverse side effects, so plants are used for treatment because they have fewer side effects and are safer. If left untreated, a hydatid cyst can lead to serious problems such as organ failure, rupture, and even death. Understanding the epidemiology and life cycle of *Echinococcus granulosus* is crucial for improving diagnosis, treatment, and control measures. This review aims to study *Echinococcus granulosus* to improve diagnosis and treatment and to enhance epidemiological understanding and prevention strategies, thereby reducing the public health impact of cystic echinococcosis.

### Corresponding Author:

zahrasalari1357@yahoo.com

**How to cite this article:** Hashemi Shahraki S, Salari Z. *Echinococcus Granulosus*, a Parasite Producing Hydatid Cyst: A Review. *Archives of Razi Institute*. 2025;80(3):543-548. DOI: 10.66224/ARI.2025.80.3.543

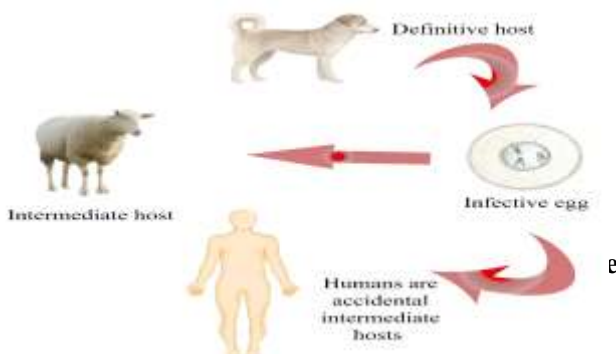


## 1. Introduction

Hydatid cyst disease, also known as cystic echinococcosis, is prevalent in many parts of the world (1). Cystic echinococcosis is a serious zoonotic disease caused by the larval stage of the parasite *Echinococcus granulosus*. *Echinococcus granulosus* has a life cycle in which dogs are the definitive host and sheep, goats or other livestock are the intermediate hosts (2):

- Hydatid cyst disease is especially prevalent in rural, underdeveloped areas where people raise livestock, such as: Africa: Hydatid disease is a major public health concern in many African countries, including those in North Africa, the Horn of Africa, and Southern Africa. Countries with high incidence rates include Morocco, Tunisia, Algeria, Libya, Egypt, Ethiopia, Kenya, and South Africa (3).
- South America: Hydatid disease is endemic in several South American countries, especially Argentina, Peru, Chile, and Uruguay. The disease is associated with the domestic dog-sheep cycle in these regions (4).
- Mediterranean region: Hydatid disease is prevalent in Mediterranean countries such as Spain, Italy, Greece, and Turkey (5).
- Central Asia: Hydatid disease is a significant health problem in Central Asian countries such as Kazakhstan, Kyrgyzstan, Tajikistan, Turkmenistan, and Uzbekistan (6).
- Eastern Europe: Hydatid disease is present in some Eastern European countries such as Romania and Bulgaria (7).

The high incidence of hydatid disease in these regions is linked to the close contact between humans, dogs, and livestock, as well as poor sanitation and hygiene practices. Hydatid cysts cause severe illness and possible death in humans and result in economic losses due to treatment costs, patient disability, and reduced animal product output. Studying hydatid cysts and the *Echinococcus* parasite help us better understand and diagnose cystic echinococcosis, a parasitic disease. This review will focus on hydatid cysts, the parasite that produces them, and their diagnosis, transmission and epidemiology, and prospects for treatment, control and prevention.



**Figure 1.** *Echinococcus granulosus* life cycle.

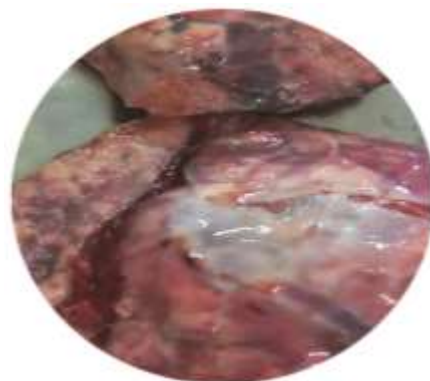
The parasite *Echinococcus granulosus* is a zoonotic tapeworm parasite that primarily infects herbivorous animals such as sheep, goats, and cattle. Its life involves a definitive host, such as dogs and other canids), and an intermediate host, such as sheep and other herbivores (Figure 1). The adult tapeworm resides in the intestine of the definitive host, while larval stages infect intermediate host and develop into hydatid cysts in organs such as the liver and lungs (Figure 2). *Echinococcus granulosus* eggs eventually enter the environment through the host's feces and can survive outside the host for up to two years. Intermediate hosts ingest the egg, and larval stages develop in hydatid cysts. These cysts grow slowly over several months and, if ingested by the definitive host, they can develop into adult tapeworms, completing the life cycle (8). Understanding the epidemiology and life cycle of *Echinococcus granulosus* is important for the following reasons:

1. Improving diagnosis and treatment with specific diagnostic tests and targeted treatment methods.
2. Implement transportation strategies. Identifying high-risk areas and animal sanctuaries allows for the implementation of effective management strategies.
3. Vaccine Development: Identify protective antigens to design effective vaccines for human and animal hosts.
4. Drug Resistance Monitoring: Monitoring the emergence of drug-resistant strains to guide appropriate chemotherapy strategies.
5. Promoting One Health: Achieve integration between human, animal and environmental health, and address this shared disease in humans and animals.

Therefore, The study of hydatid cysts and echinococcosis parasites is an important area of research to address the significant global burden of cystic echinococcosis.

### 2.1. The clinical Symptoms and Pathogen of Hydatid Cyst Disease

The clinical symptoms of hydatid cyst disease depend on the location and size of the cysts. Many people with hydatid cysts may have no symptoms for years because the cysts grow slowly. However, as the cysts grow, they can cause a various symptoms, including:



**Figure 2.** Hydatid cyst of the liver.

- Abdominal pain, nausea and vomiting (if the cysts are in the liver) (9).
- Chest pain, cough, and shortness of breath (if there is a cyst in the lung) (9).
- Neurological symptoms such as headaches, seizures and vision problems (if there are cysts in the brain).
- Allergic reaction and anaphylaxis with cyst rupture (10).

If left untreated, a hydatid cyst can lead to serious complications, including organ failure, rupture, and even death. Early diagnosis and appropriate treatment, which may include a combination of surgery, medication and other interventions, are essential for controlling this viral disease (11, 12).

### 2.2. Prevention of Hydatid Cyst Disease

Preventing hydatid cyst disease involves disrupting the life cycle of *Echinococcus granulosus*. The main preventive measures are:

- Bathe the dog regularly with tapeworm medication to remove adult tapeworms from the intestines.
- Limit dogs' access to raw or infected livestock carcasses to avoid ingesting parasites (13).
- Dispose of contaminated animal parts by burning or deep burial.
- Educate people, especially those in rural areas, about the importance of good hygiene, such as washing hands before eating and after handling animals.
- Improve sanitation and access to clean water in affected areas. Implement monitoring and control program of hydatid disease in livestock (14).

### 2.3. Treatment of Hydatid Cyst Disease

The treatment of hydatid cyst disease involves various methods, each with its own advantages and limitations. The most appropriate treatment depends on factors such as the cyst's size and location, the patient's overall health, and the availability of medical resources. The treatment of hydatid cyst disease involves various methods, each with its own advantages and limitations. The most appropriate treatment depends on factors such as the cyst's size and location, the patient's overall health, and the availability of medical resources.

### 2.4. Surgical Options

Surgical treatment is considered the most effective method for removing hydatid cysts. There are two types of surgery: radical, where the entire cyst and surrounding tissue are removed, or conservative, where only the affected organ is partially resected, if possible (15). Surgical treatment is considered the most effective method for removing hydatid cysts. There are two types of surgery: radical, where the entire cyst and surrounding tissue are removed; and conservative, where only the affected organ is partially resected, if possible. Compared to conservative surgery, radical surgery is considered a better treatment

method for hydatid cysts. This conclusion is based on the results of various studies comparing the outcomes of radical and conservative surgical interventions for liver hydatid disease. Radical surgery involves completely removing the cyst and surrounding tissue. This significantly reduces the risk of postoperative recurrence. In contrast, conservative surgery, which involves partial resection or drainage of the cyst, has been associated with higher rates of complications and recurrence. While conservative surgery may be a good choice in some cases, such as when the cyst is located in a sensitive location or the patient is seriously ill, radical surgery is generally more effective in preventing postoperative recurrence and providing timely treatment (16).

### 2.5. Percutaneous intervention (PAIR)

Percutaneous intervention, also known as PAIR, is a minimally invasive procedure. It involves removing the cyst using a needle inserted into the skin. This is often combined with albendazole therapy to prevent recurrence of the cyst (16, 17).

### 2.6. Chemotherapy

Chemotherapy using albendazole or mebendazole is another treatment option. These medications effectively reduce the size of the cysts and can be used in combination with PAIR or as a standalone treatment. However, the efficacy of chemotherapy alone is not very effective, so it is often used in conjunction with other methods (18).

### 2.7. Watch and Wait Approach

In some cases, hydatid cysts are inactive and cause no symptoms. In these cases, a "watch and wait" approach is often recommended, which involves monitoring the cyst for signs of activity or growth. This method is usually used for static cysts that are not problematic (19). Generally, the most effective method for treating cystic disease is surgical removal of the cyst. However, if surgery is not possible or if the cyst is located in a sensitive area, percutaneous drainage and chemotherapy using albendazole or mebendazole may be recommended. In humans, these drugs must be taken in high doses and for a long time, and they have undesirable side effects. Given these facts, it is crucial to develop new drugs that are more effective and have fewer side effects for treating hydatid cysts. For this reason, identifying and preparing effective, side-effect-free drugs, such as medicinal plants, for the treatment of hydatid cysts is important.

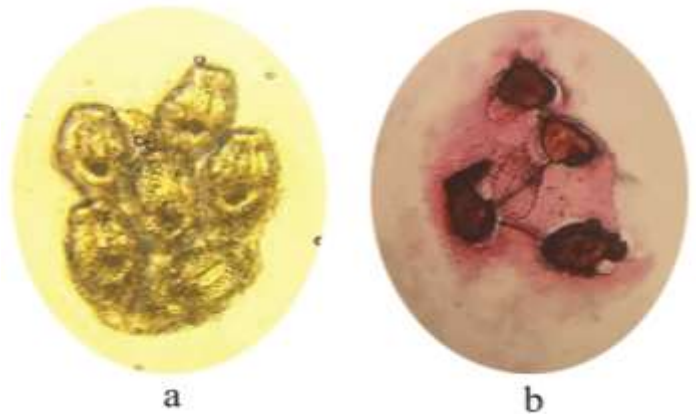
### 2.8. Scolicidal Effects of Plant Extracts

In recent decades, scientists have searched for new, safe and effective scolicidal agents to inactivate the contents of cysts. Recently, studying the antiparasitic activity of medicinal plants has become a popular research topic. Studies have demonstrated the potent scolicidal

properties of various plants including *Eucalyptus microtheca* (20), *Myrtus communis* (21), *Sideritis perfoliata* (22), *Sambucus ebulus* (23), *Zingiber officinale* (24). The hydroalcoholic extract of Pistachio Atlantica fruits exhibited strong scolocidal activity in laboratory tests (25). Phytochemical analysis of the plant extracts showed the revealed of various bioactive compounds like flavonoids, alkaloids, tannins, and terpenoids. These phytochemicals appear to be responsible for the anti-protoscolices (anti-hydatid cyst) effects of the plant extracts. The mechanisms by which these plant extracts kill the protoscolices are not fully understood but may involve membranes disruption, enzymatic activities inhibition, and oxidative stress induction. The concentration and exposure time of the plant extracts appear to be important factors in determining their scolocidal potency. In summary, the phytochemicals such as alkaloids, flavonoids, and terpenoids, seem to be the key component conferring the anti-hydatid cyst effects observed in these studies (26-29). The mechanisms by which these plant extracts kill protoscolices are not fully understood but may involve membrane disruption, enzymatic activity inhibition, and oxidative stress induction. The concentration and exposure time of the plant extracts appear to be important factors in determining their scolocidal potency. In summary, phytochemicals such as alkaloids, flavonoids, and terpenoids seem to be the key components conferring the anti-hydatid cyst effects observed in these studies (26-29).

### 2.9. The identification of Live and Dead Parasites Using Eosin Dye

In parasitology, the identification of live and dead parasites using eosin dye is a technique employed in parasitology to distinguish between viable and non-viable parasites. Live parasites have intact cell membranes which prevent certain dyes, like eosin, from entering the cell. Dead parasites, on the other hand, have compromised cell membranes that allow the dye to penetrate and stain the cell (Figure 3). In this method, a solution of eosin dye is mixed with the parasites, and the mixture is then observed under a microscope. Live parasites do not take up the dye and appear as clear or transparent cells. Dead parasites are stained red or pink because the dye can penetrate their damaged cell membranes. Eosin dye is used in this process because it is a vital stain, meaning it is excluded by live cells but taken up by dead cells. This property makes eosin dye useful for quickly and easily assessing the viability of parasites (30).



**Figure 3.** Live and dead parasites using eosin dye. Live parasites (a). Dead parasites (b).

### Acknowledgment

The authors would like to thank the University of Sistan and Baluchestan, for their cooperation.

### Authors' Contribution

Conceptualized the review article, conducted the literature review, wrote the main part of the manuscript, and provided critical revisions to the manuscript; SH.H.

Prepared the figures and contributed to the literature review and writing the manuscript; SH.H

Contributed to the literature review and writing the manuscript; SH.H, Z.S.

Provided critical revisions to the manuscript and contributed to writing the manuscript; Z.S.

Took on a supervisory role, managed the project administration, and approved the final manuscript; Z.S.

### Ethics

Not Applicable.

### Conflict of Interest

The authors declare that they have no conflicts of interest to disclose.

### Financial support

This research has been financially supported by the Saffron Institute, University of Torbat Heydarieh. The grant number was 149629.

### Data Availability

The data that support the findings of this study are available on request from the corresponding author.

## References

1. Zeinali M, Mohebbali M, Shirzadi MR, Rahimi Esboei B, Erfani H, Pourmozafari J, et al. Human Cystic Echinococcosis in Different Geographical Zones of Iran: An Observational Study during 1995-2014. *Iranian journal of public health*. 2017;46(12):1623-31.
2. Ebrahimipour M, Budke CM, Harandi MF. Control of Cystic Echinococcosis in Iran: Where Do We Stand? *Trends in Parasitology*. 2020;36(7):578-81. <https://doi.org/10.1016/j.pt.2020.04.007>
3. Develoux M. [Hydatidosis in Africa in 1996: epidemiological aspects]. *Medecine tropicale : revue du Corps de sante colonial*. 1996;56(2):177-83.
4. Cucher MA, Macchiaroli N, Baldi G, Camicia F, Prada L, Maldonado L, et al. Cystic echinococcosis in South America: systematic review of species and genotypes of *Echinococcus granulosus sensu lato* in humans and natural domestic hosts. *Tropical Medicine & International Health*. 2016;21(2):166-75. <https://doi.org/10.1111/tmi.12647>
5. Grosso G, Gruttadauria S, Biondi A, Marventano S, Mistretta A. Worldwide epidemiology of liver hydatidosis including the Mediterranean area. *World journal of gastroenterology*. 2012;18(13):1425-37. <https://doi.org/10.3748/wjg.v18.i13.1425>
6. Adambekov S, Kaiirykyzy A, Igissinov N, Linkov F. Health challenges in Kazakhstan and Central Asia. *Journal of epidemiology and community health*. 2016;70(1):104-8. <https://doi.org/10.1136/jech-2015-206251>
7. Moosazadeh M, Abedi G, Mahdavi SA, Shojaee J, Charkame A, Afshari M. Epidemiological and clinical aspects of patients with hydatid cyst in Iran. *Journal of parasitic diseases : official organ of the Indian Society for Parasitology*. 2017;41(2):356-60. <https://doi.org/10.1007/s12639-016-0803-4>
8. Plummer CE, Colitz CMH, Kuonen V. Chapter 10 - Ocular Infections. In: Sellon DC, Long MT, editors. *Equine Infectious Diseases (Second Edition)*. St. Louis: W.B. Saunders; 2014. p. 109-18.e3. <https://doi.org/10.1016/B978-1-4557-0891-8.00010-5>
9. Moro PL, Schantz PM. 128 - Cystic Echinococcosis. In: Magill AJ, Hill DR, Solomon T, Ryan ET, editors. *Hunter's Tropical Medicine and Emerging Infectious Disease (Ninth Edition)*. London: W.B. Saunders; 2013. p. 908-12. <https://doi.org/10.1016/B978-1-4160-4390-4.00128-4>
10. Hanalioglu D, Terzi K, Ozkan S, Sivri M, Kurt F, Misirlioglu ED. Anaphylactic shock following minor abdominal trauma as the initial presentation of *Echinococcus* cyst: a case report. *BMC Pediatrics*. 2022;22(1):89. <https://doi.org/10.1186/s12887-022-03154-z>
11. Khalili N, Iranpour P, Khalili N, Haseli S. Hydatid Disease: A Pictorial Review of Uncommon Locations. *Iranian journal of medical sciences*. 2023;48(2):118-29.
12. Hart JM, Eshetu F, Kassa S. An unusual manifestation of hydatid disease: A case in a 20-year old male patient. *IDCases*. 2022;27:e01359. <https://doi.org/10.1016/j.idcr.2021.e01359>
13. Robertson LJ. Parasites in Food: Occurrence and Detection. In: Caballero B, Finglas PM, Toldrá F, editors. *Encyclopedia of Food and Health*. Oxford: Academic Press; 2016. p. 219-24. <https://doi.org/10.1016/B978-0-12-384947-2.00518-3>
14. Condie SJ, Crellin JR, Andersen FL, Schantz PM. Participation in a community program to prevent hydatid disease. *Public Health*. 1981;95(1):28-35. [https://doi.org/10.1016/S0033-3506\(81\)80097-2](https://doi.org/10.1016/S0033-3506(81)80097-2)
15. Reza M, Seyed, Khoshnevis, Jalaluddin, Kharazm P. Surgical treatment of hydatid cyst of the liver: Drainage Omentoplasty. *Annals of Hepatology*. 2005;4(4):272-4. [https://doi.org/10.1016/S1665-2681\(19\)32051-4](https://doi.org/10.1016/S1665-2681(19)32051-4)
16. Farhat W, Ammar H, Rguez A, Harrabi F, Said MA, Ghabry L, et al. Radical versus conservative surgical treatment of liver hydatid cysts: A paired comparison analysis. *The American Journal of Surgery*. 2022;224(1, Part A):190-5. <https://doi.org/10.1016/j.amjsurg.2021.12.014>
17. Nasser-Moghaddam S, Abrishami A, Taefi A, Malekzadeh R. Percutaneous needle aspiration, injection, and re-aspiration with or without benzimidazole coverage for uncomplicated hepatic hydatid cysts. *The Cochrane database of systematic reviews*. 2011;2011(1):CD003623. <https://doi.org/10.1002/14651858.CD003623.pub3>
18. Velasco-Tirado V, Alonso-Sardón M, Lopez-Bernus A, Romero-Alegría Á, Burguillo FJ, Muro A, et al. Medical treatment of cystic echinococcosis: systematic review and meta-analysis. *BMC infectious diseases*. 2018;18(1):306. <https://doi.org/10.1186/s12879-018-3201-y>
19. Hager J, Sergi CM. Pediatric Echinococcosis of the Liver in Austria: Clinical and Therapeutical Considerations. *Diagnostics (Basel, Switzerland)*. 2023;13(7). <https://doi.org/10.3390/diagnostics13071343>
20. Mahmoodpour H, Spotin A, Hatam GR, Pourmahdi Ghaemmaghami A, Sadjjadi SM. In vitro and ex vivo protoscolicidal effects of hydroalcoholic extracts of *Eucalyptus microtheca* on protoscoleces of *Echinococcus granulosus sensu stricto*: A light and scanning electron microscopy (SEM) study. *Experimental Parasitology*. 2023;251:108553. <https://doi.org/10.1016/j.exppara.2023.108553>
21. Benmarce M, Haif A, Elissondo MC, Bouaziz S, Bentahar A, Laatamna A. Comparison of the Scolicidal Activity of Two Leaves Extracts of *Myrtus communis* from Algeria Against *Echinococcus granulosus Sensu Lato* Protoscoleces. *Acta Parasitologica*. 2024;69(1):839-53. <https://doi.org/10.1007/s11686-024-00808-z>
22. Çelik T, Önderci M, Pehlivan M, Yumrutaş Ö, Üçkardeş F. In vitro scolicidal effects of *Sideritis perfoliata* extract against *Echinococcus granulosus*. *International*

Journal of Clinical Practice. 2021;75(10):e14498.  
<https://doi.org/10.1111/ijcp.14498>

23. Gholami S, Rahimi-Esboei B, Ebrahimzadeh M, Pourhajibagher M. In vitro effect of Sambucus ebulus on scolices of Hydatid cysts. *Eur Rev Med Pharmacol Sci*. 2013;17(13):1760-5.

24. Moazeni M, Nazer A. In vitro lethal effect of Zingiber officinale R. on protoscolices of hydatid cyst from sheep liver. *Microbiology Research*. 2011;2(2):e25.  
<https://doi.org/10.4081/mr.2011.e25>

25. Ghalavand M, Esmaeili-Gouvarchin-Ghaleh H, Mirzaei-Nodooshan M, Vazifedost S, Mohammadi-Yeganeh S. An evaluation of the effects of Pistacia atlantica gum hydro-alcoholic extract on the phagocytosis ability of macrophages and atherosclerosis development in hypercholesteremic rats. *ARYA atherosclerosis*. 2022;18(4):1-6.

26. Shahraki SH, Javar FM, Rahimi M. Quantitative and Qualitative Phytochemical Analysis of Manilkara zapota (Sapodilla) Extract and Its Antibacterial Activity on Some Gram-Positive and Gram-Negative Bacteria. *Scientifica*. 2023;2023:5967638.  
<https://doi.org/10.1155/2023/5967638>

27. Sadeghi H, Alijani HQ, Hashemi-Shahraki S, Naderifar M, Rahimi S-S, Zadeh FA, et al. Iron oxyhydroxide nanoparticles: green synthesis and their cytotoxicity activity against A549 human lung adenocarcinoma cells. *Rendiconti Lincei Scienze Fisiche e Naturali*. 2022;33(2):461-9. <https://doi.org/10.1007/s12210-022-01065-w>

28. Shahraki SH, Ahmadi T, Jamali B, Rahimi M. The biochemical and growth-associated traits of basil (*Ocimum basilicum* L.) affected by silver nanoparticles and silver. *BMC Plant Biology*. 2024;24(1):92.  
<https://doi.org/10.1186/s12870-024-04770-w>

29. Babaei M, Shabani L, Hashemi-Shahraki S. Improving the effects of salt stress by  $\beta$ -carotene and gallic acid using increasing antioxidant activity and regulating ion uptake in *Lepidium sativum* L. *Botanical Studies*. 2022;63(1):22. <https://doi.org/10.1186/s40529-022-00352-x>

30. Wen L, Lv G, Zhao J, Lu S, Gong Y, Li Y, et al. In vitro and in vivo Effects of Artesunate on *Echinococcus granulosus* Protoscoleces and Metacestodes. *Drug design, development and therapy*. 2020;14:4685-94.  
<https://doi.org/10.2147/DDDT.S254166>