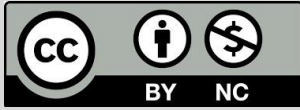

The Analysis of Norduz Sheep Mandible with DFA and PCA

Dalga, S¹, Koçak, S²

1. Department of Anatomy, Faculty of Veterinary Medicine, Kafkas University, Kars-36100 / Turkey.
2. Department of Surgery, Faculty of Veterinary Medicine, Kafkas University, Kars-36100 / Turkey.

How to cite this article: Dalga S, Koçak S. The analysis of Norduz Sheep Mandible with DFA and PCA. *Archives of Razi Institute*. 2025;80(1):139-145. DOI: [10.32592/ARL.2025.80.1.139](https://doi.org/10.32592/ARL.2025.80.1.139)



Copyright © 2023 by



Razi Vaccine & Serum Research Institute

ABSTRACT

The Norduz region, which is located inside the boundaries of the Gürpınar district of Van province, is home to the Norduz sheep, a breed of Akkaraman sheep. A sheep breed that is only bred in the Norduz region is the Norduz sheep. It has proven to be able to adjust to the severe weather in Eastern Anatolia, and it has shown distinct performance metrics that set it apart from other breeds. In this work, the Norduz sheep's mandible was analyzed and inspected utilizing a geometric morphometric approach. By using principal component analysis, principle components in multidimensional data sets were found. Using discriminant function analysis, the differences between the samples were found. The study materials used to accomplish this came from Van slaughterhouses. Gender was a factor of interest, so a total of 20 mandibles (10 female and 10 male) were chosen for analysis. First, the skull's mandibles were taken out. The underlying muscles were then dissected. The mandibles were then heated for 20 to 30 minutes, and then hydrogen peroxide was used to bleach them. After drying, the mandibles were shot from the same 20-cm distance. Photographs of the mandibles' left lateral surfaces were captured. These variations were also subjected to formal and statistical studies. There were sixteen significant variations found using the main component analysis. The observed shape differences were explained by the first three variances in 58,647% of cases. The results of the discriminant function analysis, which produced the best results for gender discrimination, were quite pleasing, showing that people were clearly and distinctly different from one another. According to the previously indicated investigations, information was obtained about the anatomical traits and adaptations of the Norduz sheep mandible, which was used as a model case study in this area.

Article Info:

Received: 18 January 2024

Accepted: 16 March 2024

Published: 28 February 2025

Corresponding Author's E-Mail:

seminaldalga@kafkas.edu.tr

sdalga91@gmail.com

Keywords: Mammalian Morphology, Discriminant Function Analysis, Principal Components Analysis, Geometric Morphometry.

1. Introduction

The Norduz sheep is an Akkaraman sheep breed that was developed in the Norduz region, which is located inside the boundaries of Van province's Gürpınar district (1-3). In addition to being bred only in the Norduz region, the Norduz sheep have proven to be able to adapt to the harsh climate of Eastern Anatolia and have unique performance characteristics that set them apart from other breeds (3). Numerous studies on Norduz sheep have been written up in scholarly journals (3-5). It is expected that research using geometric morphometric analysis and traditional morphometric approaches (6-21) will add to the body of knowledge regarding gender and figural analysis (22). Additionally, the study of species-specific patterns and evolutionary processes is made possible by geometric morphometrics. This method uses the coordinates of the points to identify the objects' form and positional differences (23). Many research on various species and skeletal components have been carried out in recent years in an effort to use geometric morphometrics to explain the sexual dimorphism seen in animal populations (24–31). Three-dimensional bone materials have also been the subject of geometric morphometric investigations in recent years (32). This study's goal was to use geometric morphometric analysis to clarify the morphological differences between Norduz sheep's male and female mandibles.

2. Materials and Methods

Van slaughterhouses provided the study materials. To perform gender-specific studies, a total of 20 mandibles (10 female and 10 male) were used. First, the mandibles were taken out of the skull. The muscles that covered it were then dissected. The next procedure was to boil the mandibles long enough to guarantee that the muscles were completely removed. After that, the mandibles were bleached by immersing them in hydrogen peroxide for 20 to 30 minutes. The mandibles were shot from the same distance (20 cm) after drying. The left lateral surfaces of the mandibles were photographed. The tpsUtil software, version 1.82, was used to save the photos that were to be used in punctuation as tps files. To mark, the tps file was loaded into the tpsDig (version 2.31) application. Ten specific spots on each mandible were marked using the TpsDig program. The same positions were used to mark each mandible in the photos. To undertake a geometric morphometric analysis, the information about the indicated mandibles was transformed into a text file and entered into MorphoJ (version 1.07a). To find shape changes, a principal component analysis (PCA) was used. After then, the components were arranged according to their percentage of variation. Additionally, form changes were acquired through the use of Discriminant Function Analysis (DFA). Discriminant Function Analysis was used to statistically

and formally analyze the differences between the male and female groups.

3. Results

Using the geometric morphometric analysis method, 20 Norduz sheep mandibles (10 females and 10 males) were analyzed in this study. A total of 16 fundamental components with 10 punctuation marks were identified. Of the entire variation among these principal components, 27.49% came from the first principle component (PC1). Of the entire variation, 17.25% was explained by the second principal component (PC2), and 13.91% by the third principal component (PC3). Table 1 displays the findings of the main component analysis. The cumulative and individual variance distributions for 16 of the main component analyses are shown in Figure 1. Together, PC1, PC2, and PC3 explain more than half of the variation, as the graph shows. Additionally, it varies significantly from person to person. A comparison of PC1, PC2, and PC3 was made when performing a principal component analysis of the results. Figure 2 shows the shape variation that was obtained for principal components 1, 2, and 3. The mean shape is represented by the dots. The extensions stand for PC1, PC2, and PC3's upper bounds. Given the significant differences between PC1 and PC2, it is clear that the infradentale expands significantly in a proximal direction. On the other hand, a distal extension was observed in PC3. The first molar tooth's anterior edge shows a proximally expanded morphology in PC3, while it shows a distally and medially enlarged morphology in PC1 and PC2. The processus coronoideus shows a distally oriented extension in PC2, while it shows a proximally directed expansion in PC1 and PC3. The gonion caudale shows a proximal growth in PC2, while it shows a distal expansion in PC1 and PC3. In PC1 and PC3, the gonion showed a clear enlargement along with a distal and ventral displacement. PC2, on the other hand, showed a proximal enlargement. The second premolar tooth terminal in PC1 and PC2 is seen to expand medially and distally in a manner toward the ventral border. However, it is seen that this expansion takes place in a proximal and medial direction in PC3. While the distance between the ventral edge and the Foreman mentale increased lateral and distal in PC2, it increased proximally in PC1 and PC3. Here, it was found that the mandible enlarged both proximally and distally when the values for PC1 and PC3 rose. PC2 showed a narrowing from the proximal to the distal region. Figure 3 shows the 16 primary components that were identified using principal component analysis. Together, the first three of these factors (PC1, PC2, and PC3) were able to account for 27,487, 17,246 and 13,914 of the variance. Moreover, the main component analysis did not show a full separation of the genders, even with the high total variance and the significant results of the discriminant function analysis (Figure 4). The anterior border of the first molar tooth showed a medial

augmentation in shape as the female to male ratio rose. The ramus mandible's anterior edge enlarges as it approaches the proximal end. Lateral expansion of the processus coronoideus was seen. It has been seen that the gonion has enlarged ventrally and distally. Laterally, the gap between the ventral margin and the mental foramen has widened. In this regard, males were found to have a larger corpus mandible and a smaller ramus mandible in comparison to females. The gender distinction in Discriminant Function Analysis is presented in both shape variations and graphically in Figures 5a, b and 6. Using Discriminant

Function Analysis (DFA), an objective assessment of gender differences was performed. Figure 6 displays the variance and frequency distribution of individuals derived from Discriminant Function Analysis for sex determination in Norduz sheep's mandibles. The male and female groups are clearly completely different from one other. Additionally, this distinction shows that there is a statistically significant difference between the two groups. The p-value (p=0.02) in the discriminant function analysis was less than 0.05.

Table 1. Principal components, eigenvalues and variances.

PC No	Eigenvalues	Varyans (%)	PC No	Eigenvalues	Varyans (%)
TB1	0,00040929	27,487	TB9	0,00003808	2,557
TB2	0,00025680	17,246	TB10	0,00002842	1,909
TB3	0,00017209	13,914	TB11	0,00001513	1,016
TB4	0,00017209	11,557	TB12	0,00001255	0,843
TB5	0,00010624	7,135	TB13	0,00000714	0,480
TB6	0,00008472	5,689	TB14	0,00000273	0,184
TB7	0,00007692	5,166	TB15	0,00000201	0,135
TB8	0,00006869	4,613	TB16	0,00000103	0,069

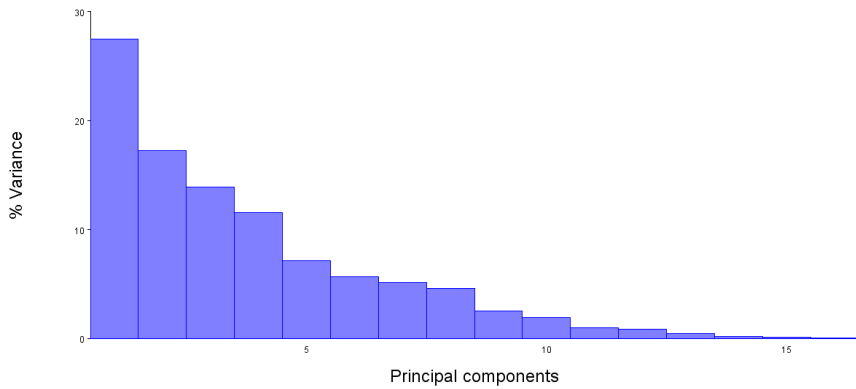


Figure 1. Variation scatter plot of principal component analysis.


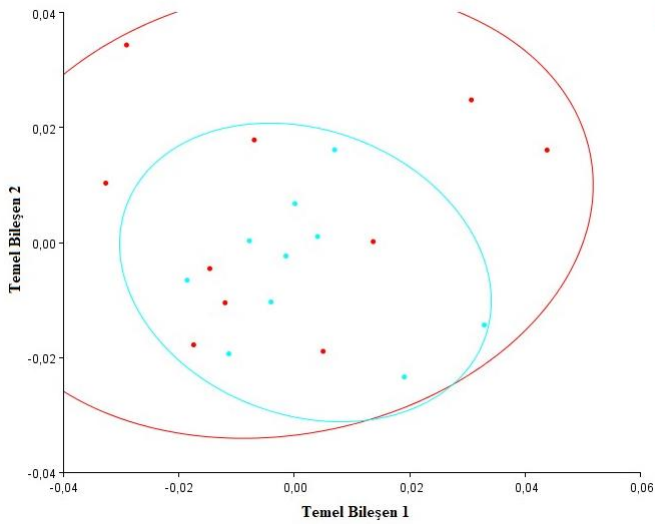


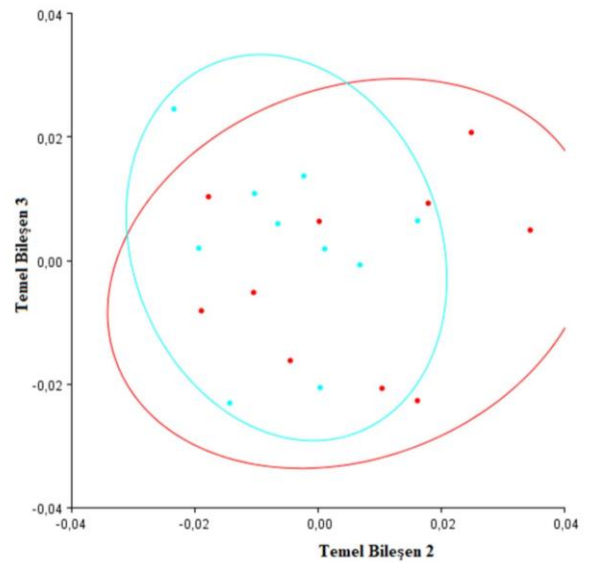
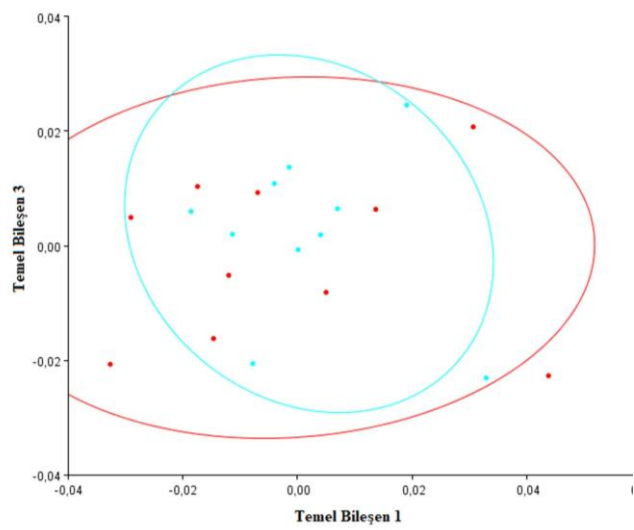
Figure 2. The shape variation of major components 1, 2, and 3 is depicted in figure. 1. Infradentale 2. The first molar tooth's anterior edge, 3: The ramus mandible's anterior edge, Incura mandibulae, Processus coronoideus, and 6. Condylaris processus, 7: Caudale gonion, 8: Ventrale gonion, 9: The second premolar's end point in relation to the ventral edge, 10: The mental foramen's distal to the ventral edge.



D
E

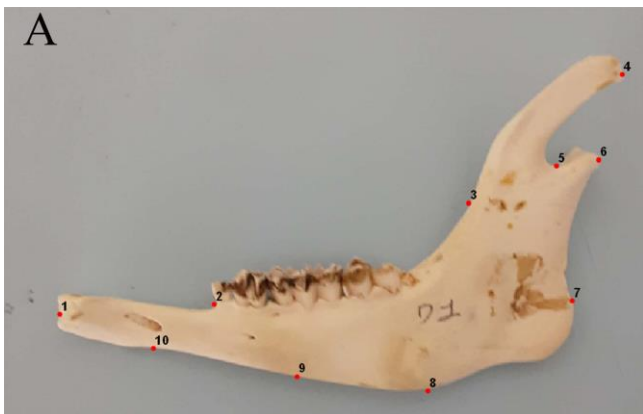Figure 5A,B. Ten selected points on the mandible are presented in photographs with punctuation. The circular dots represent the female subjects, while the e

Figure 3. Principal component 1-2 variation distributions and 95% confidence ellipses in Norduz sheep. Red dots: female, green dots: male.

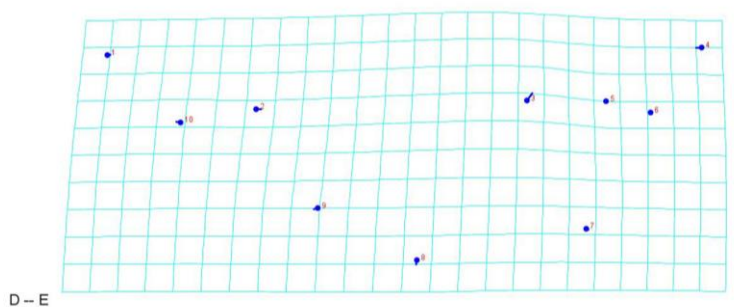


D
E

Figure 4A,B. Norduz sheep Principal component 1-3 and 2-3 variation distributions and 95% confidence ellipses. Red dots: female, green dots: male.



B



D - E

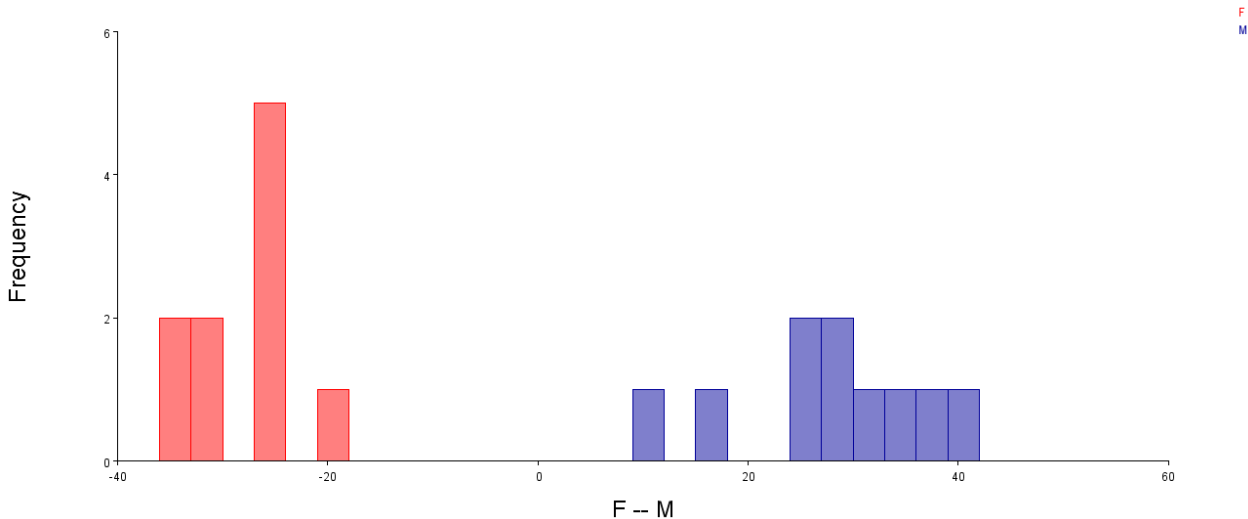


Figure 6. Gender distribution graph in Discriminant Function Analysis. Red: female, green: male.

4. Discussion

In the present study, a total of 20 mandibles from Norduz sheep (10 females and 10 males) were utilized. The mandibles of Norduz sheep were marked at 10 points, and both principal component analysis and discriminant function analysis were performed with geometric morphometric analysis. The Norduz sheep mandible was examined in order to determine the sex of the animal. The application of the geometric morphometrics method proved to be an invaluable technique for the differentiation of sexes in Norduz sheep mandibles. In our study, while no separation between the sexes was observed in the Principal Component Analysis, a complete separation between genders was evident in the Discriminant Function Analysis. In the Discriminant Function Analysis, a gradual enlargement was observed in the corpus mandible as the sex progressed from female to male. Conversely, the ramus mandible demonstrated a narrowing trend. As previously stated, the morphological data obtained from the skull and jawbone of living mammals can be used to reveal phylogenetic relationships thanks to the studies carried out with the geometric morphometric method (33). The researchers indicated that principal component analysis conducted within the framework of geometric morphometry elucidated 24.92% of the total shape disparity associated with the first principal component, particularly in the mandible of Awassi sheep (27). In the mandible of the Norduz sheep, it was determined that the first basic component explained 27.49% of the total shape difference. In a study of the jawbone of Anatolian wild sheep, the researchers (34) reported that no sex-related differences were observed in the jawbone of Anatolian wild sheep.

Similarly, principal component analysis revealed no dimorphism in Norduz sheep, consistent with the findings of Demircioğlu et al. (2023), who reported no dimorphism in the mandible of Avesi sheep. However, a complete separation between the sexes was observed in terms of Discriminate Function Analysis. In their studies on Anatolian wild sheep, Yalçın et al. (2010) proposed that the divergence in mandibular morphology at the LM9 level is a notable phenomenon. They postulated that this disparity is influenced by a complex interplay of environmental factors, dietary habits, and evolutionary adaptations during domestication. As observed in the aforementioned study, the gonion ventral enlarges distally in PC1 and PC3 and proximally in PC2 in Norduz sheep, exhibiting a similar pattern to that observed in the study. Significant differences in the LM9 parameter were also reported in Awassi sheep (Demircioğlu et al., 2023). Furthermore, it was indicated that discrepancies were observed in the LM2, LM8 and LM10 levels, albeit to a limited extent. Duro et al. (2021) also employed the geometric morphometry method to investigate sexual dimorphism in turtles, thereby contributing to the existing body of knowledge on this topic. Furthermore, in addition to the aforementioned studies on the skull, which clearly demonstrate dimorphism in ruminants, various researchers have also conducted studies on the lower jawbone, resulting in the publication of their findings in the scientific literature (35). Principal component variances, which express statistical and shape variations between groups, are related to the number of materials used. In their principal component analysis study, Koçak et al. (2023) obtained 46 variances, whereas in our study, 16 variances were obtained due to the difference in

the number of animals. The same method was employed in our study as was used by the aforementioned researchers (21), who conducted gender discrimination with discriminant function analysis. This resulted in a complete separation between the genders. Analyses were conducted on the lengths determined by studies on the skull (15), mandible (15,35) and metapodium (29,37) in sheep. The unique anatomical differences of the species were evaluated with various methods in terms of species and sex, as in our study. A more straightforward analysis of variation and deviation was employed to examine the impact of variables on gender in Norduz sheep. This work is expected to advance both the morphometric findings and the morphometric analysis of the Norduz sheep mandible. The studies that will be carried out in this field, such as the diagnosis and identification of the osteological materials retrieved from archaeological excavations, the development of three-dimensional models, and the application of these morphological analyses in animal-human models, will greatly benefit from these analyses. Additionally, using principal component analysis with the data stratified by race, the principal component variation values between males and females were investigated. Principal component analysis was also used to assess the differences in form between males and females. Furthermore, the study's main focus—gender determination—was also assessed using discriminant function analysis.

Acknowledgment

None

Authors' Contribution

Study concept and design: S.D and S.K. Acquisition of data: S.D and S.K Analysis and interpretation of data: S.D. Drafting of the manuscript: S.D. Critical revision of the manuscript for important intellectual content: S.D. Statistical analysis: S.K.

Ethics

The study permit for animal experiments was approved by the local ethics committee at Kafkas University with reference code 2023/070 (KAU/HADYЕК).

Conflict of Interest

The authors have declared no conflicts of interest.

Data Availability

The data that underpin the findings of this study are available from the corresponding author upon reasonable request.

References

- Koyuncu, M. Sheep Breeding (in Turkish). Bursa, Turkey. Dora Publishing Distribution Ltd. Şti. 1st edn. 2019;42.
- Mis, L., Mert, H., Comba, A., Comba, B., Söğütü, İD., Irak, K., Mert, N. (2018). Some mineral substance, oxidative stress and total antioxidant levels in Norduz and Morkaraman sheep. *Van Vet J*, 29 (3), 131-134.
- Delibaş, V., Soygüder, Z., Çakmak, G., Gündüz, MS. Morphological Examination of Tongue Papillae in Norduz Sheep: A Scanning Electron Microscopic Study. *Van Veterinary Journal*, 2023;34 (1) , 75-80.
- Dalga, S., Aksu, Sİ., Aslan, K., Deprem, T., Uğran, R. (2021). Morphological, Morphometrical and Histological Structure of the Interdigital Gland in Norduz Sheep. *Kafkas Univ Vet Fak Derg*, 2021, 27 (6), 749-754.
- Dalga, S., Aydın, U., Çal, T. (2022). Topographic, Morphological and Morphometric Investigation of Mandible in Norduz Sheep. *Türk Doğa ve Fen Dergisi*, 2022, 11 (3) , 129-133. DOI: 10.46810/tdfd.1100636
- Ozcan, S., Aksoy, G., Kurtul, I., Aslan, K., Ozudogru, Z. (2010). A comparative morphometric study on the skull of the Tuj and Morkaraman sheep. *Kafkas Üniversitesi Veteriner Fakültesi Dergisi* 2010; (16):111–114. [https:// doi. org/ 10. 9775/ KVFD. 2009. 518](https://doi.org/10.9775/KVFD.2009.518)
- Karimi, I., Onar, V., Pazvant, G., Hadipour, M., Mazaheri, Y. (2011). The cranial morphometric and morphologic characteristics of Mehraban sheep in Western Iran. *Glob Vet*, 2011, 6:111–117
- Mohamed, R., Driscoll, M., Mootoo, N. Clinical anatomy of the skull of the Barbados Black Belly sheep in Trinidad. *Int J Curr Res Med Sci*. 2016;2:8–19
- Dalga, S., Aslan, K., Kırbas, G. (2017). Hemşin Koyunu mandibulası üzerinde morfometrik bir çalışma. *Atatürk Üniv Vet Bil Derg*, 2017; 12(1): 22-7.
- Dalga, S., Aslan, K., Akbulut, Y. A morphometric study on the skull of the adult Hemshin sheep. *Van Vet J*. 2018;29:125–129
- Dalga, S., & Aslan, K. Topographic and morphometric study on mental foramen in Hemshin sheep for local anesthesia. *MJAVL*, 2020, 10:93–97
- Wehausen, JD., & Ramey, RR. Cranial morphometric and evolutionary relationships in the northern range of *Ovis canadensis*. *J Mammal*, 2000, 81:145–161.
- Dalga, S., & Aslan, K. Morphological and Osteometric Analysis of the Skull in Abaza goats (*Capra aegagrus*), *Dicle Üniv Vet Fak Derg*. 2021;14(1):35-38.
- Dalga, S. Topographic and morphometric study of the mental foramina of Abaza goats with its clinical implication for regional anesthesia *Folia Morphol*, 2020; 3(79): pp. 576–579.
- Jashari, T., Duro, S., Gündemir, O., Tomasz, S., Vlatko, I., Dashmir, M., Om Prakash, C. (2022). Morphology, morphometry and some aspects of clinical anatomy in the skull and mandible of Sharri sheep. *Biologia*, 2022; 77, 423–433.
- Gündemir, O., Duro, S., Jashari, T., Kahvecioğlu, O., Demircioğlu, İ., Mehmeti, H. (2020). A study on morphology and morphometric parameters on skull of the Bardhoka

- autochthonous sheep breed in Kosovo. *Anat Histol Embryol*, 2020;00:1–7.
17. Yılmaz, B., & Demircioğlu, İ. (2020). İvesi Koyunlarda (*Ovis aries*) Kafatasının Morfometrik Analizi. *Fırat Üniversitesi Sağlık Bilimleri Veteriner Dergisi*, 2020; 34:01–06
 18. Özdoğru, Z., İlgün, R., Teke, BE. (2019). Konya Merinosunun Mandibula'sı Üzerine Morfometrik Bir Çalışma. *Uluslararası Tarım ve Yaban Hayatı Bilimleri Dergisi*, 5(2): 392-395.
 19. Babaei, M., Yavari, M., Zolhavarieh, S. M., Kalantari Hesari, A. A Case History of Gross and Radiological Observations of Agnathia: Otocephaly in a Mehraban Ewe-lamb. *Iranian Journal of Veterinary Medicine*, 2023; 17(4): 415-422. doi: 10.32598/ijvm.17.4.1005231
 20. Marzban Abbasabadi, B., Ghojoghi, F., Rahmati, S., Hajian, O. Morphological Variations in the Skulls of Male and Female Persian Fallow Deer (*Dama dama mesopotamica*). *Iranian Journal of Veterinary Medicine*, 2021; 15(2): 221-232. doi: 10.22059/ijvm.2020.299875.1005075
 21. Samuel, O., Korzerzer, B., Olopade, J. O., Onwuka, S. K. A comparative osteometric evaluation of some cranial indices of clinical significance in goats (*Capra hircus*) from the middlebelt regions of Nigeria. *Iranian Journal of Veterinary Medicine*, 2013; 7(2): 111-116. doi: 10.22059/ijvm.2013.35315
 22. Klingenberg, CP., & Marugan-Lobon, J. (2013). Evolutionary Covariation in Geometric Morphometric Data: Analyzing Integration, Modularity, And Allometry In A Phylogenetic Context. *Syst. Biol*, 62: 591–610, 2013.Ff
 23. Szara, T., Duro, S., Gündemir, O., Demircioğlu, İ. (2022). Sex Determination in Japanese Quails (*Coturnix japonica*) Using Geometric Morphometrics of the Skull. *Animals*, 2022, 12: 302.
 24. Koçak, S., Özaydın, İ., Gündemir, O. (2023). Sağlıklı ve Septik Artritli Buzağılarda Karpal Eklem Radyometrik ve Geometrik Morfometrik Analizi. *Kafkas Üniv, Sağlık Bilimleri Enstitüsü, Doktora Tezi, Kars, 2023*, (in Turkish).
 25. Duro, S., Gündemir, O., Sönmez, B., Jashari, T., Szara, T., Pazvant, G., Kambo, A. (2021). A Different Perspective on Sex Dimorphism in the Adult Hermann's Tortoise: Geometric Morphometry. *Zoological Studies*, 60 (9): 3-9.
 26. Hadžiomerović, N., Gündemir, O., Tandir, F., Avdić, R., Katica, M. (2023). Geometric and Morphometric Analysis of the Auditory Ossicles in the Red Fox (*Vulpes vulpes*). *Animals* 2023, 13, 1230.
 27. Demircioğlu, I., Demiraslan, Y., Gurbuz, I., Dayan, MO. (2021). Geometric Morphometric Analysis of Skull and Mandible in Awassi Ewe and Ram. *Kafkas Üniv. Vet. Fakültesi Derg.* 2021, 27, 43–49.
 28. Gürbüz, I., AYTEK, AI., Demiraslan, Y., Onar, V., ÖZGEL, Ö. (2020). Geometric morphometric analysis of cranium of wolf (*Canis lupus*) and German shepherd dog (*Canis lupus familiaris*). *Kafkas Üniv. Vet. Fakültesi Derg.* 2020, 26, 525–532.
 29. Gündemir, O., Özkan, E., Dayan, MO., Aydogdu, S. (2020). Sexual analysis in turkey (*Meleagris gallopavo*) neurocranium using geometric morphometric methods. *Turk. J. Vet. Anim. Sci.* 2020, 44, 681–687.
 30. Parés-Casanova, PM., Tolić, A., Carricero, R. (2020). Side differences in the skull of sheep: An assessment by geometric morphometrics. *Annu Res Rev Biol*, 34 (2): 1-7, 2020. DOI: 10.9734/arrb/2019/v34i230147
 31. Parés Casanova, PM. (2015). Geometric morphometrics to the study of skull sexual dimorphism in a local domestic goat breed. *J Fisheries Livest Prod*, 3:141. DOI: 10.4172/2332-2608.1000141
 32. Fernandez Blanco, MV., Cassini, GH., Bona, P. (2023). A three-dimensional geometric morphometric analysis of the morphological transformation of *Caiman* lower jaw during post-hatching ontogeny. *PeerJ*, 11:e15548
 33. Marcus, LF., Hingst-Zaher, E., Zaher, H. (2000). Application of landmark morphometrics to skulls representing the orders of living mammals. *Hystrix*, 2000, 11, 27-47.
 34. Yalçın, H., Kaya, MA., Arslan, A. (2010). Comparative geometrical morphometrics on the mandibles of Anatolian wild sheep (*Ovis gmelini anatolica*) and Akkaraman sheep (*Ovis aries*). *Kafkas Üniv Vet Fak Derg*, 16 (1): 55-61, 2010.
 35. Özkan, E., Jashari, T., Gündemir, O., İnce, NG. (2020). Morphometric Analysis of the Mandible of Bardhoka Autochthonous Sheep in Kosovo. *Anat Histol Embryol*, 2020, (1): 1-5.
 36. Gündemir, O., Pazvant, G., Jashari, T., Dayan, MO. (2020). A morphometric study of metapodium in Bardhoka sheep. *Res Agric Vet Sci*, 2020, 4 (1): 30-38.
 37. Kahraman, M., Değirmencioğlu, İ., Gülşah, G., Gündemir, O., Özkan, E., Das, A., Yılmaz, B. (2022). Determination of the correlations between the morphological characteristics and metapodial radiometric measurements of Awassi sheep. *Eurasian J Vet Sci*, 2022, 38 (2): 180-189.