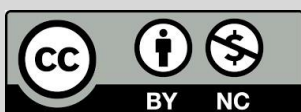

Urogenital Myiasis Caused by *Psychoda Albipennis* Larvae (Diptera: Psychodidae) in Ahvaz, South Western Iran: A Case Report

Larki, S^{1*}, Salmanzadeh, S², Jafari, Z¹

1. Department of Pathobiology, Faculty of Veterinary Medicine, Shahid Chamran University of Ahvaz, Ahvaz, Iran.
2. Infectious and Tropical Diseases Research Center, Health Research Institute, Ahvaz Jundishapur University of Medical Sciences, Ahvaz, Iran.

How to cite this article: Larki S, Salmanzadeh S, Jafari Z. Urogenital Myiasis Caused by *Psychoda Albipennis* Larvae (Diptera: Psychodidae) in Ahvaz, South Western Iran: A Case Report. *Archives of Razi Institute*. 2024;79(5):1117-1120. DOI: 10.32592/ARI.2024.79.5.1117



Copyright © 2023 by



Razi Vaccine & Serum Research Institute

ABSTRACT

Urogenital myiasis is a rare parasitic infestation caused by larvae of the *Psychoda albipennis* species. The presence of larvae in the urogenital tract, along with their feeding and activity patterns, can lead to disorders of the urinary and reproductive systems. This study presents a 36-year-old male patient with the chief complaint of dysuria, hematuria, urethral discharge, and abdominal flank pain. Over an eight-month period, the subject observed the presence of mobile particles in his urine, which were described as black-grayish in color. The patient was subsequently referred to the urology outpatient clinic, where he received treatment for cystitis and/or urethritis. However, despite these treatments, the patient's symptoms remained unresolved, and the presence of larvae in his urine was observed. Following microscopic examination of the urine, the presence of viable, motile, and hairy larvae (measuring approximately 1 cm in length) was confirmed. Based on morphological characteristics, these were identified as fourth-stage larvae of the moth fly, *Psychoda albipennis*. In Iran, human urogenital myiasis caused by *Psychoda albipennis* is an infrequent infection. It appears that the primary risk factors for urogenital myiasis in this recent case were urinating in unsanitary environments, sleeping without a blanket while traveling to the Dez River in Khuzestan province, and urinating in unsanitary toilets. The administration of appropriate antiseptic medication and the consumption of sufficient quantities of water resulted in a notable reduction in patient-reported symptoms following the two-week treatment period. Urogenital myiasis is an uncommon occurrence, comprising only 0.7% of all cases of human myiasis, as reported in a few publications from Iran and elsewhere. This is the inaugural account of urogenital myiasis caused by *P. albipennis* in the Khuzestan province of southwestern Iran.

Keywords: Urogenital Myiasis, *Psychoda Albipennis*, Larvae, Iran.

Article Info:

Received: 13 February 2024

Accepted: 9 March 2024

Published: 31 October 2024

Corresponding Author's E-Mail:
s.lar@scu.ac.ir

1. Introduction

The classification of myiasis based on the anatomical location of the infested tissue determines whether it is human or animal, living or dead. The egg or larvae of dipterous flies can infest a variety of tissues, including the skin wounds and mucous membranes of the body cavities, such as the mouth, ears, eyes, gastrointestinal, and urogenital tracts (1, 2). The infrequent occurrence of human urogenital myiasis is attributed to the covering of the urogenital area with clothing and the inaccessibility of these sites to flies. It is associated with poor sanitary conditions in socio-economically disadvantaged communities in tropical and subtropical countries (3). Myiasis is defined as the most common travel-associated disease, particularly in patients with a history of international travel. In order to make an accurate diagnosis of myiasis, it is essential to consider a number of factors, including the region that the patient has visited, the climate conditions prevailing there, and the habits of the local species that may have been encountered. Urogenital myiasis is defined as an accidental tissue invasion of larval dipterous flies which can infest the genitourinary tract of males and females. The occurrence of external or internal urogenital myiasis is dependent on the anatomical location of the infestation. Internal urogenital myiasis, in contrast to the external type, which is analogous to wound myiasis, occurs in internal genitourinary organs such as the bladder or urethra. It gives rise to related dysfunctional symptoms, including dysuria, lumbar pain, and ureteric obstruction. The most common laboratory examinations are those that test for microhematuria, albuminuria, and leucocyturia (4). Urogenital myiasis can be caused by larvae of a wide variety of fly species. In Iran, the primary etiological agents of urogenital myiasis have been identified, including *Lucilia sericata* (Diptera: Calliphoridae) and *Wohlfahrtia magnifica* (Diptera: Sarcophagidae) from Arak (5), as well as *Psychoda* sp. The larvae in question, originating from Kashan (6), and the *Psychoda albipennis* larvae (Diptera: Psychodidae) (7), were observed to be confined to the central (Markazi Province) and northwest (West Azerbaijan Province) regions of Iran, respectively. Adults of the *Psychoda albipennis* fly primarily inhabit humid and warm environments, such as unsanitary toilets, while humans typically urinate or engage in other activities in locations with low hygiene standards. The definitive treatment of urogenital myiasis is the removal of the irritating active larvae. However, in many cases, the maggot has exited the body before the larvae are detected. This report documents the first case of human urogenital myiasis caused by *Psychoda albipennis* larvae (Diptera: Psychodidae) in a 36-year-old male from Ahvaz, located in the southwest of Iran.

2. Case Presentation

A 36-year-old male patient was referred to the parasitology laboratory of the veterinary faculty of Shahid Chamran University from Golestan Hospital, Jundishapur University of Medical Sciences, Ahvaz, Iran. The patient presented

with a history of frequent urination, dysuria, abdominal discomfort, and cystitis-like symptoms, including a burning and itching sensation during or immediately following urination and hematuria. The patient was employed as a cleaning services laborer in one of the Ahvaz hospitals, located in the southwestern region of Iran, and resided in the city center. A review of the patient's medical history revealed a history of travel to rural areas along the Dez River in the northern region of Khuzestan province, swimming in tourist locations, and urination in unsanitary toilets. He had previously presented to an infectious disease clinic, where he was diagnosed with cystitis based on his symptoms and subsequently prescribed a 10- to 14-day course of antibiotics. However, the patient's symptoms persisted, and his condition did not improve until he observed the presence of black-grayish particles in his urine on three occasions over an eight-month period. Following the submission of a urine sample to the parasitology laboratory of the veterinary faculty at Shahid Chamran University of Ahvaz, the presence of live, mobile, and hairy larvae measuring approximately 1 cm in length was observed. The physical examination yielded unremarkable results. Biochemical values and complete blood count results were within the normal range. The ultrasound of the urinary system revealed no pathological findings. The patient collected three larvae, which were subsequently observed in the urine. Upon microscopic examination of the worms under a light microscope, the larvae were identified as the fourth-stage larvae of the moth fly, *Psychoda albipennis* (Figure 1&2), using the morphological features outlined in valid larval identification keys (8). The recommended treatment plan involved the administration of an appropriate antiseptic medication for the urinary tract and the consumption of sufficient quantities of water. At the follow-up visit, which occurred two weeks later, the patient reported an improvement in their itching and dysuria. Additionally, no further larvae were identified following the administration of treatment.

3. Discussion

The subfamily Psychodinae (moth flies) differs from the Phlebotominae (sand flies), which are hematophagous insects. Unlike the latter, the former are found in mild and unhygienic areas such as toilets and bathrooms, yet they do not transmit infectious pathogens. The female flies are hairy in appearance, with a length of approximately 2 mm, and lay their eggs in groups of 30–40 within a jelly-like mass. The larvae are typically found on humid and dirty hard objects, and rarely in animal or human live tissues, such as the urogenital area, where they are known as facultative myiasis. The fourth-stage larvae are characterized by a grayish hue and a hairy appearance. They are composed of seven or eight segments, with a siphon situated at the end of the final ring (1). In the survey on human myiasis conducted in Iran between 2013 and 2020, oral myiasis (23.1%) was the most prevalent type of myiasis, followed by ocular myiasis and intestinal myiasis (19.2%).

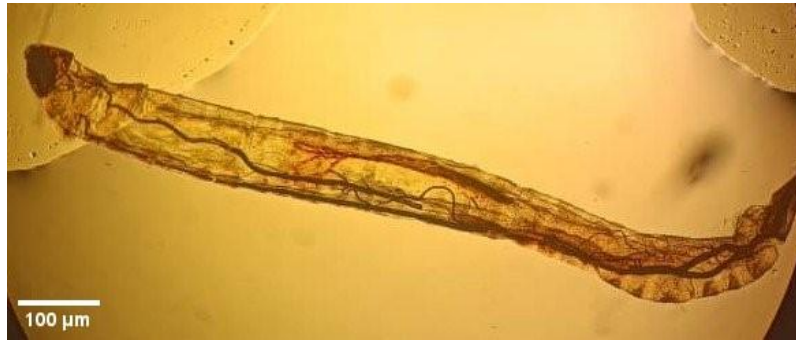

Figure 1. *P. albipennis*. larvae collected from patients' urogenital tract under microscopic magnification.




Figure 2. Oral skeleton (A) and Syphon (B) of the fourth stage larva of *P. albipennis* under microscopic magnification.

Urogenital myiasis represents a mere 7.7% (two humans) of cases, with *Psychoda* sp. observed in 3.8% (one human) of instances (9). This indicates that urogenital myiasis is a rare occurrence, accounting for only 0.7% of all documented cases of human infestations, as evidenced by the limited number of published reports (10).

The primary causative species of urogenital myiasis have been identified, including the larvae of *Fannia scalaris*, *Chrysomya bezziana*, *Sarcophaga permix*, *Lucilia sericata*, and *Eristalis tenax* in various countries. *P. albipennis*, the least common species of urogenital myiasis, has been primarily documented in Asia and South America, where it is particularly prevalent in temperate climates prone to myiasis (11). Recently, there has been an increase in the number of urogenital myiasis reports caused by *P. albipennis* in Asian countries, including Iran (7, 12), Turkey (13, 14), and India (15). In contrast, in developed countries with higher-quality healthcare systems, such as those in Central Europe, it is considered a travel-related disease (4). The diagnosis of disease is further complicated by the non-specific nature of symptoms and the rarity of cases in humans. This presents a challenge for physicians, who must consider detailed histories when making a diagnosis. In a recent report, Hazratian and colleagues (2021) documented the occurrence of urogenital myiasis caused by *P. albipennis* in the Azerbaijan province, located in the northern west of Iran (7). In the report by Salehi and colleagues (2022) from Iran, the species of *Psychoda* spp. may be identified as *P. albipennis* (12). This is the inaugural report of urogenital myiasis caused by *P. albipennis* in the

Khuzestan province of southwestern Iran. A number of common predisposing factors for urogenital myiasis have been identified, including low socioeconomic status, limited mobility, urinary obstruction, lack of access to sanitary toilets, sleeping without covering the body, and poor health conditions (4). It appears that the primary risk factors for urogenital myiasis in this patient were urinating in unsanitary environments and sleeping without a blanket, particularly during the summer months. The administration of antibiotics and antiseptics represents an additional therapeutic option for the treatment of urinary myiasis.

Acknowledgment

The authors would like to acknowledge the financial support provided by the Research Council of the Shahid Chamran University of Ahvaz, Ahvaz, Iran (grant number GN. SCU. VP1402.26535).

Ethics

The manuscript is in accordance with the ethical recommendations set forth in the Declaration of Helsinki of the World Medical Association (WMA). Sh. S. and S. L. were instrumental in the conceptualization and design of the manuscript. The project was supervised by S. L., Sh. S., and Z. J. S. L., Sh. S., and Z. J. provided the materials and were instrumental in the collection and processing of the data. Sh. S. and S. L. were instrumental in the interpretation and analysis of the project. S. L. and Sh. S. contributed to the literature review and the writing of the manuscript,

respectively. S. L., Sh. S., and Z. J. provided constructive feedback on the manuscript.

Conflict of Interest

The authors did not identify any potential conflicts of interest.

Data Availability

The data that support the findings of this study are available on request from the corresponding author.

References

1. Guven E, Kar S, Dogan N, Karaer Z. Urogenital myiasis caused by *Psychoda albipennis* in a woman. *Turkiye Parazitoloj Derg.* 2008; 32: 174–176.
2. Shrestha AB, Hoque SMS, Nawaz MH, Pokharel P, Shrestha S, Mahaseth A. Urogenital myiasis in a post-menopausal rural woman: A case report. *Int J Surg Case Rep.* 2023;106:108138.
3. Demir AD, Iraz M, İpek DN. Urogenital myiasis caused by *Psychoda albipennis* in a child. *Turk Pediatri Ars.* 2015;50 (1):65-68.
4. Francesconi F, Lupi O. Myiasis. *Clin Microbiol Rev.* 2012;25(1):79-105.
5. Salimi M, Goodarzi D, Karimfar M, Edalat H. Human Urogenital Myiasis Caused by *Lucilia sericata* (Diptera: Calliphoridae) and *Wohlfahrtia magnifica* (Diptera: Sarcophagidae) in Markazi Province of Iran. *Iran J Arthropod-borne Dis.* 2010;4(1):72–76.
6. Rasti S, Dehghani R, Khaledi HN, Takhtfiroozeh SM, Chimehi E. Uncommon Human Urinary Tract Myiasis Due to *Psychoda* Sp. Larvae, Kashan, Iran: A Case Report. *Iran J Parasitol.* 2016;11(3):417-421.
7. Hazratian T, Dolatkah A, Naghili Hokmabadi B, Hazratian E, Paksa A. First Record of Human Urogenital Myiasis Caused by *Psychoda albipennis* Larvae (Diptera: Psychodidae) in Miandoab, West Azerbaijan Province, Iran: A Case Report. *J Arthropod Borne Dis.* 2021;14(4): 425–429.
8. Velásquez Y, Magaña C, Martínez-Sánchez A, Rojo S. Diptera of forensic importance in the Iberian Peninsula: larval identification key. *Med Vet Entomol.* 2010;24(3):293–308.
9. Jokar A, Sharififard M, Jahanifard E. Prevalence of Human Myiasis and its Epidemiological Aspects in Iran From 2013 To 2020: A Review Study. *J Prevent Med.* 2022;9(2):102-115.
10. Rawat R, Seth S, Rawat R, Sinha S. Vulvar myiasis: a rare case report. *Int J Reprod Contracept Obstet Gynecol.* 2014;3(3):857-859.
11. Faridnia R, Soosaraei M, Kalani H, Fakhar M, Jokelainen P, Zolfaghari Emameh R, et al. Human urogenital myiasis: A systematic review of reported cases from 1975 to 2017. *Eur J Obstet Gynecol.* 2019;235:57-61.
12. Salehi AM, Jenabi E, Salehi M. A Rare Case of Urogenital Myiasis in a 49-Year-Old Woman. *Case Rep Med.* 2022;7910176.
13. Üntan İ, Sabur V, Kenan B. *Psychoda albipennis* myiasis as a rare cause of erectile dysfunction: A case report. *Andrologia.* 2021;53:e14087.
14. Esenkaya Taşbent F, Dik B, Kepenek Kurt E. Urogenital Myiasis Caused by *Psychoda* spp. in Female Patient with No Risk Factor for Myiasis. *Mikrobiyoloji Bul.* 2020;54(3):490–496.
15. Paul S, Upreti P, Makhija A, Nautiyal R. Urogenital myiasis – An atypical presentation. *Autops Case Rep.* 2021; 11:e2020192.