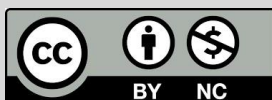

Prevalence of Helminths Infection in Wild Rodents of Northwestern Iran

Parande Shirvan, S¹, Yaghfoori, S², Mahmoudi, A³, Naddaf, SR⁴, Molawi, G⁵, Ahmadi, A⁶, Hugot, JP⁷, Mostafavi, E^{8,9*}

1. Hormozgan Provincial Office of Iran's Department of the Environment, Bandar Abbas, Iran.
2. Laboratory of Hormozgan Veterinary Head Office, Bandar Abbas, Iran.
3. Department of Biology, Faculty of Science, Urmia University, Urmia, Iran.
4. Department of Parasitology, Pasteur Institute of Iran, Tehran, Iran.
5. Department of Medical Parasitology & Mycology, School of Public Health & Institute of Public Health Research, Tehran University.
6. Department of Basic Sciences, Faculty of Veterinary Medicine, Ardakan University, P.O. Box 184, Ardakan, Iran.
7. Service de Gastroentérologie et Nutrition Pédiatrique, Hôpital Robert Debré (APHP), Paris, France.
8. National Reference laboratory for Plague, Tularemia and Q fever, Research Centre for Emerging and Reemerging infectious diseases, Pasteur Institute of Iran, Akanlu, Kabudar Ahang, Hamadan, Iran.
9. Department of Epidemiology and Biostatistics, Research Centre for Emerging and Reemerging infectious diseases, Pasteur Institute of Iran, Tehran, Iran.

How to cite this article: Parande Shirvan S, Yaghfoori S, Mahmoudi A, Naddaf SR, Molawi G, Ahmadi A, Hugot JP, Mostafavi E. Prevalence of helminths infection in wild rodents of Northwestern Iran. *Archives of Razi Institute*. 2024;79(1):120-128. DOI: 10.32592/ARI.2024.79.1.120



Copyright © 2023 by

Razi Vaccine & Serum Research Institute



Article Info:

Received: 2 July 2023

Accepted: 29 July 2023

Published: 29 February 2024

Corresponding Author's E-Mail:
mostafavihsan@gmail.com

ABSTRACT

Rodents act as reservoirs, intermediate hosts, or definitive hosts for various zoonotic helminths. Parasitic diseases are among the critical factors affecting the survival and composition of wild rodent populations. Wild rodents share their habitat with domestic free-grazing animals, mainly sheep, stray dogs, and cats, which allows the transmission of helminth infections, such as *Toxocara* and *Trichinella*, to these animals. This study investigated the helminth parasite fauna of wild rodents in East Azerbaijan province, north-western Iran, and discussed the possibility of parasite transmission among wild rodents. A total of 204 rodents of 17 different species (spp.) were collected in north-western Iran. Information about the genus, developmental stage, and rodent spp. was recorded for each animal. The gastrointestinal tract, liver, and diaphragm were examined for the presence of helminths. The recovered specimens were identified based on references. The prevalence rate of helminth infection among the captured rodents was 67.16%. *Meriones persicus* (*M. persicus*) showed the highest infection and diversity rates. This spp. harbored the zoonotic helminth *Capillaria hepatica* and some spp. belonging to the genera *Toxocara*, *Syphacia*, and *Hymenolepis*. *M. persicus* specimens from mountainous areas showed the highest infection rate. This study aimed at evaluating the potential role of wild rodent spp. as reservoirs of helminth infection in East Azerbaijan province, Iran. *M. persicus* was the most common spp. in our study and represented a higher proportion of the infected rodents in terms of helminth diversity and frequency. Harboring zoonotic helminths, *M. persicus* represents a health risk. Further studies are recommended to evaluate the prevalence of these parasites in the human community and inform people concerned about the risk of disease transmission to humans through rodents.

Keywords: Helminths, Public health, Wild rodents

1. Introduction

Wild rodents represent a conspicuous and diversified group of the living fauna of any ecosystem worldwide. They constitute a significant part of predator diets and are an ecosystem service provider in charge of the germination and dispersal of seeds and spores (1). On the other hand, they are agricultural pests and play a central role in harvest losses. They are also the paratenic and intermediate hosts for numerous parasites pathogenic to domestic animals and humans (1, 2). Parasitic diseases are among the critical factors affecting the survival and composition of wild rodent populations. Investigations into infectious diseases can determine their population situation, explaining the renewed interest they have aroused in recent years (3-7). Wild rodents share their habitat with domestic free-grazing animals, mainly sheep, stray dogs, and cats, which allows the transmission of helminth infections, such as *Toxocara* and *Trichinella*, to these animals (2, 8). Besides, forest fragmentation and urbanization have increased the proximity between wild rodents and humans. This might pose a severe threat to humans and domestic animals, particularly regarding infections caused by *Capillaria hepatica* (*C. hepatica*), *Syphacia*, and *Hymenolepis* species (spp.) (9). Therefore, the study of rodent-borne parasitic diseases may contribute to the preservation efforts of public health (10, 11). This study investigated the helminth parasite fauna of wild rodents in East Azerbaijan province, north-western Iran, and discussed the possibility of parasite transmission among wild rodents, humans, and domestic animals.

2. Materials and Methods

This study is part of a more extensive survey investigating rodent-borne infectious diseases and their public health significance in north-western Iran. It aimed to study helminths in wild rodents and the importance of parasites found in rodents

concerning their relevance to public and domestic animals' health.

Study Area and Sampling

Rodents were captured under a two-stage random sampling design. In step one, 103 rodent spp. were captured, and in step two, 101 rodent spp. were captured. Sampling was carried out using live traps at 26 locations installed in crop fields, mountains, arboreturns, plains, along rivers and roads, rural houses, industrial units, rolling terrain, and foothills.

Identification of Rodents

Live rodents were euthanized by exposure to isoflurane. The identification and development stages of all rodent spp. were done based on morphological and morphometric measurements using a valid reference (12). The developmental stage (adults vs. subadults) was assessed based on cranium shape and molar patterns. The spp. and genus identifications were recorded for each animal according to external morphology (such as pelage coloration and tail morphology) and morphometry (such as head and body length, tail length, hindfoot length, ear length, and weight). Animals were then necropsied, and the entire gastrointestinal (GI) tract, liver, and diaphragm were placed in individual tubes, labeled, and transported to the Parasitology Laboratory of Veterinary Medicine, Ferdowsi University of Mashhad, Mashhad, Iran.

Helminths Identification

The dissected GIs were examined for the presence of helminths using a dissecting microscope. The nematodes collected from the intestine and stomach were washed in a saline solution and preserved in 70% ethanol. The worms were clarified in lactophenol and identified according to morphological characterizations (13). The recovered cestodes and trematodes were washed and relaxed in the water and then stained with carmine acid. The specimens were dehydrated in alcohols of various concentrations, cleared in methyl salicylate, and mounted in Canada balsam. The helminths were

identified based on valid references (14). The animals' diaphragm tissues were investigated for *Trichinella* spp. and *Toxocara* larvae by microscope. The diaphragms were cut into 3-4 mm pieces, compressed between two glass slides, and examined under the light microscope at 40× magnification. The rodent diaphragms with larvae were digested with HCL 0.5% for 24 h at 37°C. Following centrifugation for 2 min at 1500 rpm, the recovered larvae were identified by microscopy at 40× magnification (15). The liver of each rodent was macerated gently in a mortar using a pestle, suspended in water, and centrifuged for 2 min at 1500 rpm. The pellets were examined for the presence of *C. hepatica* eggs.

Data Analysis

Regarding the high number of *Meriones persicus* (*M. persicus*) trapped in this study (55.88%) and to minimize the possible effects of host spp. variation on the diversity and prevalence of helminth infection, only *M. persicus* specimens were included in the evaluation of the impact of gender and sampling location on helminth infection and diversity. The Chi-squared test using Prism 6.01 (GraphPad, La Jolla, CA, USA) software was used to make a comparison between helminth infection and the gender of *M. persicus*, while the Kruskal-Wallis test was employed to test the association between helminth infection and sampling locations. Trapping locations of *M. persicus* were divided into five categories, including mountainous landscapes covered with *Astragalus* spp. (n=20), crop fields (n=19), plain landscapes (n=32), rolling terrain (n=13), and locations close to human residential areas, including rural houses, along rivers, industrial units, and arboretum landscapes (n=30). The sample size was inadequate for comparing the seasonal effects and the prevalence of helminth infection, owing to the sampling in two different seasons (90 samples in October vs. 24 samples in June). The prevalence rate of helminth infection was calculated for each rodent spp., and the diversity of helminths

was recorded. The relative roles of gender and season were calculated for the total helminth infection. Ethical approval for the study was obtained from the Ethical Committee of the National Institute for Medical Research (Ethical code: IR NIMAD REC 1396 079).

3. Results

Rodent Species Identification

A total of 204 rodent specimens (86 males and 118 females) belonging to 12 genera and 17 spp. were trapped in this study. The spp. included *Apodemus wetherbyi* (n=19, 9.31%), *Arvicola persicus* (n=10, 4.9%), *Chionomys nivalis* (n=2, 0.98%), *Dryomys nitedula* (n=7, 3.43%), *Ellobius lutescens* (n=1, 0.49%), *Meriones libycus* (n=1, 0.49%), *M. persicus* (n=114, 55.88%), *Meriones vinogradovi* (*M. vinogradovi*; n=10, 4.9%), *Mesocricetus brandti* (n=1, 0.49%), *Microtus mystacinus* (n=2, 0.98%), *Microtus obscurus* (n=3, 1.47%), *Microtus socialis* (n=21, 10.29%), *Mus macedonicus* (n=4, 1.96%), *Mus musculus* (*M. musculus*; n=1, 0.49%), *Nothocricetulus migratorius* (n=3, 1.47%), *Rattus norvegicus* (*R. norvegicus*; n=2, 0.98%), and *Scarturus williamsi* (n=3, 1.47%). Overall, 137 rodents, including 54 males and 83 females, had an infection with at least one helminth spp. (67.16%; 95% CI: 60.5%-73.3%). The identified GI helminths included *Heligmosomoides polygyrus*, *Syphacia* spp., *Nippostrongylus brasiliensis*, *Trichuris* spp., *Rictolaria* spp., *Trichostrongylidae*, *Aspicularis* spp., *Mastophorus* spp., *Hymenolepis* spp., *Mesocestoides* spp., and *Notocotylus* spp. Furthermore, *Toxocara* larvae and *C. hepatica* eggs were detected in the diaphragm and liver, respectively (Figure 1).

Association between Gender, Season, and Host Species in Helminth Infection

The difference in helminth infection prevalence rate between males (62.79%) and females (70.34%) was not statistically significant ($P=0.25$). There was also no significant association between season and

infection prevalence in the rodents examined ($P=0.31$). As only 10 subadult rodents were captured, estimating the effect of age on the prevalence and composition of helminths was unreliable. Table 1 shows the prevalence per host spp. The prevalence of helminth infection was different depending on the rodent spp. examined (Table 1), and the highest rate was observed in *M. persicus* (83 of 137 [60.59%]). Host spp. also had an impact on the helminth spectrum (Table 2). Among the captured rodents, *Scarturus williamsi*, *Dryomys nitedula*, *M. musculus*, and *R. norvegicus* showed no helminth infection. *Apodemus witherbyi* was infected with one or more parasites, and *Heligmosomoides polygyrus* was detected only in this rodent. Three GI helminths, including *Trichuris* spp., *Hymenolepis* spp., and *Notocotylus* spp., were found in *Arvicola persicus*. *Toxocara* larvae were found in the diaphragm of *Snow vole* and *Chionomys nivalis*. *Ellobius lutescens* and *M. persicus* also had *Toxocara* larvae infections. *Meriones* spp., the most numerous collected group, were infected with several spp. of helminths. The eggs of *C. hepatica*, a zoonotic helminth infection, were detected in the livers of two *M. persicus* and one *M. vinogradovi*. In

Microtus spp., the parasites *Syphacia* spp., *Nippostrongylus brasiliensis*, *Trichostrongylidae*, *Aspicularis* spp., and *Hymenolepis* spp. were found in the GI. The parasites found in *Mus macedonicus* were *Syphacia* spp., *Trichostrongylidae*, and *Hymenolepis* spp.

Mixed infections were common and were recorded in 35 specimens. One *M. persicus* and one *Microtus* spp. were infected with three different spp. of nematodes.

Gender and Habitat Effects on Helminths Composition in *M. persicus*

In *M. persicus*, the prevalence of helminth infection between males (68.8%) and females (76.12%) showed no significant difference ($P=0.34$). The prevalence rate of helminth infection per habitat type showed the highest infection rate for mountainous landscapes (90%), followed by plain landscapes (75%), crop fields (63.16%), locations close to human residents (60%), and rolling terrain (53.84%). The zoonotic helminths, *C. hepatica* and *Toxocara* larvae, were found in locations close to human residents, *Toxocara* larvae in rural areas, and *C. hepatica* both in rural areas and industrial locations.

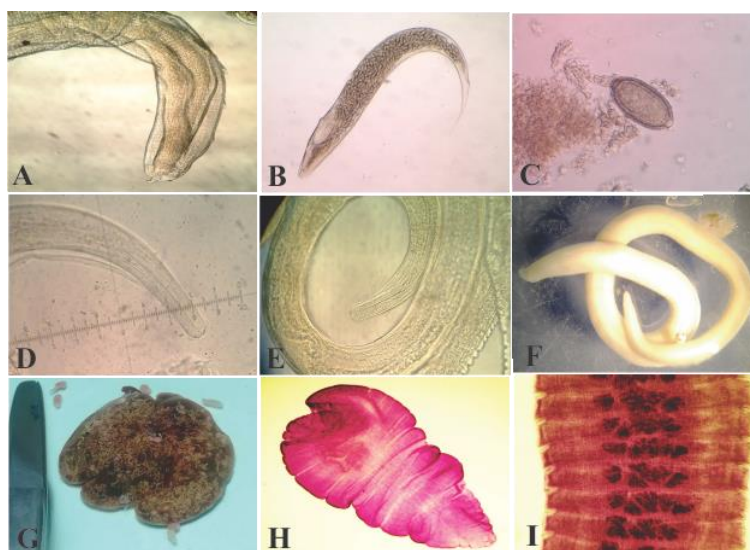


Figure 1. Helminths collected from wild rodents in East Azerbaijan Province. A) *Rictolaria* spp., B) *Syphacia*, C) Egg of *Capillaria*, D) *Nippostrongylus* spp., E) *Heligmosomoides* spp., F) *Mastophorus* spp., G) Macroscopic view of *Taenia taeniaeformis* larval migration in liver, H) *Mesocestoide*, I) *Hymenolepis* spp

Table 1. Prevalence per host species of rodents captured in East Azerbaijan Province, Iran

	<i>Scarturus williamsi</i>	<i>Apodemus. witherbyi</i>	<i>Arvicola. persicus</i>	<i>Chionomys. nivalis</i>	<i>Nothocricetulus. migratorius</i>	<i>Dryomys. nitidula</i>	<i>Ellobius. lutescens</i>	<i>Meriones. libycus</i>	<i>Meriones. persicus</i>	<i>Meriones. vinogradovi</i>	<i>Mesocricetus brandii</i>	<i>Microtus spp.</i>	<i>Mus macedonicus</i>	<i>Mus musculus</i>	<i>R. norvegicus</i>
Prevalence (%) Trapped/infected male	0% (1/0)	78.57% (14/11)	60% (5/3)	0% (1/0)	-	0% (3/0)	-	-	68% (47/32)	0% (2/0)	-	77.77% (9/7)	50% (2/1)	0% (1/0)	0% (2/0)
Prevalence (%) Trapped/infected female	0% (2/0)	60% (5/3)	40% (5/2)	100% (1/1)	66.67% (3/2)	0% (4/0)	100% (1/1)	100% (1/1)	76.12% (67/51)	50% (8/4)	100% (1/1)	88.23% (17/15)	100% (2/2)	-	-
Prevalence (%) Trapped/infected	0% (3/0)	73.68% (19/11)	50% (10/5)	50% (2/1)	66.67% (3/2)	0% (7/0)	100% (1/1)	100% (1/1)	72.80% (114/67)	40% (10/4)	100% (1/1)	84.61% (26/22)	75% (4/3)	0% (1/0)	0% (2/0)
Prevalence (%) Total infection/Infected species	0% (137/0)	10.22% (137/14)	3.65% (137/5)	0.73% (137/1)	1.46% (137/2)	0% (137/0)	0.73% (137/1)	0.73% (137/1)	60.59% (137/83)	2.92% (137/4)	0.73% (137/1)	16.05% (137/22)	2.19% (137/3)	0% (137/0)	0% (137/0)

Table 2. Diversity of helminths infection in different rodent species captured from East Azerbaijan Province, Iran

	<i>Scarturus spp</i> N=3	<i>Apodemus sp.</i> N=19	<i>Arvicola sp</i> N=10	<i>Chionomys sp</i> N=2	<i>Nothocricetulus sp</i> N=3	<i>Dryomys sp</i> N=7	<i>Ellobius sp</i> N=1	<i>Meriones sp</i> N=125	<i>Mesocricetus sp</i> N=1	<i>Microtus sp</i> N=26	<i>Mus sp</i> N=5	<i>Rattus sp</i> N=2
<i>Heligmosomoides polygyrus</i>	-	10	-	-	-	-	-	-	-	-	-	-
<i>Syphacia</i>	-	6	-	-	1	-	-	3	-	18	2	-
<i>Nippostrongylus brasiliensis</i>	-	2	-	-	-	-	-	-	-	2	-	-
<i>Trichuris sp.</i>	-	1	1	-	1	-	-	44	1	-	-	-
<i>Rictolaria spp.</i>	-	-	-	-	-	-	-	1	1	-	-	-
<i>Microfilaria</i>	-	-	-	-	-	-	-	1	-	-	-	-
<i>Trichostrongylidae</i>	-	-	-	-	-	-	-	2	-	9	1	-
<i>Aspicularis</i>	-	-	-	-	-	-	-	1	-	2	-	-
<i>Mastophorus sp.</i>	-	-	-	-	-	-	-	2	-	-	-	-
<i>Hymenolepis sp.</i>	-	5	2	-	1	-	-	54	-	4	1	-
Mesocostoides	-	-	-	-	1	-	-	10	-	-	-	-
<i>Notocotylus sp.</i>	-	-	2	-	1	-	-	-	-	-	-	-
<i>Capillaria</i>	-	-	-	-	-	-	-	3	-	-	-	-
<i>Toxocara larva</i>	-	-	-	1	-	-	1	1	-	-	-	-

Table 3. Helminth infection per each study area in *Meriones persicus*

Locality	No. Of <i>M. Persicus</i>	No. Of Infected <i>M. Persicus</i>	Type Of Infection					
			Cestode	Nematode	Trematode	Mesocestoides	Toxocara Larva	Capillaria
Mountainous landscape	20	18	11	9	-	-	-	-
Crop fields	19	12	9	6	-	-	-	-
Plain landscape	32	24	16	14	-	4	-	-
Rolling terrain	13	7	2	5	-	2	-	-
Locations with close contact to human	30	18	14	11	-	2	1	2

4. Discussion

An increasing amount of research conducted in the field of parasitology is highlighting the crucial role of wild rodents in the transmission of pathogenic diseases to humans and livestock (6, 7, 16, 17). Several recent studies have evaluated the prevalence and diversity of helminth fauna in wild rodents in Iran (17-21). In East Azerbaijan province, only a recent study on commensal rodents was conducted in Tabriz city (22). Therefore, the present study is the only recent study investigating the helminths of wild rodents in this province. Like most previous studies (21, 23), the most abundant spp. in the captures was *M. persicus*. There is a positive effect of host population size on the prevalence and diversity of pathogens (24, 25). Therefore, it seems not to be surprising to find the wealthiest parasite fauna for this spp. than for other rodents. This phenomenon is reflected by the prevalence and abundance of particular helminth spp., such as *Hymenolepis* spp. and *Trichuris* spp. (Table 3). *M. persicus* harbored the highest prevalence rate (60.59%) among the identified helminth spp. Therefore, it can be assumed that this spp. might be an important reservoir for helminth infection in this region. Because *M. persicus* lives in various ecosystems, ranging from pure wild landscapes (mountainous, plain, and arid landscapes) to semi-domestic areas (cultivated fields, rural areas, and industrial units), this spp. is potentially a great threat to public health (26, 27). Specimens of *M. persicus* captured in mountainous landscapes had the highest infection rate

(18 of 20, 90%), while specimens from localities close to human residents showed more diversity of parasite spp. The presence of zoonotic parasites, such as *C. hepatica*, *Syphacia* spp., *Hymenolepis* spp., and *Toxocara* larvae, in *M. persicus* suggests a survey of these parasites' prevalence in the human community; however, earlier studies, such as Kia et al. (2001) and Asakawa et al. (1996), investigated parasitic helminths in various rodent spp. and identified genera such as *Trichostrongylus* spp., *Armocapillaria*, *Trichocephalus*, *Heligmosomoides* spp., *Rictularia* spp., *Capillaria* spp., *Syphacia* spp., *Aspicularis* spp., and *Strongyloides*. Their importance was also described from the point of view of public health (17). *Trichuris* spp. was the common parasite at most sampling sites and was the only nematode found in rolling terrain. Since these nematode eggs are resistant to drought and heat, their prevalence is not significantly influenced by climatic changes (28).

C. hepatica is a zoonotic disease that infects the hepatic parenchyma of its hosts. Heretofore, this parasite has been reported in >90 rodent spp. *C. hepatica* infection has been recorded in various rodents in Iran, including *M. persicus*, *M. musculus*, *Nothocricetulus migratorius* (Meshkin-Shahr district), *M. persicus* (Dasht-e-Moghan, Ardabil Province) (19), as well as *M. musculus*, *R. norvegicus*, and *Rattus rattus* (Kermanshah) (29). In this study, the eggs of *C. hepatica* were found in the livers of *Meriones* spp. (*M. persicus*=2 and *M. vinogradovi*=1) captured in rural areas and industrial units, emphasizing the necessity of

controlling rodents and devising sanitation programs. In the present study, three spp. had the infective stage of *Toxocara* spp. However, this stage of *Toxocara* spp. is a zoonotic agent commonly reported worldwide, and its importance as a zoonotic agent should not be underestimated (30). The principal goal of this study was to detect *Trichinella* spp., but this parasite was not detected. *Syphacia obvelata*, *Hymenolepis diminuta*, and *Hymenolepis nana* occasionally infect humans, which was also reported by Yosefi et al. (2014) and Mohtasebi et al. (2020) in Iran (31, 32). However, it is doubtful whether these parasites in rodents are the same spp. infecting humans (33-35). In our study, seven spp. (*Apodemus witherbyi*, *Arvicola persicus*, *Nothocricetulus migratorius*, *M. persicus*, *Microtus mystacinus*, *Microtus socialis*, and *Mus macedonicus*) were infected with *Hymenolepis* spp. Arzamani et al. (2017) observed no parasitic infection in *Ellobius* spp. and *Dryomys* spp. in north Khorasan province, Iran, which is consistent with our findings as well. This study indicates that while different sampling sites share the majority of helminth spp. that are endemic in the region, rolling terrain showed less *Hymenolepis* spp. infection. This is related to the harsh air environment and limited intermediate hosts, resulting in a limited opportunity for infection (36, 37). In the present study, *Mesocestoides* spp. was found in the peritoneal cavity and the liver of *M. persicus* and one *Nothocricetulus migratorius*. Rodents are known as the intermediate hosts of *Taenia taeniaeformis* and *Taenia crassiceps*, which rarely infect humans (38). The larval stages of *Taenia taeniaeformis* are found in the livers of rodents. Metacestodes of *Taenia crassiceps* are detected in peritoneal and pleural cavities, subcutaneous tissues, and muscles and have zoonotic importance, particularly in immunodeficient patients (39). *Mesocestoides* spp. has been recorded in other rodent spp., such as *M. persicus* and *Cricetulus migratorius*, in north-western Iran (17). In conclusion, we assessed the potential role of wild rodent spp. as reservoirs of helminth infection in East Azerbaijan province. *M. persicus* was the most common spp. in our study and represented a higher proportion of the infected

rodents in terms of helminth diversity and frequency. Harboring zoonotic helminths, *M. persicus* represents a health risk. In the future, it is recommended to evaluate the prevalence of these parasites in the human community and inform people concerned about the risk of disease transmission to humans through rodents.

Acknowledgment

The research was supported by the National Institute for Medical Research Development of Iran (grant no 957145). The funders had no role in study design, data collection, analysis, decision to publish, or manuscript preparation. We would like to thank Mr. Hamed Hanifi, Mr. Alireza Mordadi, Mr. Ali Mohammadi, Mr. Hesamoddin Zali, Mr. Seyyed Adel Hosseini, Dr. Majid Hemmati and Dr. Hosein Ahangari Kohan from Pasteur Institute of Iran, who supported us in data sampling.

Authors' Contribution

Conceived and designed the analysis, collected the data, contributes data or analysis tools, performed the analysis and wrote the paper. All authors reviewed the manuscript.

Ethics

We hereby declare all ethical standards have been respected in preparation of the submitted article.

Conflict of Interest

The authors declare that they have no known competing financial interests or personal relationships that could have appeared to influence the work reported in this paper.

Funding

This research received no specific grant from any funding agency in the public, commercial, or not-for-profit sectors.

References

1. Morand S, Krasnov BR, Poulin R. Micromammals and macroparasites: from evolutionary ecology to management: Springer; 2007.
2. Krücken J, Blümke J, Maaz D, Demeler J, Ramünke S, Antolová D, et al. Small rodents as paratenic or intermediate hosts of carnivore parasites in Berlin, Germany. *PloS one*. 2017;12(3):e0172829.
3. Cao X, Wang Y, Wang Y, Li H, Luo L, Wang P, et al. Prevalence and Characteristics of *Listeria ivanovii* Strains in Wild Rodents in China. *Vector-Borne and Zoonotic Diseases*. 2019;19(1):8-15.
4. Krijger IM, Meerburg BG, Harmanus C, Burt SA. *Clostridium difficile* in wild rodents and insectivores in the Netherlands. *Letters in applied microbiology*. 2019.
5. Kudo Y, Vansith K, Rin E, Uchida K, Kodama S, Fukui T, et al. Molecular Epidemiological Survey of *Leptospira* Infection of Wild Rodents in the Urban Settlement of Cambodia. *Vector-Borne and Zoonotic Diseases*. 2018;18(3):144-50.
6. Cardoso TdS, Braga CA dC, Macabu CE, Simões RdO, Costa-Neto SFd, Maldonado Júnior A, et al. Helminth metacommunity structure of wild rodents in a preserved area of the Atlantic Forest, Southeast Brazil. *Revista Brasileira de Parasitologia Veterinária*. 2018;27(4):495-504.
7. Siribat P, Chaisiri K, Douangboupouha B, Ribas A, Chaval Y, Herbreteau V, et al. Helminth communities in murid rodents from southern and northern localities in Lao PDR: The role of habitat and season. 2019.
8. Hidalgo A, Villanueva J, Becerra V, Soriano C, Melo A, Fonseca-Salamanca F. *Trichinella spiralis* Infecting Wild Boars in Southern Chile: Evidence of an Underrated Risk. *Vector-Borne and Zoonotic Diseases*. 2019;19(8):625-9.
9. Rabiee MH, Mahmoudi A, Siahsarvie R, Kryštufek B, Mostafavi E. Rodent-borne diseases and their public health importance in Iran. *PLoS neglected tropical diseases*. 2018;12(4):e0006256.
10. Ola-Fadunsin.S D, Abdulrauf.A B, Ganiyu.I, Hussain.K, Ambali.H M, Elelu.N. The Intensity of Infection and Public Health Perception of Potentially Zoonotic Intestinal Parasites of Dogs in Kwara Central, Nigeria. *Iranian Journal of Veterinary Medicine*. 2023;17(2):119-28.
11. Ahmad.S, Chowdhury.S.M, Hossain.M.M, Rahman.M.M, Rahman MM. The Prevalence of Gastrointestinal Parasites in Buffalo Calves in Sylhet District of Bangladesh. *Iranian Journal of Veterinary Medicine*. 2020;14(3):221-9.
12. Darvish J, Mohammadi Z, Mahmoudi A, Siahsarvie R. Faunistic and taxonomic study of Rodents from northwestern Iran. *Iranian Journal of Animal Biosystematics (IJAB)*. 2014;10(2):119-36.
13. Anderson RC, Chabaud AG, Willmott S. *Keys to the nematode parasites of vertebrates: archival volume: Cabi*; 2009.
14. Yamaguti S. *Systema Helminthum*. vol. II. The cestodes of vertebrates. *Systema helminthum Vol II The cestodes of vertebrates*. 1959.
15. Soulsby E.J.L. *Helminths, arthropods, & protozoa of domesticated animals: Williams and Wilkins Co.* xix; 1968.
16. Chou M, Siew C, Morand S, Ribas A. Gastrointestinal helminth fauna of rodents from Cambodia: Emphasizing the community ecology of host-parasite associations. 2019.
17. Moradpour N, Borji H, Darvish J, Moshaverinia A, Mahmoudi A. Rodents Helminth Parasites in Different Region of Iran. *Iranian journal of parasitology*. 2018;13(2):275.
18. Khajeh A, Mohammadi Z, Darvish J, Razmi GR, Ghorbani F, Mohammadi A, et al. A survey on endoparasites in wild rodents of the Jaz Murian depression and adjacent areas, southeast of Iran. *Journal of parasitic diseases*. 2018;42(4):589-97.
19. Kia E, Shahryary-Rad E, Mohebbali M, Mahmoudi M, Mobedi I, Zahabiun F, et al. Endoparasites of rodents and their zoonotic importance in Germe, Dashte-Mogan, Ardabil Province, Iran. *Iranian journal of parasitology*. 2010;5(4):15.
20. Nateghpour M, Motevalli-Haghi A, Akbarzadeh K, Akhavan AA, Mohebbali M, Mobedi I, et al. Endoparasites of wild rodents in southeastern Iran. *Journal of arthropod-borne diseases*. 2015;9(1):1.
21. Harandi MF, Madjdzadeh SM, Ahmadinejad M. Helminth parasites of small mammals in Kerman province, southeastern Iran. *Journal of parasitic diseases*. 2016;40(1):106-9.
22. Garedaghi Y, AFSHIN KA. Prevalence of gastrointestinal and blood parasites of rodents in Tabriz, Iran, with emphasis on parasitic zoonoses. 2014.
23. Ranjbar MJ, Sarkari B, Mowlavi GR, Seifollahi Z, Moshfe A, KHABISI SA, et al. Helminth Infections of Rodents and Their Zoonotic Importance in Boyer-Ahmad

- District, Southwestern Iran. Iranian journal of parasitology. 2017;12(4):572.
24. Poulin R. Macroecological patterns of species richness in parasite assemblages. Basic and Applied Ecology. 2004;5(5):423-34.
25. Feliu C, Renaud F, Catzefflis F, Hugot J-P, Durand P, Morand S. A comparative analysis of parasite species richness of Iberian rodents. Parasitology. 1997;115(4):453-66.
26. Z Z, Mohebbali.M, Heidari.Z, Davoodi.J, Shabestari.A, A MH, et al. Helminth Infections of *Meriones persicus* (Persian Jird), *Mus musculus* (House Mice) and *Cricetulus migratorius* (Grey Hamster): A Cross-Sectional Study in Meshkin-Shahr District, Northwest Iran. Iranian journal of Parasitology. 2016;11(2):213-20.
27. Adam.M, Bakare.R, Ola-Fadunsin.S.D, Akanbi.O.B, Kigir.E.S, Barka.S.A. Pathological Changes of *Fasciola* Species Infection in Cattle Slaughtered in Ilorin Abattoir Kwara State, Nigeria. Iranian Journal of Veterinary Medicine. 2022;16(4):356-63.
28. Okulewicz.A. The impact of global climate change on the spread of parasitic nematodes. Annals of parasitology. 2017;63(1):15-20.
29. Pakdel N, Naem S, Rezaei F, Chalehchaleh A-A, editors. A survey on helminthic infection in mice (*Mus musculus*) and rats (*Rattus norvegicus* and *Rattus rattus*) in Kermanshah, Iran. Veterinary Research Forum; 2013: Faculty of Veterinary Medicine, Urmia University, Urmia, Iran.
30. Hildebrand J, Zalesny G, Okulewicz A, Baszkiewicz K. Preliminary studies on the zoonotic importance of rodents as a reservoir of toxocarasis from recreation grounds in Wroclaw (Poland). Helminthologia. 2009;46(2):80-4.
31. Mohtasebi.S., Teimouri.A., Mobedi.I., Mohtasebi.A., Abbasian.H., Afshar.M.J. A. Intestinal helminthic parasites of rodents in the central region of Iran: first report of a capillariid nematode from *Dryomys nitedula*. BMC research notes. 2020;13(1):461.
32. Yousefi A, Eslami A, Mobedi I, Rahbari S, Ronaghi H. Helminth Infections of House Mouse (*Mus musculus*) and Wood Mouse (*Apodemus sylvaticus*) from the Suburban Areas of Hamadan City, Western Iran. Iran J Parasitol. 2014;9(4):511-8.
33. Tena D, Simón MP, Gimeno C, Pomata MTP, Illescas S, Amondarain I, et al. Human infection with *Hymenolepis diminuta*: case report from Spain. Journal of Clinical Microbiology. 1998;36(8):2375-6.
34. Mowlavi G, Mobedi I, Mamishi S, Rezaeian M, Ashtiani MH, Kashi M. *Hymenolepis diminuta* (Rodolphi, 1819) infection in a child from Iran. Iranian Journal of Public Health. 2008;37(2):120-2.
35. Stone WB, Manwell RD. Potential helminth infections in humans from pet or laboratory mice and hamsters. Public Health Reports. 1966;81(7):647.
36. Hancke D, Suárez O. Infection levels of the cestode *Hymenolepis diminuta* in rat populations from Buenos Aires, Argentina. Journal of helminthology. 2016;90(2):199.
37. Hancke D, Suárez OV. Factors affecting helminth abundances in synanthropic rodents of an Urban environment. The Open Parasitology Journal. 2018;6(1).
38. Deplazes.P, Eichenberger.R.M., Grimm.F. Wildlife-transmitted *Taenia* and *Versteria* cysticercosis and coenurosis in humans and other primates. International Journal for Parasitology: Parasites and Wildlife. 2019;9:342-58.
39. Bathmanaban.P, Chandrawathani.P, Shi.T, Jegathesuran.T, Omar.J, Mohamed.R, et al. *Taenia Taeniaeformis* in Wild Rats. Malaysian Journal of Veterinary Research. 2016;7:21-3.