

Original Article

The Protective Effect of Turmeric against Carbimazole Induced Toxicity in Male Rats

Hussein Naser, I¹, Aziz, N. D^{1*}, Abed Al-Kareem, Z²

1. Department of Clinical Pharmacy, College of Pharmacy, University of Kerbala, Kerbala, Iraq
2. Department of Pharmacology and Toxicology, College of Pharmacy, University of Kerbala, Kerbala, Iraq

Received 14 March 2022; Accepted 7 July 2022
Corresponding Author: noor.dh@uokerbala.edu.iq

Abstract

Carbimazole is a widespread drug utilized for treating hyperthyroidism. However, carbimazole usage could be associated with adverse effects such as liver damage and nephritis in rats. At the same time, turmeric, as a medical plant, has many antioxidant effects against liver and kidney toxicity. This study aimed to explore the protective effect of turmeric against carbimazole-induced toxicity in rats. The experiment was carried out on 24 male Wistar rats. They were separated into four groups, each with six animals, as follows: 1. Control group: represents a healthy animal, and each rat is only given standard food and distilled water for 30 days. 2. Carbimazole group: drenched orally 0.5 mg carbimazole daily for 30 days. 3. Turmeric group: drenched orally 100 mg turmeric powder daily for 30 days. 4. Carbimazole and turmeric group: drenched orally carbimazole 0.5 mg and turmeric 100 mg daily for 30 days. The study demonstrated a significant effect of turmeric powder in reducing the toxicity of carbimazole in both the kidney and liver biochemical parameters, in addition to the evidence of histological sections. Turmeric powder has the ability to reduce and prevent renal and hepatic toxicity induced by carbimazole overdose, which gives turmeric medical value.

Keywords: Carbimazole, Hepatic toxicity, Rats, Renal toxicity, Turmeric

1. Introduction

Carbimazole (CBZ) is an antithyroid drug. It belongs to thionamides and is considered the most extended-acting member of this drug family (1). It is the carbethoxy derivative of methimazole. Carbimazole has the same structure as methimazole (MMI) (1-methyl-2-mercaptoimidazole) but has a different carbethoxy group linked to sulfur at position 2 of the imidazole ring, so the carbimazole is a pro-drug that rapidly converted to methimazole (2, 3). Pharmacokinetic properties of carbimazole were studied on different types of animals like domestic cats which were treated with hyperthyroidism by induction. It has a long t_{max} (6 hours) with good bioavailability (about $88\pm 11\%$) after oral administration (4). Carbimazole exerts its action

after conversion to methimazole and inhibits the production of thyroid hormone since this drug accumulates in the thyroid gland after administration. Methimazole inhibits iodination of tyrosine in thyroglobulin by acting as a substrate for thyroid peroxidase (TPO) is an enzyme in the thyroid follicle that catalyze both iodination and oxidative couple process involved in thyroid hormone production and inhibits the coupling process of monoiodinated and diiodinated tyrosine residue to form T_3 and T_4 by inhibition of thyroid peroxidase (5). Carbimazole uses, like other medications, reported several side effects, ranging from minor side effects such as gastric upset and allergic reactions to serious side effects like hepatitis (6), agranulocytosis, and jaundice (7, 8).

Carbimazole is still considered the mainstay therapy during pregnancy but still has a severe side effect on both fetus and the mother. All antithyroid drugs are associated with hepatotoxicity, this rare side effect is associated with carbimazole, and methimazole appears to impair the cholestasis process and mild periportal inflammation while the hepato cellular architecture is preserved. The incidence of this adverse effect occurs within the first 90 days of administration and can occur even a year or more after starting treatment. Some studies suggest that this side effect is more significant in older patients and consider old age a risk factor for CBZ/MMI-induced agranulocytosis. The granulocytosis and cholestasis hepatitis are rare idiosyncratic side effects of carbimazole and are usually dose and age-related (9).

2.1. Turmeric Plant

Turmeric is an herbaceous plant derived from the rhizomes of *Curcuma longa*, which belongs to the ginger family (10). The main active constituent of turmeric includes flavonoid curcumin (diferuloylmethane), which comprises 0.3-5.4 percent of raw turmeric, volatile oils, polyphenols, sesquiterpenes, diterpenes, triterpenoids, sterols, and alkaloids (11) in addition to other chemical components with different biological activity (12). Turmeric has a bright yellow color related to the presence of a fat-soluble polyphenolic pigment known as curcuminoid, and the principal curcuminoid in turmeric is curcumin. Turmeric powder is widely used in traditional medicine for gastrointestinal diseases (especially biliary and hepatic disorders), diabetic wounds, inflammation, rheumatism, anorexia, sinusitis, and cough (13). Similarly, many researchers investigate curcumin's protective effect against some pathological cases such as testicular toxicity induced by lead acetate (13) and against induced myocardium injuries. Turmeric has anti-inflammatory action due to the presence of curcumin, which exerts anti-inflammatory activity by inhibiting the number of different molecules that play roles in inflammation, such as cyclooxygenase, 5-lipoxygenase, and glutathione S – transferase. Recently,

studies have proven that turmeric has activity as anti-cancer, anti-diabetic, antioxidant, anti-inflammatory, anti-microbial, anti-fertility, hepatoprotective, nephroprotective, anti-coagulant, and also anti- HIV actions. Most of these activities are related to curcumin's presence as an active constituent (14).

2. Materials and Methods

This study was conducted on 24 male albino rats (200-300 g). They separated into four groups; each group consists of six animals maintained for September 2020 in the animal house of Pharmacy College of Kerbala University with open access to water and food ad libitum. As the following:

1. Control group was given only standard food and normal saline.
2. Carbimazole group: were given 0.5 mg carbimazole dissolved in 1ml of distilling water daily for 30 days.
3. Turmeric group: each animal was given 100 mg of turmeric powder dissolved in 1ml of distilling water daily for 30 days.
4. Carbimazole and turmeric group. Each rat in this group was given carbimazole 0.5 mg and turmeric 100 mg daily for 30 days.

The animals were monitored in their cages to elucidate clinical signs each day.

2.1. Experimental Technique

Drugs used include 0.5 mg carbimazole dissolved in 1ml of distilling water; turmeric plant powder 100 mg dissolved in 1ml of distilling water before administration to each animal in the group orally using a stomach cannula for 30 days. The animals were observed in their cages for clinical symptoms daily. At the end of the experimental period, the animals were anesthetized using chloroform, and blood was collected by cardiac puncture for serum biochemical analysis.

2.2. Determination of Biochemical Parameters

Serum was separated from clotted blood obtained by cardiac puncture. Serum enzymes aspartate aminotransferase (AST), alanine aminotransferase (ALT), alkaline phosphates (ALP), total serum

bilirubin (TSB), direct bilirubin, indirect bilirubin, and serum protein, serum uric acid, serum creatinine, and blood urea.

2.3. Preparation of Histopathological Slides

An organ such as the liver and kidney were isolated into 10% saline formalin and then subjected to histological procedures and preparation of tissue slides.

2.4. Statistical Analysis

The results were represented as the mean difference between control and other experimental groups and were tested for statistical significance using the SPSS version (20) one-way analysis of variance (ANOVA).

3. Results

The recorded data showed that carbimazole treatment significantly increased GPT (77.16 ± 11.44) and GOT (136.83 ± 15.3) compared to the control (53.16 ± 2.15), Turmeric (63.16 ± 7.9), and Turmeric Plant+Carbimazol (60.83 ± 3.63) groups (Table 1). The results revealed that turmeric and carbimazol led to a dramatic increase in the level of ALP compared to the control group (Table 1). At the same time, the results showed that in

the other parameters, there were no significant differences recorded for total bilirubin, direct bilirubin, indirect bilirubin, serum protein, uric acid, urea, and creatinine in different groups.

3.1. Histopathological Study of Tissue Slides

1- Control group: In this group, the liver section shows that the liver has a normal central vein with hepatocytes arranged radially around it, while the kidney section shows that the kidney has normal glomeruli and tubules (Figure 1).

2- Carbimazole group: in this group the liver section shows that there is significant congestion, degeneration in some hepatocytes, biliary stasis, vacuolated cytoplasm, single necrosis, and infiltrate of the inflammatory cell (neutrophils, lymphocytes, and eosinophil's) (Figure 2).

3- Carbimazole and turmeric group: the kidney section shows a decrease in congestion, while in the liver, there was a significant decrease in the inflammatory cell, necrosis, and degeneration, and regular hepatocytes plates and lobule (Figure 3).

4- Turmeric group: No remarkable pathology was seen in both liver and kidney sections (Figure 4).

Table 1. Blood Biochemical parameters

Groups	Control	Turmeric Plant	Carbimazole	Turmeric Plant +Carbimazol
GPT mean±SEM	53.16±2.15 ^a	63.16±7.9 ^a	77.16±11.44 ^b	60.83±3.63 ^a
GOT mean±SEM	109.50±8.19 ^a	104.5±4.49 ^a	136.83±15.3 ^b	104.16±6.36 ^a
ALP mean±SEM	265.50±22.40 ^a	471.66±33.90 ^b	426.16±19.82 ^b	483.00±44.16 ^b
T.bilirubin mean±SEM	0.31±0.030 ^a	0.31±0.047 ^a	0.35±0.042 ^a	0.33±0.042 ^a
Direct bilirubin mean±SEM	0.045±0.006 ^a	0.046±0.009 ^a	0.047±0.009 ^a	0.046±0.006 ^a
Indirect bili mean±SEM	0.33±0.026 ^a	0.37±0.044 ^a	0.30±0.042 ^a	0.28±0.038 ^a
Protein mean±SEM	0.28±0.038 ^a	0.28±0.013 ^a	0.28±0.031 ^a	0.28±0.048 ^a
Uric acid mean±SEM	0.81±0.072 ^a	0.74±0.090 ^a	1.09±0.079 ^b	0.82±0.075 ^a
Urea mean±SEM	35.16±2.30 ^a	39.83±1.27 ^a	45.83±1.62 ^b	40.00±1.34 ^a
Creatinine mean±SEM	0.29±0.004 ^a	0.33±0.033 ^a	0.30±0.025 ^a	0.33±0.021 ^a

Results with superscripts (a, b) between study groups were considered significantly different ($P \leq 0.05$)

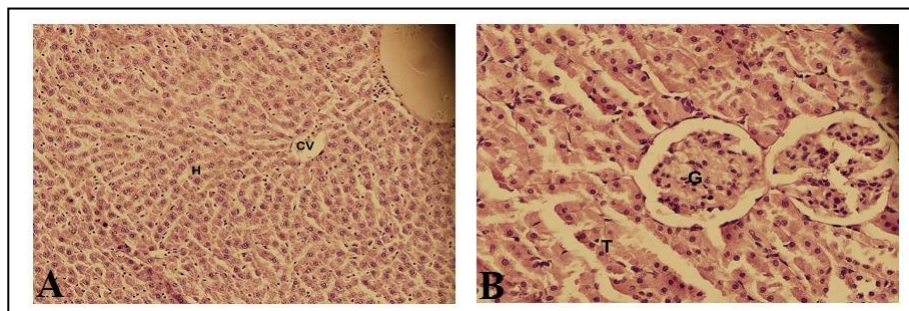


Figure 1. **A)** Cross section of the liver in the control group showed CV: central vein, H: hepatocytes (40×). **B)** Cross section of kidney in the control group showed G: normal structure of glomeruli, T: tubules. (40×)

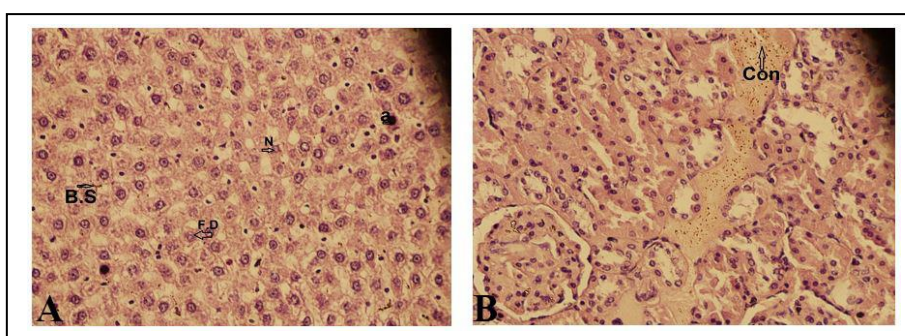


Figure 2. **A)** Cross section of the liver in the carbimazole group showed N: necrosis, a: apoptotic body, B.S: biliary stasis, F.D: focal degeneration (40×). **B)** Cross section of kidney in carbimazole group showed Con: congestion in renal tubule (40×)

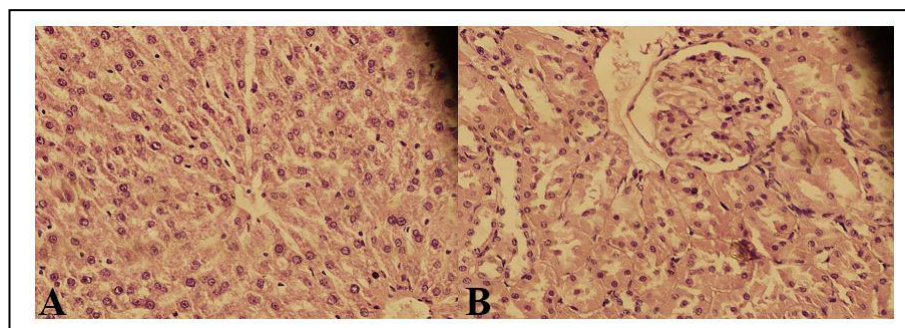


Figure 3. **A)** Liver cross section in (carbimazole+turmeric) shows a decrease in necrosis, degeneration, and the availability of inflammatory cells. 40×. **B)** Cross section of the kidney in (carbimazole+turmeric) shows the response to treatment by the absence of congestion and inflammation. (40×)

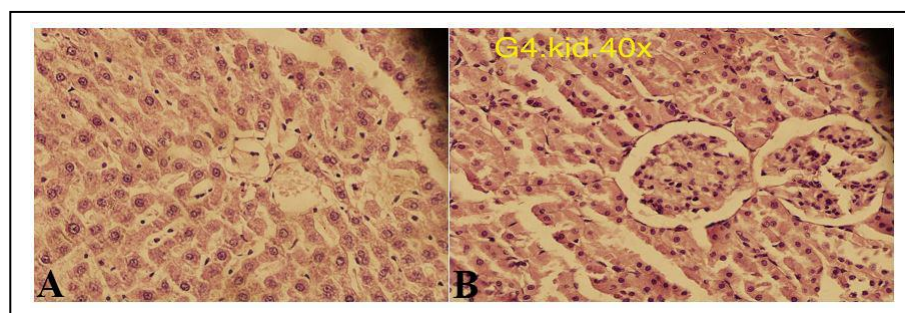


Figure 4. **A)** Cross liver section 40× in the turmeric group shows no remarkable pathology. **B)** Kidney section 40× in the turmeric group shows normal kidney tubules and glomeruli

4. Discussion

A huge number of studies showed that carbimazole overdose has a negative impact on renal and hepatic cells in addition to other systems. Several studies and research have documented the toxic effect of carbimazole on renal and liver cells in different academic areas. Liver damage caused by carbimazole could be observed by measuring the level of hepatic enzymes since the elevation in these enzymes more than the normal range reveals something incorrect, which may be related to the destruction of hepatic cells and diffusing of enzymes and other cell components outside the cell.

The results of this study demonstrate the activity of the curcumin in preventing and treating the toxicity of hepatic and renal organs, which represent the most vital organs in the body, and this is in agreement with the results of other scientists like Kheradpezhoh, Panjehshahin (15) where they used acetaminophen to induce toxicity and note that curcumin plays a crucial role in reducing toxicity.

Table 1 shows abnormal elevation in liver enzymes in the carbimazole group caused by the damage in the cell membrane of hepatocyte; this can be explained by the hypothesis that carbimazole cause hepatic damage by oxidative stress, which is proved by histological results such as inflammation, necrosis, degeneration, and congestion (16).

In general, carbimazole causes oxidative stress by irreversible inactivation of different peroxidases with heme groups at the active center involved in hydrogen peroxide scavenger. On the other hand, the liver is an organ with a high metabolic rate and generates reactive oxygen species (ROS) at a high level, which contributes to the oxidative stress process (17). It was proposed that the active form of carbimazole (MMI) inactivates the heme group of peroxidase enzyme involved in the hydrogen peroxide scavenger. MMI reduces catalase-peroxidase activity in the liver by inactivation of the catalytic center of catalase (18).

Physiologically, the presence of antioxidant enzymes such as peroxidase and dismutase prevents oxidative stress and tissue damage, any xenobiotic disrupted physiological steady state that alters the intracellular redox environment causes cellular damage because of ROS generation and consequently lipid peroxidation (18).

On the other hand, other studies reported that glyoxal, an onther metabolite of methimazole, also plays a critical role in carbimazole-induced hepatotoxicity (19).

Disturbance in the antioxidant system could cause an increase in oxidant reaction and cellular damage by hydrogen peroxide that participates in Fenton and Harber-Weiss reaction in both the cells that produce it and the neighboring cell because hydrogen peroxide diffuses through the cell membrane (20).

The results show the effect of turmeric in reducing the hepatic parameter such as a liver enzyme (ALT, AST) in (the turmeric+carbimazole) group when compared with the carbimazole group. This means that the turmeric plant may have activity in reducing the hepatotoxicity caused by carbimazole overdose. Several studies reported that turmeric's therapeutic effect results from the ability of curcumin (the main active constituent) to act as an antioxidant and anti-inflammatory. Curcumin acts as an antioxidant by scavenger of oxygen free radicals and decreases lipid peroxidation in rats' liver microsomes by maintaining the activity of antioxidant enzyme-like (superoxide, dismutase, catalase, glutathione, and peroxidase), also inducing heme-oxygenase-1 enzyme in case of liver injury.

The anti-inflammatory effect of turmeric is by decreasing the formation of pro-inflammatory cytokines such as cyclooxygenase 5-lipoxygenase (21). These are essential enzymes in synthesizing Prostaglandin and leukotriene, respectively, responsible for many human disorders. The results of this study agree with other studies carried out in various research and scientific centers, like the study of Aggarwal and

Harikumar (22) and the study of Vaiserman, Koliada (23) in Ukraine.

This study examines the ability of turmeric to recover renal damage caused by drug overdoses like carbimazole or other chemicals. Statistical analysis of the present study has shown insignificant changes (slight increase) in some liver markers, such as total bilirubin, direct and indirect bilirubin, and serum protein. Serum uric acid and urea significantly increased in the carbimazole group compared to other groups, while other markers like creatinine were slightly affected. Histopathological analysis of liver sections (Figure 2A) reveals significant congestion, degeneration in some hepatocyte, biliary stasis, necrosis, and infiltration of the inflammatory cell (neutrophils, lymphocytes, and eosinophils), while figure 3A show a significant decrease in necrosis, degeneration and the availability of inflammatory cell as a response to turmeric. The kidney section (Figure 2B) explain clearly the congestion of renal tubules damage caused by carbimazole toxicity and the recovery of these tubules after ingestion of turmeric powder (Figures 3B and 4B), and these results are supported by the finding of other scientists like Ulubay, Alkan (24).

Turmeric has a protective effect against liver and kidney toxicity induced by carbimazole because the turmeric plant contains curcumin which is the main active constituent and has many pharmacologic actions such as antioxidant and anti-inflammatory.

Authors' Contribution

Study concept and design: I. H. N., N. D. A. and Z. A. A.

Acquisition of data: I. H. N.

Analysis and interpretation of data: N. D. A. and Z. A. A.

Drafting of the manuscript: Z. A. A.

Critical revision of the manuscript for important intellectual content: N. D. A.

Statistical analysis: I. H. N.

Administrative, technical, and material support: I. H. N.

Ethics

The study was conducted after obtaining approval from the ethics committee of the college of the pharmacy, University of Kerbala.

Conflict of Interest

The authors declare that they have no conflict of interest.

References

1. Furman BL. Antithyroid Agents. 2016.
2. Kadhim S, Musa A, Abed Al-Kareem Z, Ubaid M, Aziz N. The analysis of the protective feature of *Nigella sativa* in reducing Carbimazole toxicity including liver and kidney parameters on Albino male rats. *Sci J Med Res.* 2018;2(5):14-8.
3. Skellern G, Knight B, Low C, Alexander W, McLarty D, Kalk W. The pharmacokinetics of methimazole after oral administration of carbimazole and methimazole, in hyperthyroid patients. *Br J Clin Pharmacol.* 1980;9(2):137-43.
4. Frenais R, Burgaud S, Horspool L. Pharmacokinetics of controlled-release carbimazole tablets support once daily dosing in cats. *J Vet Pharmacol Ther.* 2008;31(3):213-9.
5. Cooper DS. Antithyroid drugs. *N Engl J Med.* 2005;352(9):905-17.
6. Kota SK, Meher LK, Kota SK, Jammula S, Modi KD. Carbimazole-induced cholestatic hepatitis in Graves' disease. *Indian J Endocrinol Metab.* 2013;17(2):326.
7. Jain K, Chakrapani M, Smitha K. Acute cholestatic hepatitis along with agranulocytosis: a rare side effect of carbimazole. *Ann Afr Med.* 2010;9(2).
8. NEKI N, Aloona S. Cholestatic Jaundice Induced by Sequential Carbimazole and Propylthiouracil Treatment for Thyrotoxicosis-A Case Report. *Hong Kong Med J.* 2013;9(5):377-80.
9. Francis T, Francis N, Lazarus JH, Okosieme OE. Safety of antithyroid drugs in pregnancy: update and therapy implications. *Expert Opinion on Drug Safety.* 2020;19(5):565-76.
10. Chattopadhyay I, Biswas K, Bandyopadhyay U, Banerjee RK. Turmeric and curcumin: Biological actions and medicinal applications. *Curr Sci.* 2004;87:44-53.
11. Gupta SC, Sung B, Kim JH, Prasad S, Li S, Aggarwal BB. Multitargeting by turmeric, the golden

- spice: from kitchen to clinic. *Mol Nutr Food Res*. 2013;57(9):1510-28.
12. Niranjan A, Prakash D. Chemical constituents and biological activities of turmeric (*Curcuma longa* L.)-a review. *J Food Sci Technol*. 2008;45(2):109.
 13. Sudjarwo SA, Giftania Wardani Sudjarwo K. Protective effect of curcumin on lead acetate-induced testicular toxicity in Wistar rats. *Res Pharm Sci*. 2017;12(5):381.
 14. Liu H, Wang C, Qiao Z, Xu Y. Protective effect of curcumin against myocardium injury in ischemia reperfusion rats. *Pharm Biol*. 2017;55(1):1144-8.
 15. Kheradpezhoh E, Panjehshahin M-R, Miri R, Javidnia K, Noorafshan A, Monabati A, et al. Curcumin protects rats against acetaminophen-induced hepatorenal damages and shows synergistic activity with N-acetyl cysteine. *Eur J Pharmacol*. 2010;628(1-3):274-81.
 16. Cano-Europa E, Blas-Valdivia V, Franco-Colin M, Gallardo-Casas CA, Ortiz-Butrón R. Methimazole-induced hypothyroidism causes cellular damage in the spleen, heart, liver, lung and kidney. *Acta Histochemica*. 2011;113(1):1-5.
 17. Li S, Tan H-Y, Wang N, Zhang Z-J, Lao L, Wong C-W, et al. The role of oxidative stress and antioxidants in liver diseases. *Int J Mol Sci*. 2015;16(11):26087-124.
 18. Zhu R, Wang Y, Zhang L, Guo Q. Oxidative stress and liver disease. *Hepatol Res*. 2012;42(8):741-9.
 19. Heidari R, Babaei H, Roshangar L, Eghbal MA. Effects of enzyme induction and/or glutathione depletion on methimazole-induced hepatotoxicity in mice and the protective role of N-acetylcysteine. *Adv Pharm Bull*. 2014;4(1):21.
 20. Heidari R, Babaei H, Eghbal M. Mechanisms of methimazole cytotoxicity in isolated rat hepatocytes. *Drug Chem Toxicol*. 2013;36(4):403-11.
 21. Menon VP, Sudheer AR. Antioxidant and anti-inflammatory properties of curcumin. The molecular targets and therapeutic uses of curcumin in health and disease: Springer; 2007. p. 105-25.
 22. Aggarwal BB, Harikumar KB. Potential therapeutic effects of curcumin, the anti-inflammatory agent, against neurodegenerative, cardiovascular, pulmonary, metabolic, autoimmune and neoplastic diseases. *Int J Biochem Cell Biol*. 2009;41(1):40-59.
 23. Vaiserman A, Koliada A, Zayachkivska A, Lushchak O. Curcumin: A therapeutic potential in ageing-related disorders. *PharmaNutrition*. 2020:100226.
 24. Ulubay M, Alkan I, Yurt KK, Kaplan S. The protective effect of curcumin on the diabetic rat kidney: A stereological, electron microscopic and immunohistochemical study. *Acta Histochemica*. 2020;122(2):151486.