

Original Article

Comparative Study of Clinical Examinations, Necropsy Findings, and X-Ray Signs in Naturally Infected Pigeons to Avian Tuberculosis

Darya Bagherian Koshkghazi¹, Nader Mosavari², Kaveh Parvandar Asadollahi^{1*}

1. Department of Clinical Sciences, Faculty of Veterinary Medicine, Science and Research Branch, Islamic Azad University, Tehran, Iran.
2. Department of Tuberculosis, Razi Vaccine & Serum Research Institute, Hesarak, Karaj, Iran.

How to cite this article: Darya Bagherian Koshkghazi, Nader Mosavari, Kaveh Parvandar Asadollahi. Comparative Study of Clinical Examinations, Necropsy Findings, and X-Ray Signs in Naturally Infected Pigeons to Avian Tuberculosis. *Archives of Razi Institute*. 2025;80(2):609-616. DOI: 10.32592/ARI.2025.80.2.609



Copyright © 2023 by



Razi Vaccine & Serum Research Institute

Article Info:

Received: 9 June 2024

Accepted: 8 September 2024

Published: 30 April 2025

Corresponding Author's E-Mail:

kaveh_parvandar@yahoo.com

ABSTRACT

Mycobacterium avium subsp. *avium* is the primary cause of avian tuberculosis, a chronic disease affecting many bird species. Depending on the infected organs, the clinical manifestations of the disease are usually nonspecific and variable. The growing risk of the disease spreading to the humans has made diagnosing it in birds more important. Therefore, the present study investigated avian tuberculosis infection in several domestic pigeon's lofts in Markazi Province, Iran. Twelve pigeons from different suspected pigeon lofts were collected, fed properly, and kept under suitable conditions. After recording clinical manifestations, the pigeons underwent radiographic imaging in lateral and ventrodorsal positions. Then, the pigeons were euthanized and subjected to necropsy examinations. During necropsy examinations, samples taken from any visible lesions. If no lesions were present, samples were taken from the liver and delivered to the tuberculosis reference laboratory for culturing in LJG, LJP, H, and HM culture media. Finally, the grown colonies were tested using Polymerase Chain Reaction (PCR) with the primers targeting 16S rRNA, IS1245, and IS901. The most prominent clinical manifestations in the infected pigeons were cachexia and articular swelling of the wings and legs, while the most common radiographic findings were periarticular inflammation and Renomegaly. Moreover, nodules and lesions in the liver, the gastrointestinal tract, and the abdominal cavity were the most prevalent in the necropsy findings. Culture, Ziehl-Neelsen staining results, and PCR test results confirmed that all 12 pigeons were infected with *Mycobacterium avium* subsp. *avium*. Also, the radiographic and necropsy findings demonstrated the destructive effects of avian tuberculosis on the infected pigeons.

Keywords: Avian Tuberculosis, *Mycobacterium Avium* Subspecies *Avium*, Pigeon, Markazi Province.

1. Introduction

Avian tuberculosis is a critical, chronic, and debilitating disease that affects a wide variety of avian species, including wild and domestic birds, throughout the year (1, 2). In most cases, the related pathogens are *Mycobacterium avium* and *Mycobacterium genavense* (3). Depending on the infected organs, the clinical manifestations of the disease are usually nonspecific and variable. Infected birds may exhibit symptoms such as diarrhea, cachexia, and pectoral muscle atrophy. Necropsy examinations reveal the development of tuberculosis nodules in internal organs such as the intestines, liver, spleen, and lungs. Infected birds may die within months. However, some birds in apparently favorable body condition may experience sudden death due to internal hemorrhaging caused by ruptured hepatic or spleen blood vessels (1, 4). As previously mentioned, infection with the *Mycobacterium avium* complex (MAC) does not present with any specific clinical manifestations. Thus, diagnosing infection with these pathogens, especially *M. avium* subsp. *avium*, is challenging and requires confirmation using bacterial culture, Ziehl-Neelsen staining, and a PCR test (5). *Mycobacteria* can be transmitted through contaminated soil, ingestion of contaminated water or food, inhalation, and, in some cases, cutaneous invasion (1, 6). Birds infected with *M. avium* subsp. *avium* can survive for an extended time while acting as carriers and excreting the bacilli in their feces, thereby spreading the infection to other birds and humans. As the most important source of infection, the feces of infected birds contain numerous bacilli that can contaminate soil, water, and the environment. Studies show that the bacilli can survive in soil for up to four years. In addition to birds, *M. avium* can infect other pets and humans (1, 7). Members of the MAC are classified as Risk Group 2 for humans and should be handled appropriately. They pose a particular risk to immunocompromised patients who keep infected birds or eat their undercooked meat (1). Most people infected with *M. avium* subsp. *avium* report having kept domestic birds at home (8). On the other hand, keeping pigeons is quite popular in Iran. Considering the importance of this zoonotic disease and the essential role of birds in spreading it in nature and urban areas, this study aims to investigate avian tuberculosis in pigeon lofts in Markazi Province, Iran.

2. Materials and Methods

Investigations were carried out in ten pigeon lofts in Markazi Province. Two lofts (with a total of 55 pigeons) were suspected of having avian tuberculosis. The pigeons from the suspected lofts underwent clinical examinations, and 12 pigeons exhibiting clinical signs of the disease were selected. The birds were fed properly and kept under suitable conditions for two weeks to acclimate for further serological testing. Their clinical manifestations were recorded during this time. Then, all pigeons underwent radiographic imaging using a CR Classic (DC-12M, Toshiba, Japan) in lateral and ventrodorsal positions at Tehran University's veterinary hospital. The suspected birds

were euthanized, underwent necropsy, and the necropsy findings were recorded. Additionally, specimens were prepared from tissues with lesions, including the liver, lungs, heart, and gastrointestinal tract. If no lesions were found, sampling was performed on the liver. The specimens were placed next to dry ice in a screw-cap container and delivered to the tuberculosis reference laboratory at the Razi Vaccine and Serum Research Institute for culture and definitive diagnosis.

2.1. Culture

A small piece of each specimen was taken with a scalpel and ground in a sterile mortar with sterile sand at the tuberculosis reference laboratory. The homogenized mixtures were then decontaminated using the NALC (N-acetylcytisine)-NaOH method (9). The inoculums were cultured on four culture slopes, including glycerinated Lowenstein-Jensen (LJG) medium, pyruvate-enriched Lowenstein-Jensen (LJP) medium, mycobactin J-supplemented Herrold-egg yolk (HM) medium, and plain Herrold-egg yolk (HM) medium (10). The culture media were kept in an incubator at 37°C for 8-10 weeks. After the first colonies formed, the slides were stained using the Ziehl-Neelsen method and observed under an optical microscope (11).

2.2. PCR

After staining, gene extraction was performed using the van Soolingen et al. method (12). The purity of the specimens was evaluated using a NanoDrop device. The specimens were then prepared for PCR using 16S rRNA, IS1245, and IS901 primers to detect mycobacteria, *M. avium*, and *M. avium* subsp. *avium*, respectively. After electrophoresis, the pattern was photographed using a Bio-Rad gel documentation system (Bio-Rad, TX, USA).

3. Results

3.1. Clinical Findings

The most common clinical manifestations were cachexia, swelling of the joints in the legs and wings, ocular and periocular involvement, beak deformity, and subcutaneous nodules (Figures 1, 2, 3, 4) (Table 1). Regarding joint swelling, infected pigeons had more wing joint swelling than leg swelling.

3.2 Radiographic Findings

The most common radiographic findings were periarticular inflammation, followed by renomegaly, polyostotic lesions, hepatomegaly, air sacculitis, pneumonia, and gastroenteropathy (Figure 5) (Table 2).

3.3 Necropsy findings

Necropsy findings included lesions and nodules in the liver, followed by in the gastrointestinal tract, abdominal cavity, heart, and lungs (Figures 6, 7, 8, 9) (Table 3).

3.4 Isolation and Molecular Identification

Colony growth was observed in all culture media. However, less growth was observed in LP media than in the other culture media. All isolates were acid-fast bacilli in Ziehl-Neelsen staining. The AFB isolates were examined using the PCR method with 16S rRNA, IS1245, and IS901

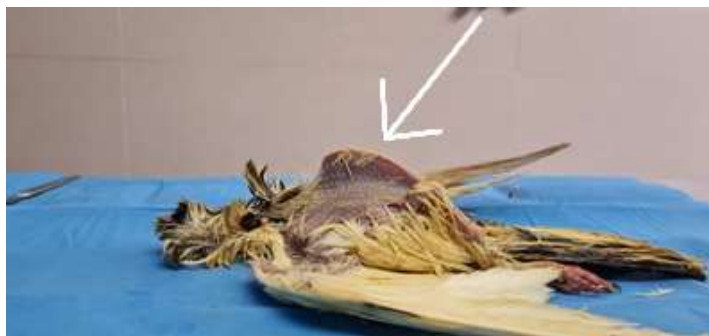

Figure 1. Cachectic pigeon, pectoral muscle atrophy.

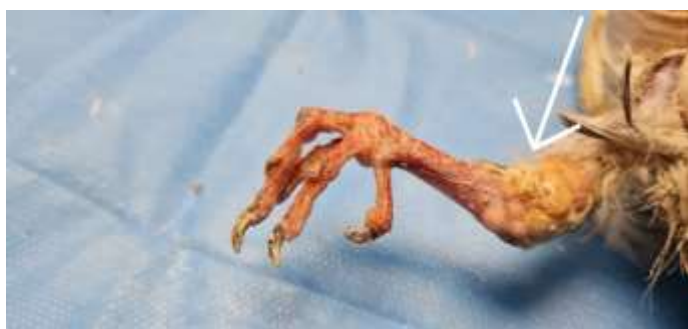

Figure 2. Tubercular lesions and joint swelling in the leg.

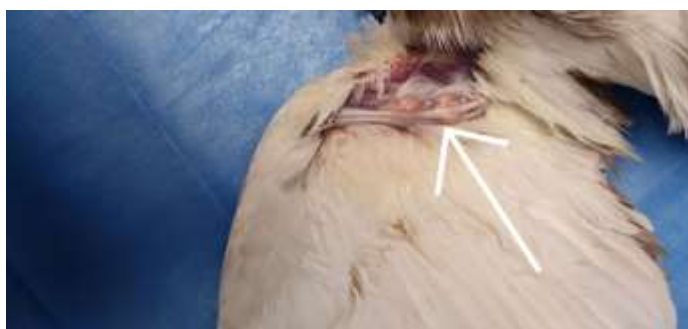

Figure 3. Tubercular lesions and swelling in the wing joint.

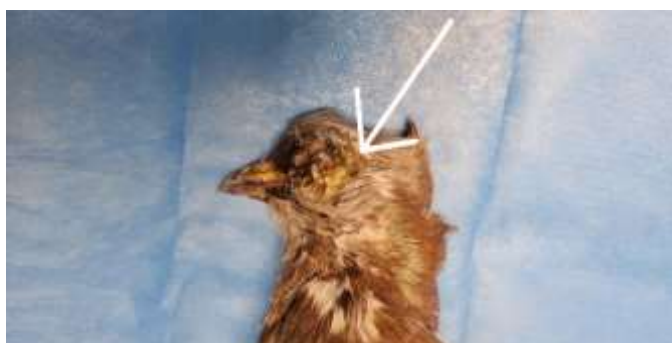

Figure 4. Ocular lesion and periocular nodules.

Table 1. Prevalence of clinical manifestations in the infected pigeons.

Clinical manifestations	number (out of 12)	Percentage (%)
Cachexia	11	91.66%
Articular swelling in legs and wings	11	91.66%
Ocular and periocular involvement	7	58.33%
Beak deformity	2	16.66%
Subcutaneous nodule	1	8.33%

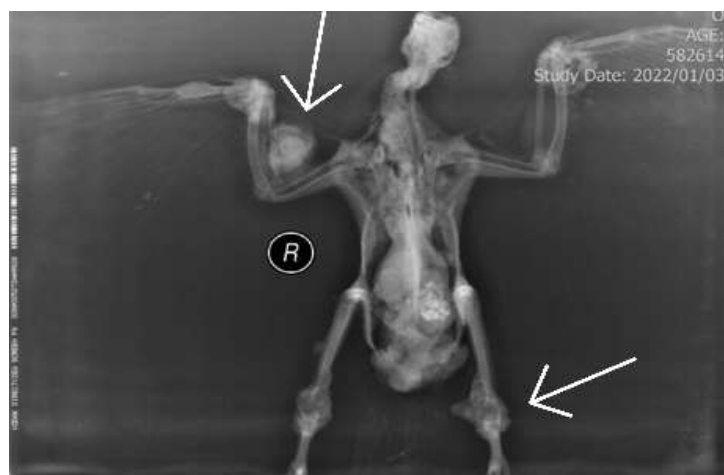

Figure 5. Radiographic image of a pigeon suspected of tuberculosis in the V.D position, showing polyostotic lesions and articular swelling in legs and wings.

Table 2. Prevalence of radiographic findings in pigeons suspected with tuberculosis.

Radiographic findings	number (out of 12)	Percentage (%)
Peri-articular inflammation	8	66.66%
Renomegaly	7	58.33%
Polyostotic lesions	7	58.33%
Hepatomegaly	6	50%
Air sacculitis	6	50%
Pneumonia	3	25%
Gastroenteropathy	2	16.66%

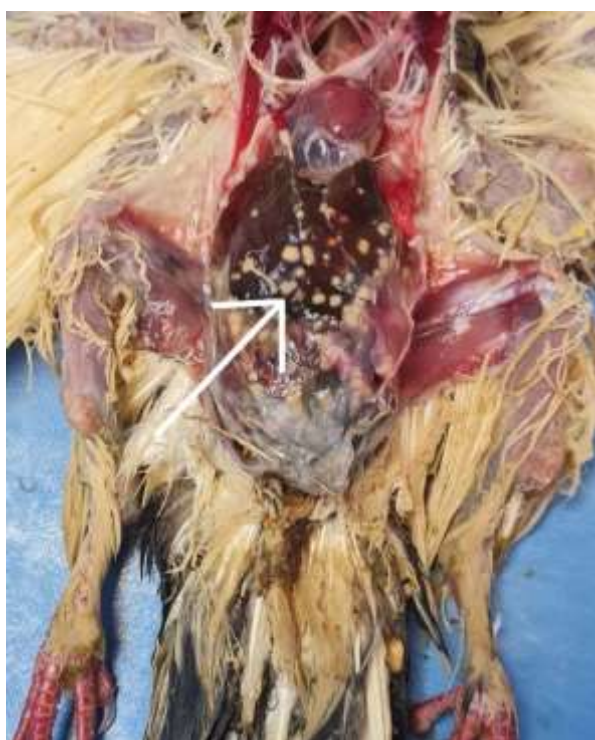

Figure 6. Hepatic lesions.

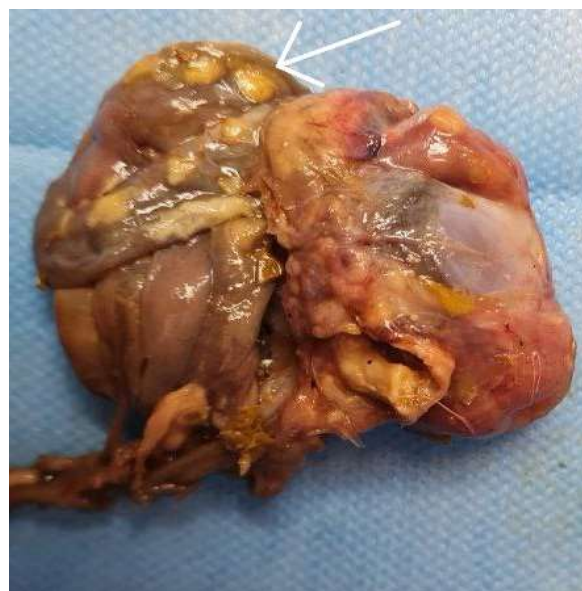

Figure 7. Lesions in the gastrointestinal tract.

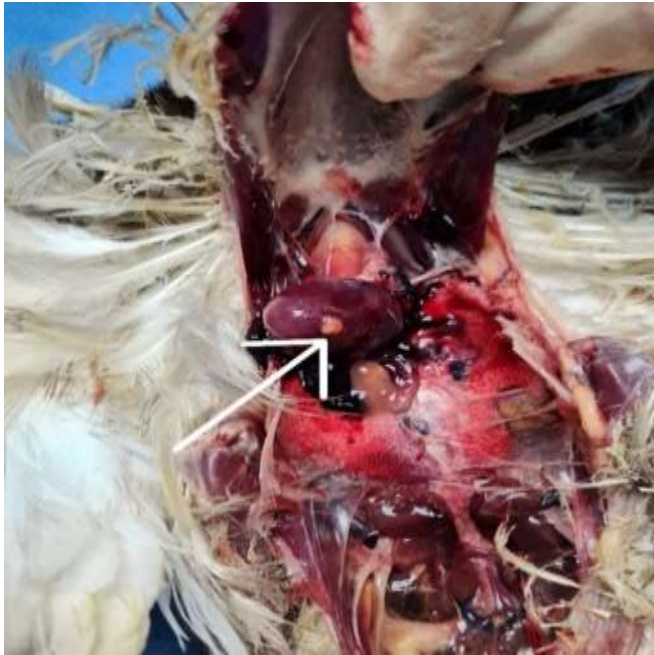

Figure 8. Lesions on heart.

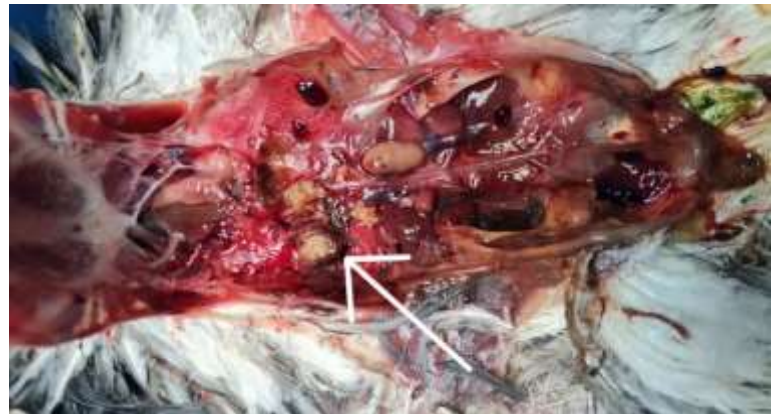

Figure 9. Pulmonary lesions.

Table 3. Prevalence of lesions in necropsy findings in pigeons suspected of tuberculosis.

necropsy findings	number (out of 12)	Percentage (%)
lesions and nodules in the liver	7	58.33%
lesions and nodules in the gastrointestinal tract and abdominal cavity	7	58.33%
Lesions and nodules on the heart	4	33.33%
Lesions and nodules in the lungs	3	25%

primers for molecular identification. The PCR results confirmed that all 12 pigeons were infected with *Mycobacterium avium* subsp. *avium* (Figures 10, 11, 12).

4. Discussion

Culture, staining, and PCR results of samples taken from all 12 pigeons confirmed their infection with *Mycobacterium avium* subsp. *avium*. The most prominent clinical manifestations in the infected pigeons were cachexia and articular swelling. The most common radiographic findings were periarticular inflammation, renal enlargement, and polyostotic lesions. Additionally, necropsy findings revealed the presence of the most lesions and nodules in the liver and gastrointestinal system. According to our findings, avian tuberculosis can severely affect the gastrointestinal systems of infected birds, which is consistent with previous studies. Several studies have reported that avian mycobacteriosis lesions include yellowish-gray nodules of various sizes and shapes, commonly found in the liver, spleen, and intestines. The ovaries, heart, testes, conjunctiva, skin, lungs, and bone marrow may also be affected, though less frequently. The present study showed

that birds infected with avian tuberculosis had necropsy findings and lesion prevalence similar to those in other studies (3, 4, 13). Parvandar et al. showed in their study that articular swelling of the legs and wings, as well as cachexia, were the most prominent clinical manifestations, and that the liver and gastrointestinal system were the most affected organs in necropsy findings in naturally infected pigeons. These findings are consistent with those of the present study (10). Additionally, Debelu et al. demonstrated in their study of the epidemiology of avian tuberculosis in selected districts of the Oromia Region of Ethiopia that the liver and gastrointestinal system were the most affected organs. The findings of this study are consistent with our results regarding the destructive consequences of avian tuberculosis on the gastrointestinal system of pigeons (14). Furthermore, Mayahi et al. (15) in a histopathology study of avian tuberculosis in naturally infected domestic pigeons with *Mycobacterium avium* subsp. *avium*, demonstrated that most granulomatous lung lesions were microscopic, indicating that the lungs were affected more severely than expected. Therefore, more affected lungs may be observed in the current study's histopathology examination than




Figure 10. PCR analysis. The 543 bp specific fragment from 16S rRNA primer. From left: ladder (L, DNA size marker 100 base pair ladder), positive control (P, *M. avium* subspecies *avium* strain D4), negative control (N, distilled water), samples (S1-S12), positive control, ladder.

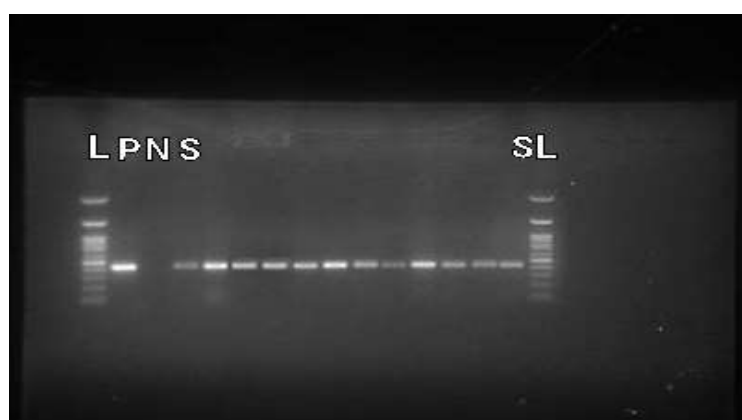


Figure 11. PCR analysis. The 427 bp specific fragment from IS1245 primer. From left: ladder (L, DNA size marker 100 base pair ladder), positive control (P, *M. avium* subspecies *avium* strain D4), negative control (N, distilled water), samples (S1-S12), ladder.

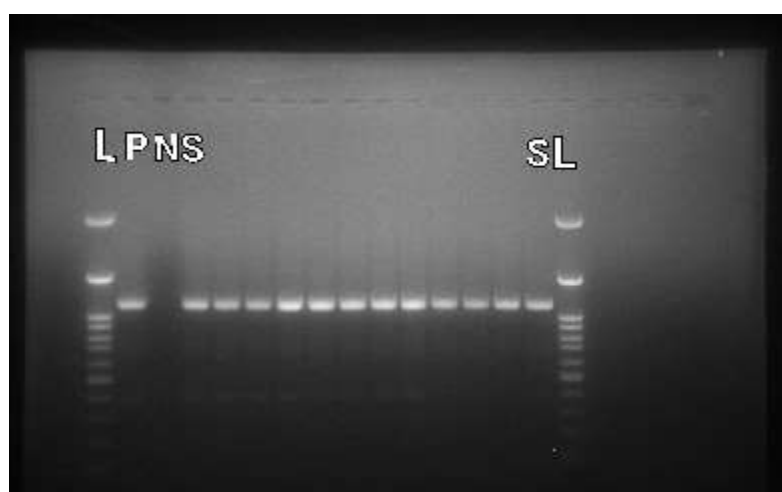


Figure 12. PCR analysis. The 1108 bp specific fragment from IS901 primer. From left: ladder (L, DNA size marker 100 base pair ladder), positive control (P, *M. avium* subspecies *avium* strain D4), negative control (N, distilled water), samples (S1-S12), ladder.

expected (16). A study by Jordan et al. that was similar to the present study reported clinical manifestations such as gradual weight loss, cachexia, lameness, and diarrhea in infected birds (17). Despite having a normal appetite, the infected birds eventually developed severe cachexia and pectoral muscle atrophy. Furthermore, the infected birds died within months. However, some birds with apparently favorable body conditions experienced sudden death due to internal hemorrhaging caused by ruptured hepatic or spleen blood vessels. The present study also reported that cachexia, whether mild or severe, was the most prominent clinical manifestation in 11 out of 12 birds. Thus, the findings of the Jordan et al. study were compatible with the current study regarding the development of cachexia in infected birds. According to our findings, avian tuberculosis can lead to several pathological symptoms, indicating its destructive effect on infected pigeons. Due to the disease's zoonotic nature, we recommend monitoring all pigeon lofts and practicing biosecurity measures to control it.

Acknowledgment

We would like to express our sincere gratitude to the Tuberculin Department staff at Razi Vaccine and Serum Research Institute for their kind assistance.

Authors' Contribution

Study concept and design: K.P.A.
Acquisition of data: D.B.K., N.M. and K.P.A.
Analysis and interpretation of data: K.P.A. and D.B.K.
Drafting of the manuscript: D.B.K. and K.P.A.
Critical revision of the manuscript for important intellectual content: K.P.A.
Statistical analysis: D.B.K. and K.P.A.
Administrative, technical, and material support: N.M., D.B.K. and K.P.A.
Study supervision: K.P.A.

Ethics

This study was approved by the Ethics Committee of the Science and Research Branch of the Islamic Azad University in Tehran, Iran (IR.IAU.SRB.REC.1401.106).

Conflict of Interest

The authors declare that they have no conflicts of interest.

Funding/Support

This work was financially supported by Razi Vaccine and Serum Research Institute in Karaj, Iran.

Data Availability

The data supporting the findings of this study are available from the corresponding author upon request.

References

1. Algammal AM, Hashem HR, Al-Otaibi AS, Alfifi KJ, El-Dawody EM, Mahrous E, et al. Emerging MDR-*Mycobacterium avium* subsp. *avium* in house-reared domestic birds as the first report in Egypt. *BMC microbiology*. 2021;21:1-11.
2. Taira N, Kawasaki H, Takahara S, Chibana K, Atsumi E, Kawabata T. The presence of coexisting lung cancer and non-tuberculous mycobacterium in a solitary mass. *The American Journal of Case Reports*. 2018;19:748.
3. Dhama K, Mahendran M, Tiwari R, Dayal Singh S, Kumar D, Singh S, et al. Tuberculosis in birds: insights into the *Mycobacterium avium* infections. *Veterinary Medicine International*. 2011;2011(1):712369.
4. Tsiouris V, Kiskinis K, Mantzios T, Dovas CI, Mavromati N, Filiouis G, et al. Avian mycobacteriosis and molecular identification of *Mycobacterium avium* Subsp. *avium* in racing pigeons (*Columba livia domestica*) in Greece. *Animals*. 2021;11(2):291.
5. Algammal AM, Wahdan A, Elhaig MM. Potential efficiency of conventional and advanced approaches used to detect *Mycobacterium bovis* in cattle. *Microbial pathogenesis*. 2019;134:103574.
6. Kham-Ngam I, Chetchotisakd P, Ananta P, Chaimanee P, Sadee P, Reechaipichitkul W, et al. Epidemiology of and risk factors for extrapulmonary nontuberculous mycobacterial infections in Northeast Thailand. *PeerJ*. 2018;6:e5479.
7. Kindu A, Getaneh G. Prevalence of avian tuberculosis in domestic chickens in selected sites of Ethiopia. *J Vet Sci Technol*. 2016;7(377):2.
8. Babacan O, Bülent B, Sareyyüpoğlu B. PCR detection of *Mycobacterium genavense* DNA in fecal samples of caged birds. *Ankara Üniversitesi Veteriner Fakültesi Dergisi*. 2020;67(2):201-4.
9. Pfyffer G, Brown-Elliott B, Wallace Jr R. *Mycobacterium*: general characteristics, isolation, and staining procedures. *Manual of clinical microbiology*. 2003;1:532-59.
10. Parvandar-Asadollahi K, Mosavari N, Mayahi M. Genotyping of *Mycobacterium avium* subsp. *avium* isolates from naturally infected lofts of domestic pigeons in Ahvaz by IS901 RFLP. *Iranian journal of microbiology*. 2015;7(5):260.
11. Tell LA, Foley J, Needham ML, Walker RL. Diagnosis of avian mycobacteriosis: comparison of culture, acid-fast stains, and polymerase chain reaction for the identification of *Mycobacterium avium* in experimentally inoculated Japanese quail (*Coturnix coturnix japonica*). *Avian Diseases*. 2003;47(2):444-52.
12. Huard RC, de Oliveira Lazzarini LC, Butler WR, van Soolingen D, Ho JL. PCR-based method to differentiate the subspecies of the *Mycobacterium*

- tuberculosis complex on the basis of genomic deletions. *Journal of clinical microbiology*. 2003;41(4):1637-50.
13. Brugère-Picoux J, Vaillancourt J-P, Shivaprasad H, Venne D, Bouzouaia M. *Manuel de pathologie aviaire*: AFAS; 2015.
 14. Kriz P, Slana I, Kralik P, Babak V, Skoric M, Fictum P, et al. Outbreak of *Mycobacterium avium* subsp. *avium* infection in one flock of domestic pigeons. *Avian Diseases*. 2011;55(3):503-8.
 15. Mayahi M, Esmailzadeh S, Mosavari N, Parvandar Asadollahi K. Histopathological study of avian tuberculosis in naturally infected domestic pigeons with *Mycobacterium avium* subsp. *avium*. *Iranian Journal of Veterinary Science and Technology*. 2013;5(1):45-56.
 16. Debelu T, Abunna F, Mamo Kassa G, Ameni G. Epidemiology of avian tuberculosis in selected districts of Oromia Region, Ethiopia. *Veterinary Medicine International*. 2022;2022(1):6933701.
 17. Jordan FT, Hampson DJ. Some other bacterial diseases. *Poultry Diseases*. 2008;5:213-18.