

Original Article

Effect of Palm Pollen and Pomegranate Peel Supplementation on Sperm Development in Male Rabbits

Abdulameer, A. K¹, Alkhayat, A. S², Talib Abbas, M³, Habeeb, I. A⁴, Sabah Bustani, G^{5,6*}

1. Department of Theriogenology, College of Veterinary Medicine, University of Kufa, Kufa, Iraq

2. Medical Laboratory Technology Department, College of Medical Technology, The Islamic University, Najaf, Iraq

3. Department of Surgery and Obstetrics, College of Veterinary Medicine, AL_Qasim Green University, Al Qasim, Iraq

4. Department of Theriogenology, College of Veterinary Medicine, University of Basrah, Basrah, Iraq

5. College of Nursing, Altoosi University College, Najaf, Iraq

6. College of Dentistry, The Islamic University, Najaf, Iraq

Received 26 January 2022; Accepted 30 April 2022

Corresponding Author: jalal.2t@yahoo.com

Abstract

The use of plants, plant extracts, and folk remedies for the treatment of human diseases has been known as traditional medicine. It is approved that the use of herbal medicine dates far back to 60,000 years ago in Iraq. This study aimed to investigate the possible effects of pomegranate and palm pollen, as two powerful herbal remedies with antioxidant, anti-inflammatory, and anti-bacterial effects, on fertility in the male rabbits. A total of 15 healthy New Zealand White male adult rabbits were randomly assigned to three groups (n=5 in each group). Group A: 5 rabbits did not receive herbal treatment (control group). Group B: 5 rabbits were treated with palm pollen at a dose of 2 g by oral gavage daily. Group C: 5 rabbits were treated with pomegranate peel (2 g) treated by oral gavage daily. All animals were euthanized 90 days after the beginning of the experiment. Following the euthanasia, the testis was removed. For sperm recovery, the epididymis was dissected from the testicles and the tail of the epididymis was minced in the sperm washing medium and incubated for 15 min in an atmosphere of humidified 5% CO₂, 95% The samples were evaluated by using computerized semen analyzer apparatus (CASA). After 90 days, the treated groups with palm pollen and pomegranate peel (groups B and C) demonstrated a significant increase in the sperm concentration, compared to group (A). Moreover, the recorded data revealed that the sperm concentration in group C was significantly higher than that in group B. The study indicated that the total sperm motility was increased significantly in groups B and C, as compared to that in the control group, while the total sperm motility in group C increased significantly, compared to group B. The histological evolutions signified that in the control group, the epithelial of seminiferous tubules were at different stages of spermatogenesis, the spermatocytogenesis (primary and secondary) with the spermatogenesis (spermatids) were found in a cluster at the cavity of the tubule. Furthermore, the results of histological evaluations in groups B and C were distinguished by a significant augmentation of the seminiferous tubules with primary and secondary spermatocytes, as well as some degrees of spermatogenesis (round spermatids), compared to group A. Moreover, increased angiogenesis was observed in groups B and C. In conclusion, the results pointed out that herbal remedies have a significant effects in the treatment of reproductive disorders.

Keywords: Herbal Medicine, Male Reproduction, Testicle

1. Introduction

The use of plants, plant extracts, and folk remedies for the treatment of human diseases has been known as traditional medicine. It has been approved that the main

components of traditional materia medica are herbs, which are the main forms of life on earth. It is estimated that there are about 350,000 species of existing plants (including seed plants, bryophytes, and

ferns), among which 287,655 species have been identified as of 2004 (1). Both the terms botanical medicine and phytomedicine are the synonyms of herbal medicine (HM) which are referred to the use of herbs, herbal materials, and extracts to cure human disease (1).

Different parts of medicinal plants, seeds, berries, roots, leaves, fruits, bark, and flowers are used as herbal remedies. While in some cases, the whole plant may be used as a therapy. Nearly about 5,000 years ago, the Sumerians described the use of plants, such as laurel, caraway, and thyme, as the proper treatment for some infectious diseases. Nonetheless, it is approved that the pioneers of herbal medicine lived in the Middle East. It dates far back to 60,000 years ago in Iraq.

Despite the long history of herbal medicine and its effective use, since the creation of conventional medicine over the past century, practitioners have been presented with serious challenges in this regard due to the lack of scientific evidence about the effectiveness of herbal remedies (1). One of the most important features of herbal plants is their antioxidant, anti-inflammatory, and anti-bacterial effects. Pomegranate and Palm pollen are two powerful herbs in terms of antioxidant, anti-inflammatory, and anti-bacterial properties.

Pomegranate peel is a highly nutritive by-product of pomegranate fruits. It has antibacterial, anti-oxidants, anti-cancer activity, anti-atherosclerotic, and wound healing properties (2-4). It is a great source of bioactive compounds, such as flavonoids, polyphenols, ellagitannins compounds (gallic acid, ellagic acid, punicalagin, punicalin, luteolin, quercetin, kaempferol, glycosides, and pedunculagin), minerals (calcium, phosphorus, nitrogen, potassium, magnesium, and sodium), and polysaccharide (5, 6). The pomegranate peel has the highest antioxidant activity, as compared to other parts of pomegranate fruit (7, 8). Moreover, pomegranate seeds, which are very important parts of pomegranate fruit, contain oil, lipid, and protein (9).

The pomegranate oil is an excellent source of unsaturated fatty acids. The physicochemical

compounds have a major role to play in the treatment of various disorders and diseases (10-13). Pomegranate seeds are a good source of juice and oil, containing 12%-20% oil of the total seed weight of the pomegranate. The extracted oil of pomegranate seed is an excellent source of fatty acid (polyunsaturated) and lipids, such as linoleic, oleic acid, linolenic, punicic acid, palmitic acid, and stearic acid (9, 14). It also contains pectin, crude fibers, minerals, vitamins, sugars, protein, sex steroids, polyphenols, and isoflavones (6, 15).

On the other hand, palm pollen contributes to the improvement of male fertility. It contains estrogenic substances and estrone, in addition to other nutrients, such as proteins, essential non-essential amino acids, sugars, vitamins, minerals, estrone, estradiol, beta-sitosterol, mino-esterol, cholesterol, as well as five types of flavonoids (16). The most important functions of palm pollen are antioxidant activities. Moreover, palm pollen improves the levels of testosterone and estrogen. It also stimulates the ovaries, containing estrogen which has multiple effects on ovulation (17, 18).

One of the most daunting changelings presented to humans and animals is infertility. Herbal remedies have been applied to cure this problem since the creation of human beings. In light of the aforementioned issues, the present study aimed to investigate the possible effects of pomegranate and palm pollen, as two powerful herbal remedies with antioxidant, anti-inflammatory, and anti-bacterial effects, on fertility in male rabbits.

2. Materials and Methods

2.1. Plant Materials and Study Design

Pomegranate peel and palm pollen were collected from Basrah. Plant powder was kept in a sterile black glass at 4°C. This study was conducted at Basra University-College of Veterinary Medicine, Theriogenology, Department of Surgery and Obstetrics. A total of 15 healthy New Zealand white male adult rabbits were randomly assigned to three groups (n=5 in

each group). The animals were housed under controlled environmental conditions ($20^{\circ}\text{C}\pm 2^{\circ}\text{C}$, 14:10h light: dark cycle) with ad libitum access to food and water (19). The period of study extended from 15/ 1/ 2021 to the end of 15/ 4/ 2021. The 1st group was served as the control group (n=5), the second group was treated with *P. pollen*, and the third group was treated with pomegranate peel for 90 days.

Group A: 5 rabbits did not receive herbal treatment (control group).

Group B: 5 rabbits were treated with palm pollen at a dose of 2 g by oral gavage daily.

Group C: 5 rabbits were treated with pomegranate peel (2 g) treated by oral gavage daily.

2.2. Testicle Recovery and Sperm Collection

After 90 days from the beginning of the experiment, all animals were euthanized after an overdose of ketamine hydrochloride (Vetanarcol 15 mg/kg intramuscular; König S.A., Avellaneda, Argentina) and xylazine hydrochloride (Kensol 1 mg/kg intramuscular; König S.A.). Following the euthanasia, the testis was removed, evaluated morphologically (Figure 1), and the testicles with normal appearance were selected for further processing. For sperm recovery, the epididymis was dissected from the testicles and the tail of the epididymis (Figure 2) was minced in the sperm washing medium and incubated for 15 min in an atmosphere of humidified 5% CO₂, 95% air (20). The samples were evaluated by using computerized semen analyzer apparatus (CASA) with 10× and 40 × magnification to evaluate sperm samples (21, 22).

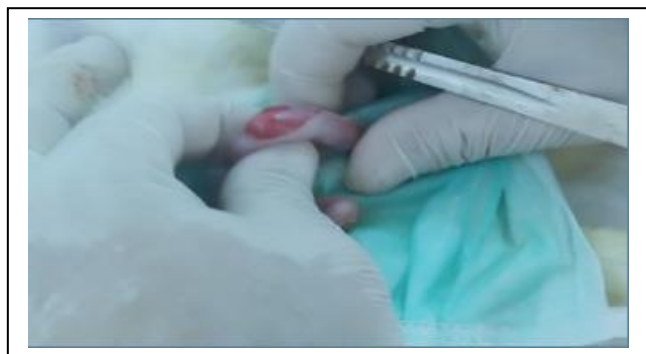

Figure 1. Open surgical of scrotum

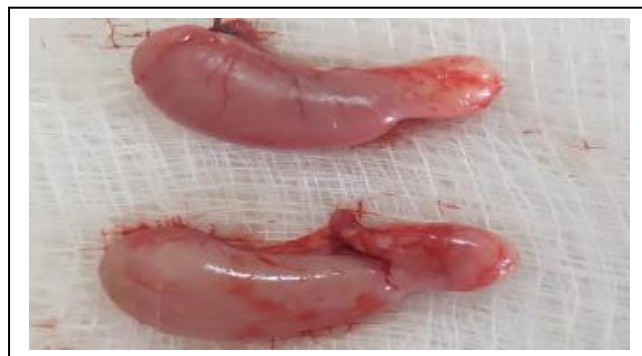

Figure 2. Complete castrated of testis

2.3. Histological Evaluations

The dissected testes were rapidly fixed in either 10% phosphate-buffered paraformaldehyde (pH; 7.4) or Bouin's solution. Testes were sectioned crossly or longitudinally, dehydrated in ascending grades of ethyl alcohol, cleared in methyl benzoate, and embedded in paraffin. Sections (5 μm-thicknesses) were cut, stained with hematoxylin and eosin (H& E) as a general stain, and examined with a light microscope.

2.4. Statistical Analysis

The data were analyzed in SPSS software (version 22) using one-way ANOVA. Differences were compared by Tukey's multiple comparison post hoc test. All data were presented as mean±SEM and the differences were considered statistically significant at $P<0.05$.

3. Results

The effects of palm pollen and pomegranate peel as a diet supplement on rabbits' physical parameters of semen and morphometric characteristics of the testis are as follows: The physical parameters of sperms evaluation were total sperm count, sperm motility, sperm immobility, progressive motility, non-progressive motility, abnormal sperm, and morphometric testis. After 90 days, the treated groups with palm pollen and pomegranate peel (groups B and C) exhibited a significant increase in the sperm concentration, compared to group (A). Moreover, the recorded data revealed that sperm concentration was

significantly higher in group C, compared to that in group B.

The study pointed out that the total sperm motility significantly increased in groups B and C, as compared to that in the control group, while total sperm motility in group C increased significantly, in comparison with that in group B. The recorded data revealed that total non-motile sperm decreased significantly in group C, as compared to that in group B. Furthermore, the recorded data also displayed that the sperm total progressive motility significantly increased in groups B and C, compared to that in group A. The results suggested that sperm progressive motility significantly increased in group C, compared to that in group B. The results of the current study demonstrated that the percentage of sperm with non-progressive motility decreased in group C, compared to that in group B. On the other hand, the results revealed that the proportion of abnormal sperms decreased significantly in groups B and C, compared to

that in group A. Nonetheless, total abnormal sperms decreased significantly in group C, compared to those in group B (Table 1).

The results of this study pointed to superiority in the improvement of morphometric testicular value in groups C and B, compared to that in control group, while the testicular morphometric increases significantly in group C, compared to group B, as presented in table 1.

The histological observations in group (A) illustrated that the testes and seminiferous tubules lined by stratified epithelial cells which were low in numbers and support the cells seated at the basement membrane of the tubule and extended into the cavity of the tubule. On the other hand, the interstitial thin tissue between the tubule interposed by blood vessels and Leydig cells, the outer connective tissue capsule, is surrounding the organs as displayed in figures 3 and 4.

Table 1. Effect of Palm pollen and Pomegranate peel on total physical parameters of sperm evaluation in rabbits

Groups	Time after treatment/ 90 days						
	Sperm count	Sperm motility	Sperm immobility	Progressive sperms motility	Non-progressive sperms motility	Abnormal sperm	Testicular morphometric
A	4.42±0.22 ^a	4.51±0.11 ^a	5.11±0.58 ^a	4.98±0.31 ^a	4.51±0.16 ^a	5.22±0.12 ^a	3.71±0.14 ^a
B	7.16±0.12 ^b	6.12±0.13 ^b	3.41±0.42 ^b	6.38±0.23 ^b	3.29±0.41 ^b	3.12±0.14 ^b	4.15±0.21 ^b
C	9.78±0.36 ^c	8.26±0.11 ^c	1.28±0.34 ^c	8.75±0.02 ^c	1.56±0.25 ^c	1.98±0.72 ^c	4.22±0.45 ^b

Data represent total sperm count X10⁹ sperm/ml as (mean ± SEM)

Different letters within each column indicate a significant difference ($P < 0.05$)

GA: Control group; GBPalm pollen supplemented (2 grams); GC, Pomegranate peel supplemented (2grams)

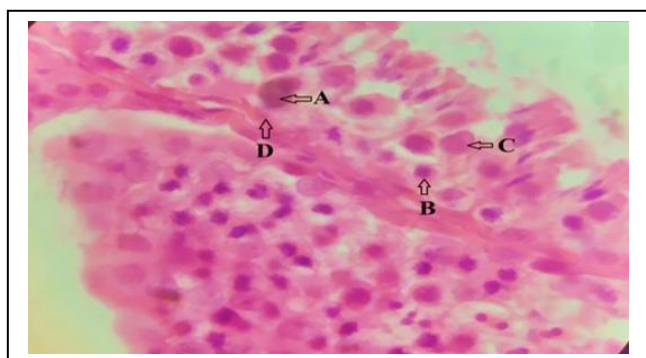


Figure 3. Normal seminiferous tubules of testis of group A, Sertoli cell (A), Primary spermatocyte (B), Secondary spermatocyte (C), Basement membrane (D) (H&E×1000)

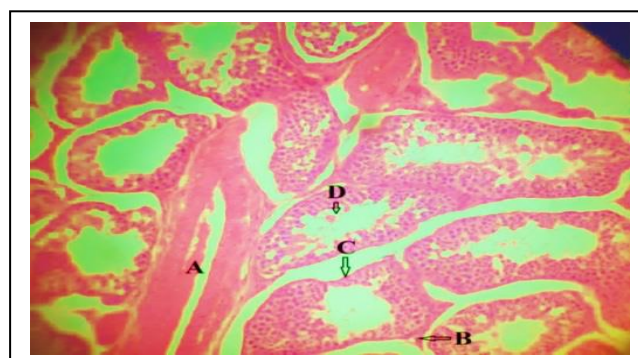


Figure 4. Cross-section of testis of group A: Blood vessels (A), Lydig cell (B), Seminiferous tubules (C), Spermatids (D) (H&E×200)

The histological evolutions indicated that in the control group, the epithelial of seminiferous tubules were at different stages of spermatogenesis, and the spermatocytogenesis (primary and secondary) with the spermatogenesis (spermatids) were found in a cluster at the cavity of the tubule (Figure 5). On the other hand, the results of histological evaluations in groups B and C were distinguished by a significant augmentation of the seminiferous tubules with primary and secondary

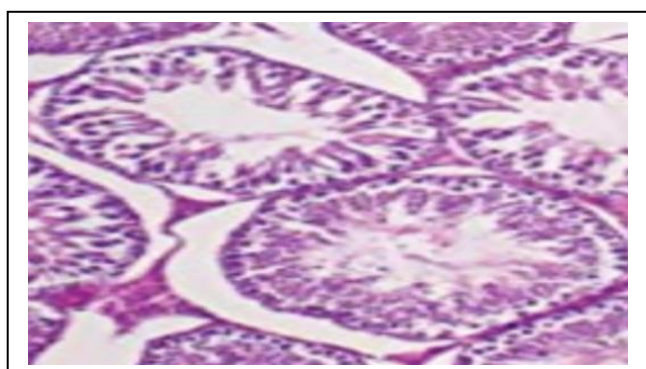


Figure 5. Seminiferous tubules of testis of group A: Primary spermatogonia (H&E×200)

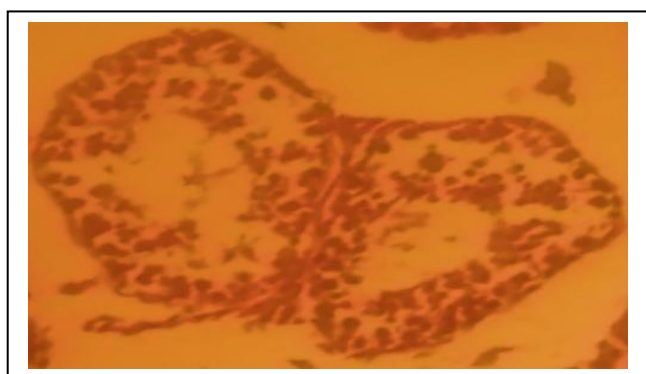


Figure 6. Palm pollen supplemented group: Primary spermatocytes (Secondary spermatocytes, Spermatids) H&E×200

4. Discussion

Modern studies have aimed to use medicinal herbs as food additives that help increase growth and treat many diseases. These herbs, such as palm pollen additives, that contribute to the improvement of male fertility contain estrogenic substances, estrone, and some other

spermatocytes, as well as some degrees of spermiogenesis (round spermatids), compared to the group A. Moreover, increased angiogenesis was observed in groups B and C (Figure 6).

The recorded data obtained in the current study demonstrated an increment of spermatozoa cells in the seminiferous tubules, with an increase in the number of interstitial cells in groups B and C, compared to that in group A (Figures 7 and 8).

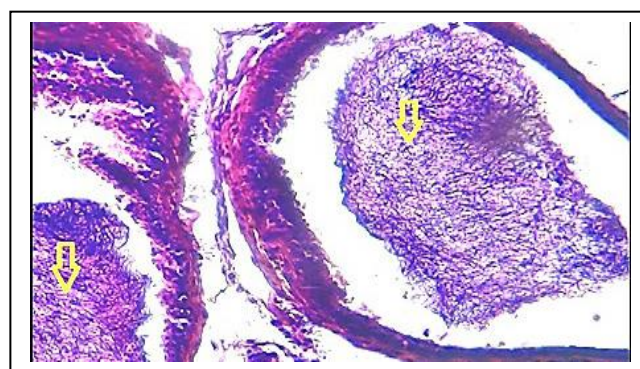


Figure 7. Testis of groups B and C: The seminiferous tubules filled with spermatids (H&E×400)

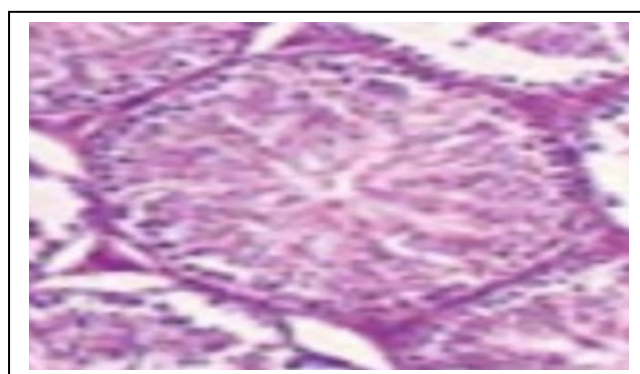


Figure 8. Testis of groups B and C: The seminiferous tubules fill with sperm (H&E×200)

nutrients, such as proteins, essential and nonessential amino acids, carbohydrates, vitamins, and minerals (16). Many researchers have indicated that using palm pollen as an additive in diets leads to the enhancement of weak sperm and sexual dysfunction in general. Moreover, it improves the level of testosterone and

estrogen hormones since this herb contains substances with similar compositions to steroid hormones.

Furthermore, palm pollen contains important nutrients, such as sugars, estrone, sterol, beta-sitosterol, mino-osterol, and cholesterol, as well as five types of flavonoids, which affect the process of increasing sexual libido in males. The researchers have noted that palm pollen combines two types of characteristics that are important for the functioning of the male reproductive system. Firstly, it provides protection and supports for testicular tissue and cells from harmful substances that may be accidentally produced during vital processes, including effective free radicals oxygen (ROS) (23). The researcher indicated that the second feature is the enhancement of the action of the sex hormones that are important for the performance of testicular functions (24).

Linjawi (25) pointed out that palm pollen had the ability to enhance the androgen receptor inside the seminiferous tubules, as well as the production of proteins and protect DNA in testicular tissue. Numerous researchers refer to Linjawi (25) who indicated that the addition of palm pollen to diets leads to an increase in the level of the testosterone hormone in serum since it may increase the numbers of testosterone receptors in the testis, which in turn increases reproductive efficiency, sperm concentration, the number of live sperms, and sperm motility.

Studies conducted on palm pollen have confirmed its role in increasing the Luteinizing Hormone (LH), which acts to increase the effectiveness of testicles through exerting an effect on Leydig Cells (24). Moreover, some other investigations have pointed to the role of palm pollen in increasing the diameter of the seminal tubule, the thickness of the germinal layer, and the diameter of the lumen of the seminiferous tubule for testicles (24). Increasing the levels of follicle-stimulating hormone (FSH) and testosterone when adding palm pollen increases the weight of the testicle and size of the testis since it increases the diameter of the seminal tubule (24). Furthermore, an increase in FSH levels may cause maturation and an increase in the

sperm generation process in the seminiferous tubules, thereby leading to an increase in the thickness of the germ layer (24). As evidenced by the results of this study, it can be concluded that herbal remedies have a significant effect on the treatment of reproductive disorders.

Authors' Contribution

Study concept and design: G. S. B.

Acquisition of data: G. S. B.

Analysis and interpretation of data: A. K. A. and A. S. A.

Drafting of the manuscript: M. T. A. and I. A. H.

Critical revision of the manuscript for important intellectual content: G. S. B.

Statistical analysis: G. S. B.

Administrative, technical, and material support: G. S. B.

Ethics

Approval for the research study was obtained from the Altoosi University College, Najaf, Iraq ethics board (project approval number 2020-4699-7954).

Conflict of Interest

The authors declare that they have no conflict of interest.

References

1. Pan S-Y, Litscher G, Gao S-H, Zhou S-F, Yu Z-L, Chen H-Q, et al. Historical perspective of traditional indigenous medical practices: the current renaissance and conservation of herbal resources. *Evid Based Complement Alternat Med.* 2014;2014:525340-.
2. Emamverdi M, Zhandi M, Shahneh AZ, Sharafi M, Akhlaghi A, Motlagh MK, et al. Flow cytometric and microscopic evaluation of post-thawed ram semen cryopreserved in chemically defined home-made or commercial extenders. *Anim Prod Sci.* 2015;55(4):551-8.
3. Navarro V, Villarreal ML, Rojas G, Lozoya X. Antimicrobial evaluation of some plants used in Mexican traditional medicine for the treatment of infectious diseases. *J Ethnopharmacol.* 1996;53(3):143-7.
4. Rajan S, Mahalakshmi S, Deepa V, Sathya K, Shajitha S, Thirunalasundari T. Antioxidant potentials of

- Punica granatum* fruit rind extracts. *Int J Pharm Pharm Sci.* 2011;3(3):82-8.
5. Li Y, Guo C, Yang J, Wei J, Xu J, Cheng S. Evaluation of antioxidant properties of pomegranate peel extract in comparison with pomegranate pulp extract. *Food Chem.* 2006;96(2):254-60.
 6. Mirdehghan SH, Rahemi M. Seasonal changes of mineral nutrients and phenolics in pomegranate (*Punica granatum* L.) fruit. *Sci Hort.* 2007;111(2):120-7.
 7. Kulkarni AP, Mahal HS, Kapoor S, Aradhya SM. In Vitro Studies on the Binding, Antioxidant, and Cytotoxic Actions of Punicalagin. *J Agric Food Chem.* 2007;55(4):1491-500.
 8. Zahin M, Aqil F, Ahmad I. Broad spectrum antimutagenic activity of antioxidant active fraction of *Punica granatum* L. peel extracts. *Mutat Res Genet Toxicol Environ Mutagen.* 2010;703(2):99-107.
 9. Fadavi A, Barzegar M, Hossein Azizi M. Determination of fatty acids and total lipid content in oilseed of 25 pomegranates varieties grown in Iran. *J Food Compost Anal.* 2006;19(6):676-80.
 10. Abbasi H, Rezaei K, Rashidi L. Extraction of Essential Oils From the Seeds of Pomegranate Using Organic Solvents and Supercritical CO₂. *J Am Oil Chem Soc.* 2008;85(1):83-9.
 11. Kýralan M, Gölükçü M, Tokgöz H. Oil and Conjugated Linolenic Acid Contents of Seeds from Important Pomegranate Cultivars (*Punica granatum* L.) Grown in Turkey. *J Am Oil Chem Soc.* 2009;86(10):985-90.
 12. Melgarejo P, Salazar DM, Amorós A, Artés F. Total lipids content and fatty acid composition of seed oils from six pomegranate cultivars. *J Sci Food Agric.* 1995;69(2):253-6.
 13. Newman RA, Lansky EP, Block ML. *Pomegranate: The most medicinal fruit: Basic Health Publications, Inc.;* 2007.
 14. Özgül-Yücel S. Determination of conjugated linolenic acid content of selected oil seeds grown in Turkey. *J Am Oil Chem Soc.* 2005;82(12):893-7.
 15. El-Nemr SE, Ismail IA, Ragab M. Chemical composition of juice and seeds of pomegranate fruit. *Food Nahrung.* 1990;34(7):601-6.
 16. Hassan HM. Chemical composition and nutritional value of palm pollen grains. *Global J Biotechnol Biochem.* 2011;6(1):1-7.
 17. Alibraheemi NAA, Bustani GS, Al-Dhalimy AMB. Effect of Curcumin on LH and FSH Hormones of Polycystic Syndrome Induced by Letrozole in Female Rats. 2021.
 18. Hamed MS, Arrak JK, Al-Khafaji NJ, Hassan AA. Effect of date palm pollen suspension on ovarian function and fertility in adult female rats exposed to lead acetate. *Diyala J Med.* 2012;3(1):90-6.
 19. Dadashpour Davachi N, Masoudi R, Bartlewski PM, Ahmadi B, Didarkhah M. Induction of Ovulation after Artificial Insemination in Rabbits: Intramuscular In-jection of Gonadotropin-Releasing Hormone (GnRH) Agonist vs. Intravenous Administration of Mated Doe Serum. *Iran J Vet Med.* 2022;16(1):26-35.
 20. Dadashpour Davachi N. Effect of different surgical methods in the mouse embryo transfer: Electrosurgery versus cold surgical technique effects on repeated use of surrogate mothers, pregnancy rate and post-surgical behavior. *Vet Res Forum.* 2021;12(4):467-71.
 21. Masoudi R, Sharafi M, Zareh Shahneh A, Towhidi A, Kohram H, Esmaeili V, et al. Fertility and flow cytometry study of frozen-thawed sperm in cryopreservation medium supplemented with soybean lecithin. *Cryobiology.* 2016;73(1):69-72.
 22. Dadashpour Davachi N, Norouzi E, Didarkhah M, Eslampanah M. In vitro Production of Grivet Monkey (*Chlorocebus aethiops*) Embryo. *Iran J Vet Med.* 2022.
 23. Liu Z-Q, Luo X-Y, Liu G-Z, Chen Y-P, Wang Z-C, Sun Y-X. In vitro study of the relationship between the structure of ginsenoside and its antioxidative or prooxidative activity in free radical induced hemolysis of human erythrocytes. *J Agric Food Chem.* 2003;51(9):2555-8.
 24. Hong B, Ji YH, Hong JH, Nam KY, Ahn TY. A double-blind crossover study evaluating the efficacy of Korean red ginseng in patients with erectile dysfunction: a preliminary report. *J Urol.* 2002;168(5):2070-3.
 25. Linjawi SA. Evaluation of the protective effect of panax ginseng nanoparticles against nicotine-induced reproductive disorders in male rats *Int. J Pharm Sci Rev Res.* 2015;32(1):38-45.