

Original Article

## Gastroprotective Effect of *Capparis spinosa* on Indomethacin-induced Gastric Ulcer in Rats

Al-Zubaidy, A. A<sup>1</sup>\*, Khalil, A. M<sup>1</sup>

1. Department of Pharmacology, College of Medicine, Al-Nahrain University, Baghdad, Iraq

Received 17 January 2022; Accepted 1 April 2022  
Corresponding Author: jawadabed78@yahoo.com

### Abstract

Peptic ulcer is an acid-induced lesion that is usually found in the stomach and duodenum. It is usually a case of imbalance between the acid (and other injurious factors) and the mucosal defense mechanisms. Indomethacin is one of the most ulcerogenic drugs that is prescribed over-the-counter for the management of musculoskeletal problems. *Capparis spinosa* is one of the most important species in the Capparidaceae family, which has a wide range of diversity. Caper (*Capparis spinosa* L.) is a common member of the genus *Capparis* (Capparidaceae family). The present study was designed to compare the effect of *C. spinosa* extract as a gastroprotective agent with indomethacin as an induction agent and ranitidine as a standard drug. To this aim, 40 adult male Wistar rats were randomly divided into 4 groups (n=10 each), including Control +: indomethacin-treated group, Control -: receiving physiological saline solution, C.S: *C. spinosa*-treated group; and ranitidine-treated group (50 mg/kg) as a standard agent for the treatment of the gastric ulcer. After the experimental period, all the animals were sacrificed by anesthesia overdose and their stomachs were removed. The gastroprotective effect of *C. spinosa* was investigated by studying prostaglandin E2 (PGE2), Gastrin, anti-tumor necrosis factor alpha (TNF- $\alpha$ ), and Interleukin 1 beta (IL1- $\beta$ ), along with histopathological examination. The results showed a significant increase in PGE2 levels in the ranitidine-treated group with a significant reduction in Gastrin, TNF- $\alpha$ , and IL1- $\beta$ . The recorded data obtained from the histopathological study showed a significant improvement in the treated group with the extract of *C. spinosa*. The study concluded that *C. spinosa* had gastroprotective properties possibly through enhancing PGE2 which was acting as anti-inflammatory inhibiting neutrophil infiltration.

**Keywords:** Anti-inflammatory, *Capparis spinosa*, Gastroprotective, Indomethacin

### 1. Introduction

Peptic ulcers are acid-induced lesions that are found in the stomach and duodenum characterized by denuded mucosa with the injuries extending into the submucosa or muscularis propria. Lesions that fail to reach this muscularis propria are called erosions (1). Traditionally, a hypersecretory acidic environment, along with dietary factors and/or stress, was thought to cause most peptic ulcer diseases; however, the discovery of *Helicobacter pylori* infection and the over-the-counter use of nonsteroidal anti-inflammatory

drugs (NSAIDs) in the second half of the 20<sup>th</sup> century had changed this perception (2).

The risk of complications of peptic ulcer is multiplied four times in NSAID users and two times in low-dose aspirin users. The concomitant use of NSAIDs or aspirin with anticoagulants, corticosteroids, and selective serotonin reuptake inhibitors (SSRIs) increases the risk of upper gastrointestinal bleeding. However, many people who use NSAIDs or aspirin also have concurrent *H. pylori* infection; the interaction of these drugs in the pathogenesis of peptic ulcer

disease remains controversial (3).

Nonsteroidal anti-inflammatory drugs (including low-dose aspirin) are among the most commonly used drugs. They have good efficacy and a long history of clinical use; nevertheless, they can cause peptic ulcers, which may have fatal consequences. Given the widespread use of NSAIDs and aspirin, the associated gastrointestinal toxic effect has substantial implications for the healthcare system (4).

The main mechanism of NSAID-associated toxicity of the gastroduodenal mucosa is the systemic inhibition of cyclooxygenase-1 (COX-1), which is constitutively expressed to be responsible for prostaglandin synthesis in normal physiology and is associated with decreased mucosal blood flow, low mucus and bicarbonate secretion, cell proliferation inhibition. Nonsteroidal anti-inflammatory drugs inhibit the enzyme reversibly in a concentration-dependent manner (1<sup>st</sup> order kinetic). The co-administration of exogenous prostaglandins and COX-2-selective NSAIDs minimizes mucosal damage and the risk of ulcers. Nevertheless, the different physicochemical properties of NSAIDs cause different toxicity patterns (5). The COX hypothesis is supported by studies showing that the co-administration of prostaglandins (exogenous) reduces mucosal damage (2).

*Capparis spinosa* is one of the most important species in the Capparidaceae family that has a wide range of diversity. Caper (*Capparis spinosa* L.) is a common member of the genus *Capparis* (Capparidaceae family). This genus consists of more than 250 flowering species located throughout different habitats from subtropical to tropical zones (6). To the best of our knowledge, so far, the chemistry of the genus *Capparis* has not been extensively studied and only a few species have been evaluated. Studies have been conducted to identify contents from different parts of the plant, including lipids, glucosinolates, and flavonoids. Capers species are also known in folk medicine for their diuretic, astringent, tonic, and antirheumatic uses; it has been shown that extracts from caper plants have hepatoprotective and antioxidant activity, and more

recently a protein with antiproliferative, antifungal, and HIV-1 reverse transcriptase inhibitory effects has been identified from the *C. spinosa* seeds (7).

It has been reported that the crude extracts of *C. spinosa* have been used for the treatment of gastrointestinal problems, headaches, liver disease, and toothache. Moreover, *C. spinosa* has been suggested by Arabian traditional medicine for the management of different human diseases, such as spleen diseases, stomach problems, skin diseases, earache, kidney diseases, and hepatic diseases. *Capparis spinosa* are also known in folk medicine for their diuretic, astringent, tonic, and antirheumatic properties (8).

## 2. Materials and Methods

This study was conducted on adult male Wistar rats (n=40) with a weight range of 180-220 g in the Biological Research Center of the University of Al-Nahrain, Baghdad, Iraq, from March to September 2020. The samples were randomly divided into 4 groups (n=10 each). The serological and histopathological testing were conducted in the College of Medicine of Al Nahrain University. All experiment procedures were performed in compliance with the Institutional Review Board.

Volumes of 50 g of *C. spinosa* were dried, finely powdered, and then separately put in a soxhlet apparatus with adding ethanol as a solvent (absolute ethanol) by continuous flow method that was demonstrated to be more efficient than the standard method (9). The procedure took a few hours, the extract was left to evaporate the ethanol content, and the final crude extract was collected.

All animals were deprived of food for 24 h before the experiment; however, they were free to access water. Gastric ulcer was induced by a single dose of indomethacin (50 mg/kg) by oral gavage on empty stomach according to the method proposed by Shahin, Abdelkader (10). Gastric ulcer was confirmed grossly after 24 h before proceeding with the experiment. The treatment started on the next day and continued for 7 days. After the experimental period, all the animals

were sacrificed by anesthesia overdose and their stomachs were removed. Ranitidine (50 mg/kg) was used as a standard agent for the treatment of gastric ulcers (11). The animals were grouped as follows: 1) Positive control: receiving indomethacin, 2) Negative control: receiving physiological saline solution, 3) C.S: undergoing treatment with *C. spinosa*, and 4) receiving ranitidine.

### 2.1. Prostaglandin E<sub>2</sub>, Tumor Necrosis Factor Alpha, Gastrin

Gastric tissue samples were kept in cool phosphate buffer saline and homogenized and centrifuged by cool ultra-centrifugate; finally, the supernatant was collected and used in the enzyme-linked immunosorbent assay kit.

After preparing the required number of strips and wells, the standard and samples were added to the wells. Afterward, the anti-prostaglandin E<sub>2</sub> (PGE<sub>2</sub>), anti-tumor necrosis factor alpha (TNF- $\alpha$ ), and anti-gastrin were individually added to the sample wells, covered, and incubated, and then washed 5 times. Subsequently, the substrates A and B were added to each well, covered, and incubated, and finally stop solution was added and the density was determined at 450 nm.

### 2.2. Interleukin 1 Beta

The immune-histochemistry technique was employed to determine interleukin 1 beta (IL1- $\beta$ ) expression in the sample. After serial sectioning for the paraffin blocks, paraffin slides were deparaffinized and rehydrated; subsequently, hydrogen peroxide was added and the slides were washed in tris-buffered saline (TBS). After incubation, the slides were washed one more time by TBS and the primary antibody was added to the slides and incubated, and then, after washing, the secondary antibody was added and washed after incubation. Horseradish peroxidase was applied to the tissue, and the slides were incubated and washed by buffer and then treated with diluted liquid 3,3'-Diaminobenzidine chromogen. The slides were washed, counterstaining was performed by Mayer's Haematoxylin, and tissues were mounted, placed on a coverslip, and examined.

### 2.3. Histopathological Examination

Tissues of all groups were harvested at the end of the experiment (day 8). The histopathological changes of each stomach tissue were evaluated and scored as follows:

- score 0: normal mucosa;
- score 1: erosion of epithelial cells;
- score 2: erosion of epithelial cells and lamina propria;
- score 3: erosion to muscularis mucosa; and
- score 4: erosion to the submucosa.

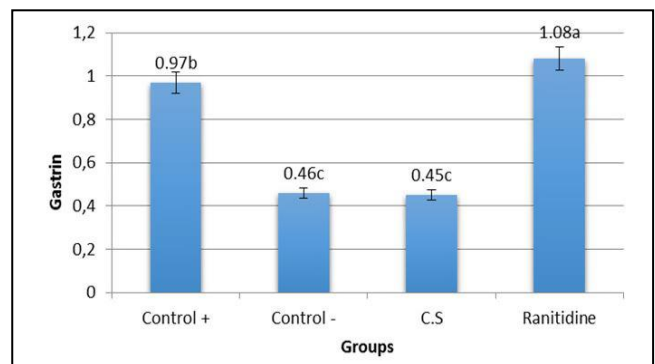
### 2.4. Statistical Analysis

Statistical analysis of data was performed using SAS software (version 9.1). All data were subjected to the Shapiro-Wilk test, the results of which confirmed the normal distribution of the data. One-way ANOVA and the least significant difference post hoc test were performed to assess significant differences among means.

## 3. Results

### 3.1. Tissue Gastrin Concentration

Figure 1 depicts tissue gastrin concentration in the control + (indomethacin-treated group), control - (receiving a physiological saline solution), C.S group (*C. spinosa*-treated group), and ranitidine-treated groups.



**Figure 1.** Gastrin levels in gastric mucosa in all groups

According to figure 1, gastrin concentration in the indomethacin-treated group (positive control) was significantly elevated ( $P < 0.05$ ), compared to the sham group. Moreover, in the *C. spinosa* group, gastrin levels significantly reduced; however, the ranitidine-treated group showed a nonsignificant difference only from the indomethacin group.

### 3.2. Tissue PGE2 Level

Figure 2 shows the PGE2 level in gastric mucosa in the control + (indomethacin-treated group), control – (receiving a physiological saline solution), C.S group (*C. spinosa*-treated group), and ranitidine-treated groups.

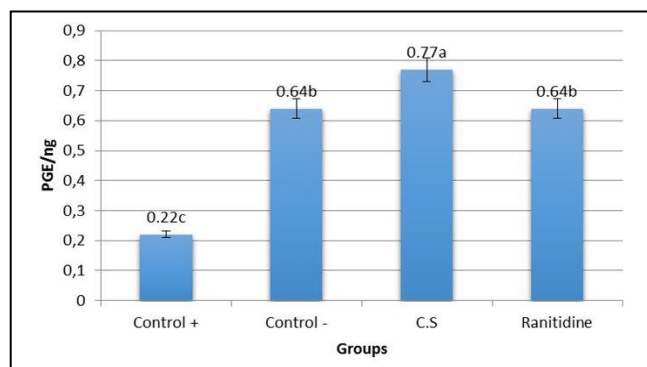


Figure 2. PGE2 level in gastric mucosa in all groups

Based on figure 2, indomethacin caused a significant reduction in the PGE2 level, compared to the sham group, in opposite to ranitidine, which led to a significant elevation ( $P<0.05$ ), in comparison to indomethacin. It was also revealed that *C. spinosa* significantly raised the PGE2 level.

### 3.3. Tissue TNF- $\alpha$ Level

Figure 3 displays tumor necrosis factor- $\alpha$  level in gastric mucosa in the control + (indomethacin-treated group), control – (receiving a physiological saline solution), C.S group (*C. spinosa*-treated group), and ranitidine-treated groups.

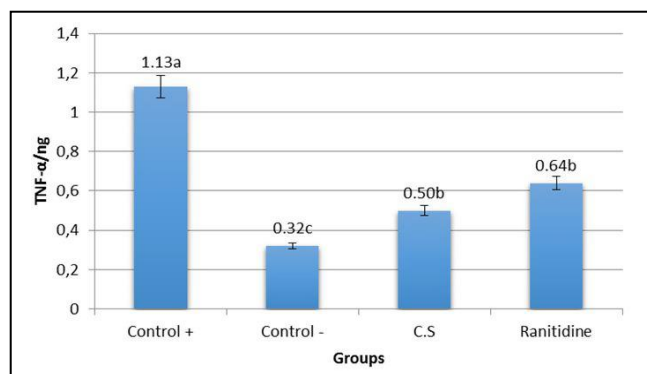


Figure 3. TNF- $\alpha$  level in gastric mucosa in all groups

Based on figure 3, indomethacin caused a significant elevation in TNF- $\alpha$  level ( $P<0.05$ ), while ranitidine significantly reduced TNF- $\alpha$  level. Additionally, the ranitidine result was insignificantly different from *C. spinosa* in reducing TNF- $\alpha$  levels in the rat gastric mucosa.

### 3.4. Immunohistochemistry Study of Gastric IL1-B

Figure 4 illustrates IL1-B scoring results in the control + (indomethacin-treated group), control – (receiving a physiological saline solution), C.S group (*C. spinosa*-treated group), and ranitidine-treated groups.

According to figure 4 and 5, IL1- $\beta$  was a pro-inflammatory marker that was expressed in nearby cells of the ulcer area in the indomethacin group to induce inflammation and tissue healing. Indomethacin caused a significant increase in IL1- $\beta$  expression in gastric tissue, whereas ranitidine significantly decreased IL1- $\beta$  levels. It was also found that *C. spinosa* caused a significant reduction in IL1- $\beta$  expression, and the *C. spinosa* result was insignificantly different from that in the sham group. Scoring was performed and the scoring system recorded the average intensity of the expression (12). Accordingly, the scoring was as follows:

- score 0: absence of immunoreactivity;
- score 1: weak immunoreactivity;
- score 2: moderate immunoreactivity;
- score 3: strong immunoreactivity.

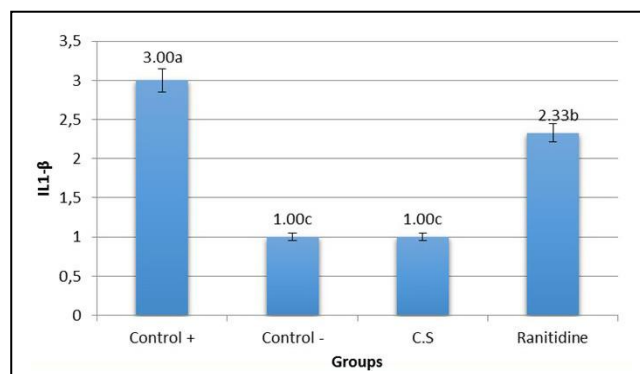


Figure 4. Interleukin 1 beta scoring results in all groups

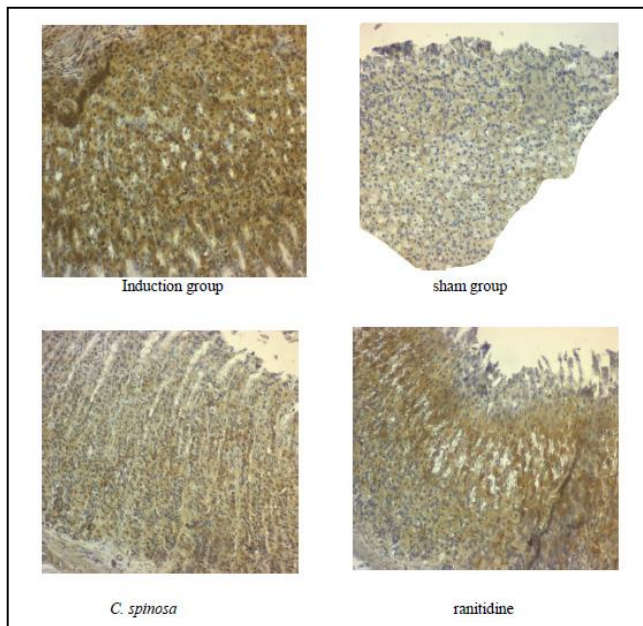


Figure 5. IL1- $\beta$  expression in the study groups

### 3.5. Histopathology examination

The induction group showed a significant ulcer scoring consisting of ulcers extending through epithelial cells to the submucosa. It was also revealed that *C. spinosa* and ranitidine groups scored significantly lower than the induction group of erosions to the epithelial cells (Figure 6 and 7).

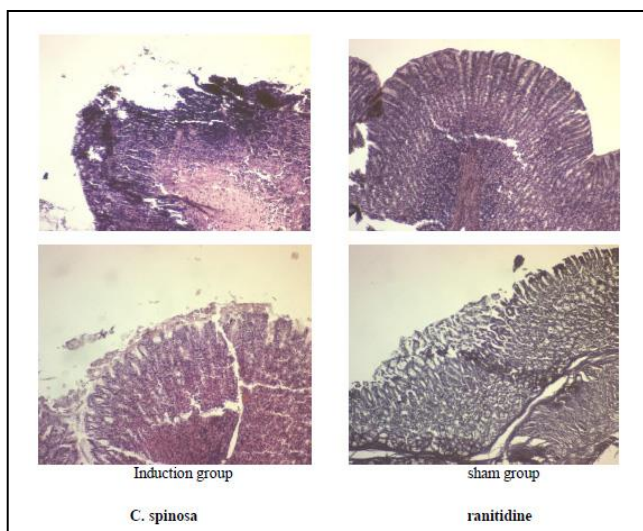


Figure 6. Hematoxylin and eosin staining of gastric tissue of the study groups

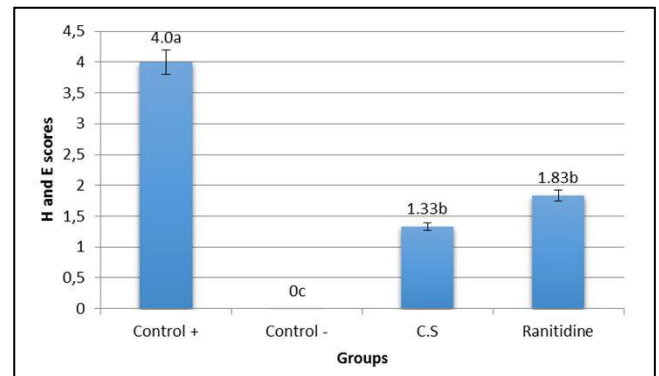


Figure 7. Histopathological scoring results in all groups

### 4. Discussion

Current conventional medications are effective in ulcer healing. However, their side effects are sometimes inevitable and limit their clinical usefulness (13). This issue highlights the role of medicinal herbs that have the support of both experimental and clinical studies exhibiting the effectiveness of herbal therapy in gastric ulcers with few side effects (14). Herbal medicines have been used for treating gastric and duodenal ulcers for decades. The results of numerous controlled clinical studies have shown the efficacy of herbs in treating gastric ulcers. The findings of a study by He, Zhang (15) showed that more than 86% of the patients with gastric ulcers improved after oral administration of an herbal therapy mixture.

Gastric ulcer induced by indomethacin was evidenced in the current study by the histopathological scoring and the gastric tissue obtained from the indomethacin group (induction group), which confirmed the mucosal injury, loss of epithelial layers, decreased mucosal thickness with the distortion of mucosa and its glands, and inflammatory cells infiltration. Ulcer induction model by indomethacin was performed on empty stomach by withholding food from animals 12 h before the induction since it has been shown that this timing of administration increases the incidence of gastric mucosal lesions because food has buffering capacity against the effect of indomethacin (16).

Gastrin is a linear peptide hormone that is secreted



from gastrin cells and regulates the function of acute gastric acid secretion and epithelial cell population. It has been reported that gastrin can stimulate acid secretion (17). The results of the current study showed a significant increase in gastrin level in the indomethacin group, compared to the negative group, while *C. spinosa*-treated gastrin level was non-significantly different from the negative control group. The ranitidine-treated group showed a significant increase in gastrin level, compared to the negative group.

The relationship between gastrin and the ulcer size and number is found to be weak (18), and the reason for the use of this parameter is for a better understanding of the molecular mechanism of gastro-protection of *C. spinosa*.

In this study, the gastrin level in the *C. spinosa*-treated group was non-significantly different from that in the negative control group. Nevertheless, the ranitidine-treated group showed a significant increase in gastrin levels, compared to the negative group. Ranitidine causes an elevation in gastrin level as a result of acid suppressant feedback of histamine 2 receptor blocking that produces this effect and the increment is even more prominent when proton pump inhibitors are used (19). Inhibition of acid secretion is important in ulcer healing. Various herbs with anti-ulcer effects reduce gastric acid secretion (20); this action may be attributed to either the blockage of  $H^+/K^+$  ATPase or stimulation of PGE2 (21, 22).

The results of the current study showed a significant reduction in PGE2 level in only the indomethacin (induction) group, compared to the normal group. One of the main causes of the gastric adverse effect of NSAIDs (especially indomethacin) is their ability to inhibit the COX enzyme (non-selectively). The findings of numerous studies have indicated that indomethacin causes gastric ulcers by inhibiting COX-1, in addition to the fact that the administration of exogenous PGE2 analogs (misoprostol) prevents ulcers due to the use of indomethacin.

Cyclooxygenase 1-derived PGE2 regulates intra-gastric pH, while COX-2 has a role in mucosal defense by increasing the proliferation of epithelial cells and reconstruction of glands during the repair cycle; in this regard, both enzymes are important in the gastric mucosal protection (23). However, some data are suggesting the indirect relationship between indomethacin (NSAIDs)-induced gastric damage degree and COX enzyme and/or PGE2 level (lansoprazole is an anti-ulcer with no effect on PGE2 level) (24).

Ranitidine treatment significantly increased the PGE2 level, compared to the indomethacin group, which was in agreement with the results of a study conducted by El-Saka, Abo Zeid (25). The findings of the mentioned study demonstrated that treatment with ranitidine significantly increased mucin and PGE2 levels and reduced ulcer size. They also concluded that the combination of ranitidine with citrulline afford better gastroprotection than either alone.

Borrelli and Izzo (26) explained the elevation of PGE2 levels in gastric tissue after using medicinal plants as an effect of the flavonoids present in the extract protecting gastric mucosal cells from damage by increasing the mucosal prostaglandin content and preventing histamine release from mast cells through inhibition of histidine decarboxylase.

Tumor necrosis factor alpha is the main mediator of the acute inflammatory response which is generated through the disease course, including infection and inflammation (27). The induction group (indomethacin only) showed a significant increase in TNF- $\alpha$  ( $P < 0.05$ ), compared to the sham group (negative control), as it was expected that indomethacin cause elevated levels of TNF- $\alpha$ , which is known to play roles in gastric injury and necrosis (23).

Based on the results of a study conducted by Inas, Hala (28) in 2011, indomethacin caused up-regulation of TNF- $\alpha$  biosynthesis; they attributed this effect to the fact that indomethacin inhibition of PGE2, which is responsible for TNF rise, and the inhibition of TNF- $\alpha$

would ultimately inhibit tissue destruction. However, TNF- $\alpha$  activates the proliferation of fibroblasts and endothelial cells and modulates angiogenesis, collagen synthesis, and collagenase synthesis; regarding this, TNF- $\alpha$  may affect wound healing. Nevertheless, some of these results are debatable, and discrepancy exists between *in vitro* and *in vivo* studies. Therefore, the question is whether TNF- $\alpha$  is required for ulcer healing or not (29).

The ranitidine-treated group (standard group) showed a significant reduction in TNF- $\alpha$  than the positive control group ( $P < 0.05$ ), which was consistent with the results of a study by Aziz, Siddiqua (30) showing the protective effect of ranitidine on gastric ulcer and its reductive effect on TNF- $\alpha$ , compared to the indomethacin-treated group. It was also revealed that *C. spinosa* caused a significant decrease in TNF- $\alpha$ , compared to the indomethacin-treated group ( $P < 0.05$ ). This effect might have been caused by the anti-inflammatory effect of *C. spinosa*, which was well documented in studies by Gursoy and Moutia (31, 32).

Baradaran Rahimi, Rajabian (33) found that treatment with the hydro-alcoholic extract of *C. spinosa* caused a significant decrement in TNF- $\alpha$  levels than in the other groups. They also reported the effect of the mentioned extract on inflammatory and cognitive impairment. The findings of a study performed by the Department of Surgical Sciences in Italy (2008) showed that *C. spinosa* extract caused the upregulation of TNF- $\alpha$  along with its receptor. However, their study was involved in the role of TNF- $\alpha$  in the viral infection and the immune-stimulatory effect of the extract (34).

Based on the results of the current study, the indomethacin-treated group showed a significant elevation in IL1- $\beta$  expression (in both cytoplasmic and cellular), compared to the sham group. This finding was in line with the results of previous studies indicating the association between NSAIDs and local inflammatory mediators and its relation to cellular signaling pathways. They also confirmed a significant

increase in IL1- $\beta$  after indomethacin use and its relation to the pathogenesis of gastric tissue (35).

The ranitidine-treated group showed a significant reduction in IL1- $\beta$  expression due to the ulcer healing effect of ranitidine. Ugan and Un conducted a study in 2020, the results of which showed that IL1- $\beta$  was significantly lower in the ranitidine group in different doses than in the indomethacin group, and they found that the ulcers disappeared in the treated groups in a dose-dependent manner (36). Panico, Cardile (37) explained the effect of *C. spinosa* on IL1- $\beta$  when used as a chondroprotective agent; accordingly, the extract of *C. spinosa* decreased IL1- $\beta$  levels (which induce nitric oxide and reactive oxygen species) in a dose-dependent fashion. Moreover, they attributed this function to the scavenging effect of polyphenolic active constituents, flavonoids (Quercetin), kaempferol glycosides, and hydroxycinnamic acids.

The findings of the present study showed that *C. spinosa* extract had a gastroprotective effect in indomethacin-induced gastric ulcers in rats, and this action was probably due to more than a single mechanism, including (1) antisecretory effect through the reduction of acid secretion, (2) enhancement of mucosal defense through the increase of PGE2, (3) anti-inflammatory effect that would decrease neutrophil infiltration to the ulcer area through antagonizing TNF- $\alpha$  and IL1- $\beta$ .

#### Authors' Contribution

Study concept and design: A. A. A.

Acquisition of data: A. A. A.

Analysis and interpretation of data: A. M. K.

Drafting of the manuscript: A. M. K.

Critical revision of the manuscript for important intellectual content: A. A. A.

Statistical analysis: A. A. A.

Administrative, technical, and material support: A. M. K.

## Ethics

The study protocol were approved by the ethics committee of the Al-Nahrain University, Baghdad, Iraq.

## Conflict of Interest

The authors declare that they have no conflict of interest.

## References

- Narayanan M, Reddy KM, Marsicano E. Peptic Ulcer Disease and Helicobacter pylori infection. *Mo Med*. 2018;115(3):219-24.
- Lanas A, Chan FKL. Peptic ulcer disease. *Lancet*. 2017;390(10094):613-24.
- Kuna L, Jakab J, Smolic R, Raguz-Lucic N, Vcev A, Smolic M. Peptic Ulcer Disease: A Brief Review of Conventional Therapy and Herbal Treatment Options. *J Clin Med*. 2019;8(2).
- Melcarne L, Garcia-Iglesias P, Calvet X. Management of NSAID-associated peptic ulcer disease. *Expert Rev Gastroenterol Hepatol*. 2016;10(6):723-33.
- Coxib, traditional NTC, Bhala N, Emberson J, Merhi A, Abramson S, et al. Vascular and upper gastrointestinal effects of non-steroidal anti-inflammatory drugs: meta-analyses of individual participant data from randomised trials. *Lancet*. 2013;382(9894):769-79.
- Zhang H, Ma ZF. Phytochemical and Pharmacological Properties of Capparis spinosa as a Medicinal Plant. *Nutrients*. 2018;10(2).
- Argentieri M, Macchia F, Papadia P, Fanizzi FP, Avato P. Bioactive compounds from Capparis spinosa subsp. rupestris. *Ind Crops Prod*. 2012;36(1):65-9.
- Nabavi SF, Maggi F, Daglia M, Habtemariam S, Rastrelli L, Nabavi SM. Pharmacological Effects of Capparis spinosa L. *Phytother Res*. 2016;30(11):1733-44.
- Ramluckan K, Moodley KG, Bux F. An evaluation of the efficacy of using selected solvents for the extraction of lipids from algal biomass by the soxhlet extraction method. *Fuel*. 2014;116:103-8.
- Shahin NN, Abdelkader NF, Safar MM. A Novel Role of Irbesartan in Gastroprotection against Indomethacin-Induced Gastric Injury in Rats: Targeting DDAH/ADMA and EGFR/ERK Signaling. *Sci Rep*. 2018;8(1):4280.
- Odabasoglu F, Cakir A, Suleyman H, Aslan A, Bayir Y, Halici M, et al. Gastroprotective and antioxidant effects of usnic acid on indomethacin-induced gastric ulcer in rats. *J Ethnopharmacol*. 2006;103(1):59-65.
- Prignano F, Ricceri F, Pescitelli L, Lotti T. Itch in psoriasis: epidemiology, clinical aspects and treatment options. *Clin Cosmet Investig Dermatology*. 2009;2:9.
- Bujanda L. The effects of alcohol consumption upon the gastrointestinal tract. *Am J Gastroenterol*. 2000;95(12):3374-82.
- Bi WP, Man HB, Man MQ. Efficacy and safety of herbal medicines in treating gastric ulcer: a review. *World J Gastroenterol*. 2014;20(45):17020-8.
- He LZ, Zhang Q, Wang SC. [Clinical study on treatment of gastric ulcer with qingwei zhitong pill]. *Chin J Integr Med*. 2001;21(6):422-3.
- Jawad FHA. studies on the origion of tissue histamine in G.P: glasgow; 1976.
- Zhang SL, Li H, He X, Zhang RQ, Sun YH, Zhang CF, et al. Alkaloids from Mahonia bealei posses anti-H(+)/K(+)-ATPase and anti-gastrin effects on pyloric ligation-induced gastric ulcer in rats. *Phytomedicine*. 2014;21(11):1356-63.
- Efendi D, Effendi R, Dairy LB, Sembiring J, Marpaung B, Sihombing M, et al. Level of gastrin serum and ulcer size on gastric ulcer correlated to helicobacter pylori infection. *Indones J Gastroenterol Hepatol Dig. Endosc*. 2009;10(3):113-6.
- Heilmann RM, Berghoff N, Grutzner N, Parnell NK, Suchodolski JS, Steiner JM. Effect of gastric acid-suppressive therapy and biological variation of serum gastrin concentrations in dogs with chronic enteropathies. *BMC Vet Res*. 2017;13(1):321.
- Dharmani P, Kuchibhotla VK, Maurya R, Srivastava S, Sharma S, Palit G. Evaluation of anti-ulcerogenic and ulcer-healing properties of Ocimum sanctum Linn. *J Ethnopharmacol*. 2004;93(2-3):197-206.
- Gao Y, Tang W, Gao H, Chan E, Lan J, Zhou S. Ganoderma lucidum polysaccharide fractions accelerate healing of acetic acid-induced ulcers in rats. *J Med Food*. 2004;7(4):417-21.
- Jainu M, Devi CS. Antiulcerogenic and ulcer healing effects of Solanum nigrum (L.) on experimental ulcer models: possible mechanism for the inhibition of acid formation. *J Ethnopharmacol*. 2006;104(1-2):156-63.
- El-Ashmawy NE, Khedr EG, El-Bahrawy HA, Selim HM. Nebivolol prevents indomethacin-induced gastric ulcer in rats. *J Immunotoxicol*. 2016;13(4):580-9.
- Brzozowski T, Konturek PC, Konturek SJ, Brzozowska I, Pawlik T. Role of prostaglandins in



- gastroprotection and gastric adaptation. *J Physiol Pharmacol.* 2005;56(5):33-55.
25. El-Saka M, Abo Zeid A, Abou Fard G. Effect Of L-Citrulline And Ranitidine On Indomethacin-Induced Gastric Ulcer In Male Albino Wister Rats. *Bull Egypt Soc Physiol Sci.* 2014;34(2):277-92.
26. Borrelli F, Izzo AA. The plant kingdom as a source of anti-ulcer remedies. *Phytother Res.* 2000;14(8):581-91.
27. Takeuchi T, Miura S, Wang L, Uehara K, Mizumori M, Kishikawa H, et al. Nuclear factor-kappaB and TNF-alpha mediate gastric ulceration induced by phorbol myristate acetate. *Dig Dis Sci.* 2002;47(9):2070-8.
28. Inas Z, Hala A, Gehan HH. Gastroprotective effect of *Cordia myxa* L. fruit extract against indomethacin-induced gastric ulceration in rats. *Life Sci J.* 2011;8(3):433-45.
29. Buck M, Houglum K, Chojkier M. Tumor necrosis factor-alpha inhibits collagen alpha1(I) gene expression and wound healing in a murine model of cachexia. *Am J Pathol.* 1996;149(1):195-204.
30. Aziz RS, Siddiqua A, Shahzad M, Shabbir A, Naseem N. Oxyresveratrol ameliorates ethanol-induced gastric ulcer via downregulation of IL-6, TNF-alpha, NF-kB, and COX-2 levels, and upregulation of TFF-2 levels. *Biomed Pharmacother.* 2019;110:554-60.
31. Gursoy N, Tepe B, Akpulat HA. Chemical composition and antioxidant activity of the essential oils of *Salvia palaestina* (Benth) and *S. ceratophylla* (L.). *Rec Nat Prod.* 2012;6(3):278.
32. Moutia M, El Azhary K, Elouaddari A, Al Jahid A, Jamal Eddine J, Seghrouchni F, et al. *Capparis Spinosa* L. promotes anti-inflammatory response in vitro through the control of cytokine gene expression in human peripheral blood mononuclear cells. *BMC Immunol.* 2016;17(1):26.
33. Baradaran Rahimi V, Rajabian A, Rajabi H, Mohammadi Vosough E, Mirkarimi HR, Hasanpour M, et al. The effects of hydro-ethanolic extract of *Capparis spinosa* (C. spinosa) on lipopolysaccharide (LPS)-induced inflammation and cognitive impairment: Evidence from in vivo and in vitro studies. *J Ethnopharmacol.* 2020;256:112706.
34. Arena A, Bisignano G, Pavone B, Tomaino A, Bonina FP, Saija A, et al. Antiviral and immunomodulatory effect of a lyophilized extract of *Capparis spinosa* L. buds. *Phytother Res.* 2008;22(3):313-7.
35. Gelen V, Sengül E, Gedikli S, Gelen S, Atila G, Makav M, et al. The Protective Effects of Probiotic Bacteria on Indomethacin-Induced Gastric Ulcer in Rats. *Research Square.* 2021.
36. Ugan RA, Un H. The Protective Roles of Butein on Indomethacin Induced Gastric Ulcer in Mice. *Eurasian J Med.* 2020;52(3):265-70.
37. Panico AM, Cardile V, Garufi F, Puglia C, Bonina F, Ronsisvalle G. Protective effect of *Capparis spinosa* on chondrocytes. *Life Sci.* 2005;77(20):2479-88.