

Original Article**Effect of Eggshell Nanoparticles on Healing Bone Fracture****Alhasson, F. A^{1*}, Kareem, D. A¹, Shehan, N. A¹, Ghaji, M. S¹, Abbas, B. A¹***1. College of Veterinary Medicine, University of Basrah, Basrah, Iraq*

Received 28 December 2021; Accepted 17 January 2022

Corresponding Author: firm.alhasson@uobasrah.edu.iq**Abstract**

Eggshell waste is considered the most abundant waste material from food processing technologies. Despite the freakish features that its components possess, it is very often discarded without further application. Nowadays, most researchers are focusing their research on pollution-free environment, biodegradable character, and balanced ecological aspects while fabricating the composite materials rather than mechanical strengths, costs, and processing methodologies. This study aimed to investigate the impact of the eggshell nanoparticles on the enhanced treatment of a bone fracture. The samples included 10 healthy female New Zealand white rabbits with an average body weight of 3 kg and age of 4 months years old. The animals were kept in an open place. All these ten rabbits had a fracture by making a surgical operation conducted by opening and excluding the muscle and anther tissue, followed by cutting the bone using a special small saw. After the operational step, the animals were divided into two groups (n=5). The fractures were checked by X-ray. The negative control group was left without treatment, however, was given 0.2 mL intraperitoneal saline injection weekly. The experimental group underwent treatment with 200 mg/kg of calcium carbonate nanoparticles (CaCO₃-NPs) for 4 weeks. The animals were sacrificed at the end of the study period to collect organs for histological studies. Considering the results of the radiographic examination before and after treatment with CaCO₃-NPs, the recorded data showed the speed of healing in the experimental group, compared to the control group. Regarding the histological study that was carried out on the vital organs, such as the liver, kidneys, heart, and lung, no side effects appeared when comparing the treatment group with the control group, except for some slight changes. In conclusion, the recorded data in the current study demonstrated that CaCO₃-NPs had a beneficial effect on the pace of fracture recovery.

Keywords: Calcium carbonate nanoparticles, Eggshell, Heart, Kidney, Liver, Lung**1. Introduction**

The modern era is experiencing extraordinary development in advanced synthetic approaches to novel materials and biomaterials of societal significance with the advent of nanotechnology. Similarly, the urge for developing biomedical devices, tissue grafting, and implants for use in tissue engineering purposes is growing (1, 2). Loss of bone tissue as a result of diseases, trauma, or injury is on the rise among the population and affects individuals' quality of life at a significant socio-economic value. Bone tissue transplantation is the second most common therapy,

with 2.2 million bone grafts being performed yearly worldwide (1-3). However, bone grafts from natural roots have their weaknesses; therefore, there is a need to develop biosynthetic materials to mimic the natural biomaterial bone grafts. Natural biomaterials, such as eggshells, are the most common forms of food waste. Its production is estimated at around 50,000 t per year globally (3, 4). Eggshells consist of two parts, including calcium carbonate (which is called eggshell) and an eggshell membrane (which is composed of protein structure). The chemical form of the eggshell has been investigated previously (5).

The focus of numerous researchers has been on the utilization of eggshells in different environmentally beneficial processes. The eggshell represents 11% of the total weight of the egg and is predominantly composed of calcium carbonate (94%), calcium phosphate (1%), organic matter (4%), and magnesium carbonate (1%). It is estimated that the world's egg production was approximately 6.37×10^7 t in 2010 (Global poultry trends, 2010), which in turn resulted in the generation of eggshell bio-waste. As a result, the recycling of eggshell wastes has become a great challenge that is yet to be addressed satisfactorily. Since the eggshell has about 11% out of the total egg weight, the amount of eggshells produced in the world in the last year has been estimated at around 7×10^6 t. This material is useless after the production of eggs and egg derivatives. Furthermore, in various cases, after using eggs, the bio-wastes are discarded. This kind of waste leads to environmental pollution due to the presence of adhered organic/bioorganic compounds. Moreover, these wastes smell disgusting and give rise to health challenges (6).

Bone fracture is the clinical term for a broken bone even in varying severity. A bone is broken if the force exerted on it, from a fall or impact, is stronger than the bone itself. Soon after, the bone undergoes a natural healing process that is consisted of 5 stages (7). Stage one: hematoma formation: during fracture, blood vessels are damaged that as a result create hematoma (i.e., clotted blood in the bone tissue). Stage two: granulation tissue formation (inflammation) hours later: the hematoma is reabsorbed and displaced by inflammatory molecules. The function of these molecules is to clean up the debris of broken bone and prepare the fracture site for tissue, cartilage, and bone formation. In this stage, vessels are rebuilt and cells are affected by the fracture. Stage three: callus formation: soft callus formation: these calli are constructed by osteoblasts (bone-building cells) and osteoclasts (bone-resorbing cells), which are the two types of cells needed for the natural bone remodeling process. Capillaries and

supporting blood vessels connect to the callus as the rebuilding process continues. Stage four (consolidation): the newly built bone is still soft and is called woven bone. At the end of this stage, a stronger type of bone, called lamellar bone, replaces the woven bone. Stage five: bone remodeling: the lamellar bone ultimately fills the fracture site and aligns in the direction of the external forces on the bone. This stage can last from a few months to a few years.

The purpose of the current study was to investigate the impact of calcium carbonate nanoparticles (CaCO_3 -NPs) derived from eggshells on the enhanced treatment of a bone fracture.

2. Materials and Methods

2.1. Study Design

This study was conducted on 10 healthy female New Zealand white rabbits with an average body weight of 3 kg and age of 4 months years old. The animals were kept in an open place. General anesthesia was achieved using a mixture of ketamine (40 mg/kg) and xylazine (8 mg/kg) with intramuscular injection, resulting in losing consciousness after a few minutes. After that that the animals were anesthetized within 5 min, they had a fracture by making a surgical operation, including opening and excluding the muscle and another tissue, followed by cutting the bone using a special small saw (Figure 1). After the operational step, the animals were divided into two groups (n=5) (Figure 2). The fractures were checked by X-ray. The negative control group was left without treatment, however, was given 0.2 mL intraperitoneal saline injection weekly. The experimental group underwent treatment with 200 mg/kg of CaCO_3 -NPs (8) for 4 weeks. The animals were sacrificed at the end of the study period to collect organs for histological studies (figures 2 and 3). The CaCO_3 -NPs were prepared according to the methods previously described by Zakaria and Hammoodi (9). In the experimental group, the eggshell nanoparticles were injected into the peritoneum area.

2.2. Histological Study

After scarifying the animals, the organs were fixed by immersion in 10% neutral buffered formalin for at least 48 h. After fixation, the organs were sectioned generating 2 longitudinal sections. In order to fit in cassettes, these longitudinal samples were then cut cross-sectionally to generate 4 sections. All samples were processed with paraffin, and 5 μm sections were stained with hematoxylin and eosin (H&E).

3. Results and Discussion

Fracture healing with a bone deformity is a notable clinical concern. Non-union is a complication of segmental destruction recognized in defects of bones (10). The main challenge in successful bone healing and new bone formation is the growth of the soft tissue process which may disrupt the osteogenesis and cause bone non-union. These deficits impact the patient's daily activities as a consequence of limb length variance and extended treatment. Furthermore, the treatment imposes high costs that affect the patients economically. The current treatment of bone fractures involves the use of the Ilizarov technique which leads to osteogenesis diversion (11). This kind of treatment has several complications, such as the infection of a pin site, massive implant, high cost, and long-term hospitalization. Recently, anabolic bone-forming factors have been established on animal model fractures. In this study, the ulnar bone was selected for several reasons. Firstly, the ulnar bone is a common site for bone fractures and segmental bone loss in humans. Secondly, the ulnar bone has an appropriate size to be used and it is easy to access during operations since there is less amount of soft tissue surrounded. Moreover, its location is subcutaneous which helps in surgery. A 2-mm bone spot was performed in this study to observe the differences in the process of the physiological repair through the fracture gap between the CaCO_3 treated group and the control group. According to the results of an earlier study, in a short period, bone healing was

incomplete and associated with immature bone and fibrous connective tissues (12). Therefore, it is perfect to assess the agent's role in the healing process. As the callus formation time is valuable to evaluate the quantity and quality of bone healing, the CaCO_3 -NPs treated group showed significant progress, compared to the control group (13). Since the bone was reconstructed during animal life, the tissue quality was accomplished during a short period. Usually, bone regeneration is inducted from the periosteum (periosteal callus) and develops in an encompassing guide from the surface to the center of the impact. The regeneration of bone without periosteum occurs with a straight ornament from the original response callus to the medullary callus. The bone proximal calluses develop faster than the distal ones. In this study, the periosteum was removed from the control and experimental groups to exert a negative impact on bone healing. The findings of the study showed that the experimental group still progressed even when the periosteum was removed. That means that CaCO_3 -NPs were useful in the case of periosteum removal. Based on the results of studies, the periosteum is vital for hastening bone growth after divesting since its growth speeds up following the transection and resection of periosteum (14, 15). The findings of studies have indicated that the transverse transection of the longitudinal periosteal fibers seems to be the most crucial perspective in stimulating growth (16, 17). Radiographic examinations of the ulna of rabbits before the treatment (Figure 1) and ulna of rabbits treated with CaCO_3 -NPs were performed at the end of the study. The samples showed radiomic association at the end of the four-week study in the treatment group (Figure 2). However, a gap remained between the two ends of the ulna in the control group (Figure 3). Considering the above results, it was evident that CaCO_3 -NPs treatment significantly improved fracture healing in the treatment group. The rates of union and non-union were evaluated using X-rays in the two groups.

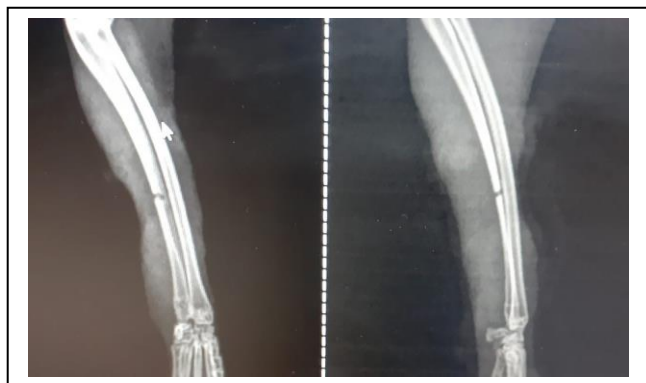


Figure 1. Radiographic examination of the ulna of rabbits in the two groups before the treatment

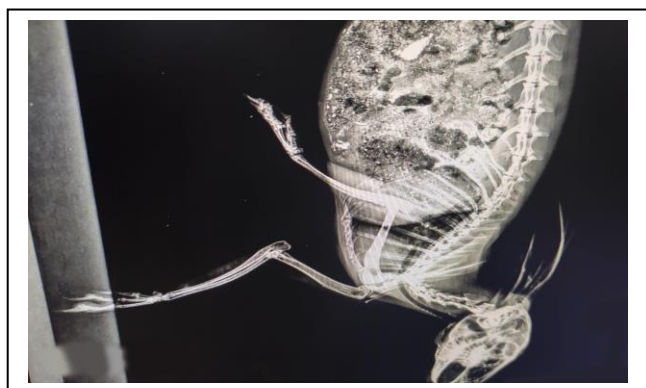

Figure 2. Radiographic association at the end of the four-week study in the treatment group

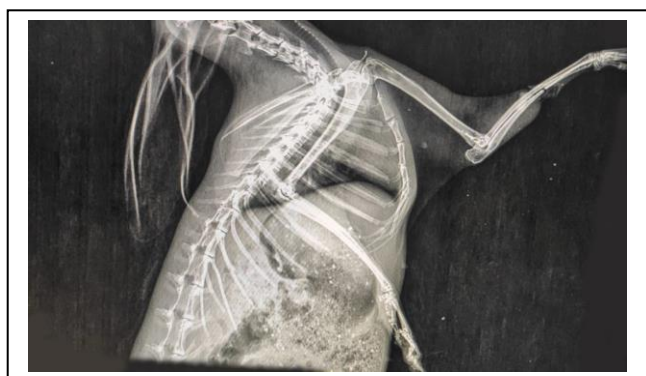

Figure 3. Radiographic results showing a gap remained between the two ends of the ulna in the control group

3.1. Histological Study

The findings of the current study showed that injection of CaCO_3 -NPs into the peritoneum area in rabbits for four weeks did not affect the liver, lung, heart, and kidneys and they were in normal status when comparing the treated group with the control group. After making tissue sections

of these organs, the results showed some histological changes as follows. Most of the risk assessments for nanomaterials have focused on configuration, structure, and exterior exposure, with few surveys of epidemiological studies on the health effects of exposure to nanomaterials.

3.1.1. Liver

No significant difference was observed between the control group and the treatment group as shown in figures 4, 5, 6, and 7. The hepatocytes were normal with polygonal shape, presence of the central vein with hepatic sinuses, and portal area. These results were in agreement with those of a study previously conducted by Fu, Yang (18).

3.1.2. Kidney

Renal section of the control group revealed a normal morphology, including a distinct glomerulus and Bowman's capsule with adjacent proximal and distal convoluted tubules (Figure 8), while the kidney sections of the experimental group showed some remarkable abnormalities, as shown in (Figure 9). Necrosis lesion and tubular dilatation were observed, compared to the control group (Figures 10 and 11), this result was consistent with that reported in previous works of literature (19). The effect of CaCO_3 -NPs on the kidney is related to the higher dose.

3.1.3. Lung

Calcium carbonate had a slight effect on lung tissue (figures 12 and 13). This effect depends on the size and chemical composition of nanomaterials which affect their toxicity (20-22). Nanomaterials might also perform a role in increasing the cytotoxicity of nanoparticles, which is considered a contributing factor (23). Hemorrhage in the alveoli's wall was the most histological change found in the treated group samples.

3.1.4. Heart

The study did not find any histological changes in cardiac histological sections between the control group and the treatment group (Figures 14 and 15).

In conclusion, the results of the current study demonstrated that CaCO_3 -NPs had a beneficial effect on the pace of fracture recovery. However, more investigations are highly suggested to evaluate the health effects of the CaCO_3 -NPs on the vital organs.

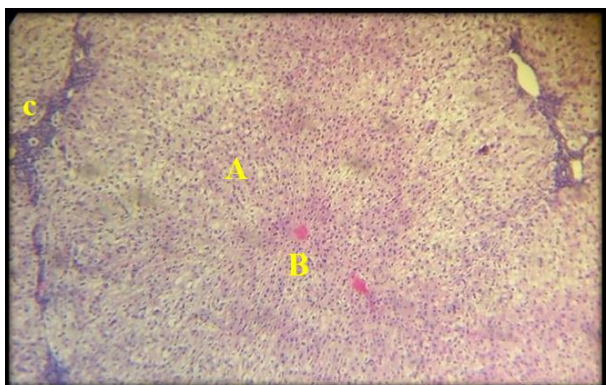


Figure 4. Histological structure of liver in the control group; normal hepatocytes (A), portal vein (B), and portal area (C) (H&E; 10x)

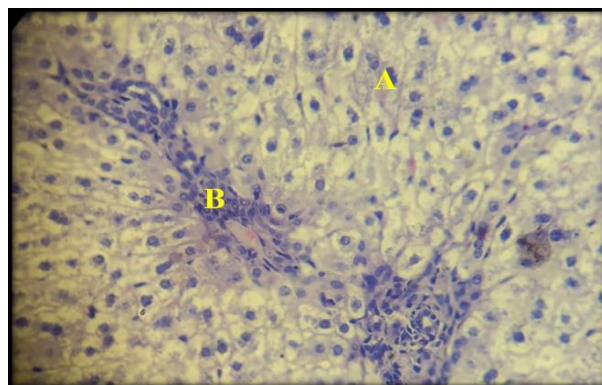


Figure 7. Histological structure of liver in the treatment group; normal hepatocytes (A) and portal area (B) (H&E; 40x)

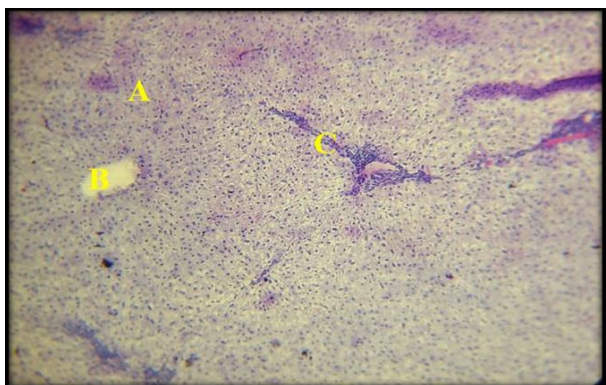


Figure 5. Histological structure of liver in the treatment group; normal hepatocytes (A), portal vein (B), and portal area (C) (H&E; 10x)

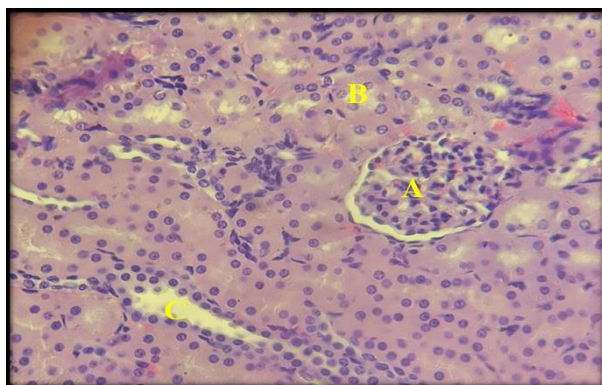


Figure 8. Histological structure of kidney cortex in the control group; normal structure of renal corpuscle (A), proximal convoluted tubule (B), and distal convoluted tubule (C) (H&E; 40x)

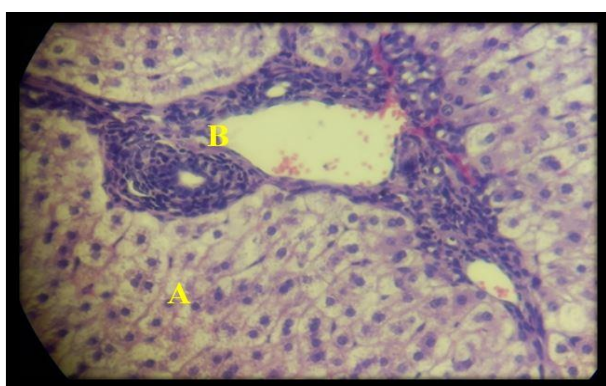


Figure 6. Histological structure of liver in the control group; normal hepatocytes (A) and portal area (B) (H&E; 40x)

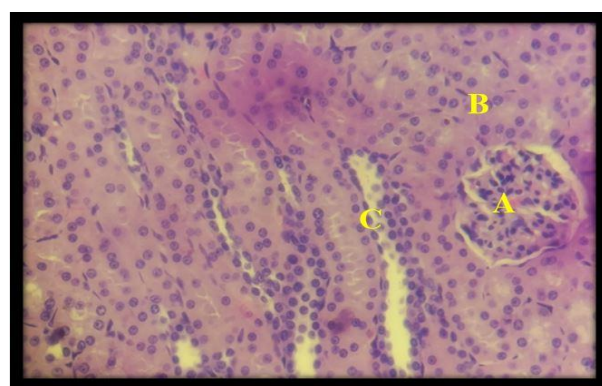


Figure 9. Histological structure of kidney cortex in the treatment group; normal structure of renal corpuscle (A), proximal convoluted tubule (B), and distal convoluted tubule (C) (H&E; 40x)

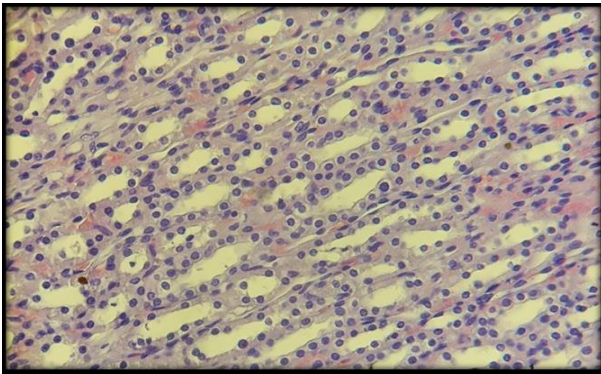


Figure 10. Histological structure of kidney medulla in the control group; normal structure of collecting tubule (H&E; 40x)

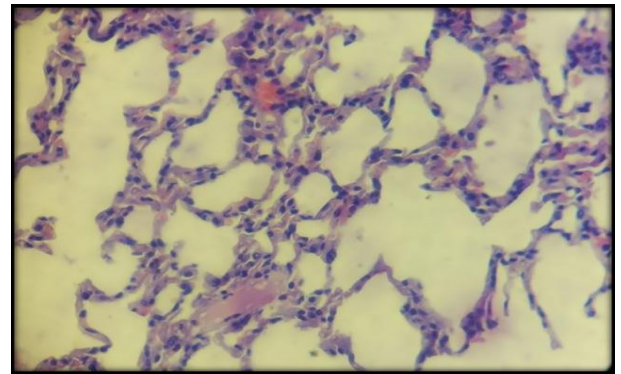


Figure 13. Histological structure of lung in the treatment group; normal structure of alveoli and bleeding (H&E; 40x)

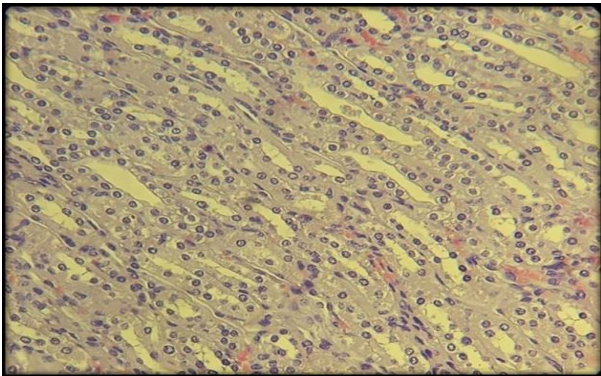


Figure 11. Histological structure of kidney medulla in the treatment group; normal structure of collecting tubule (H&E; 40x)

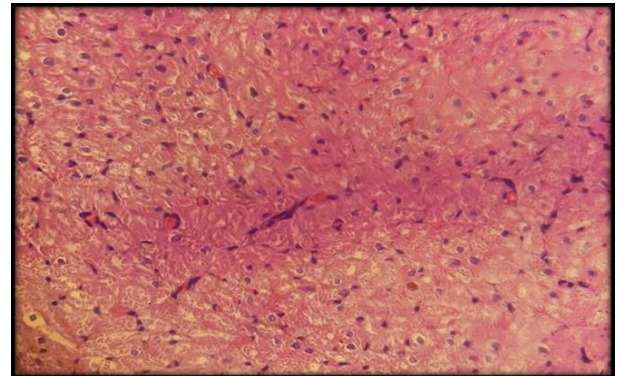


Figure 14. Histological structure of heart in the control group; normal structure of cardiac muscle (H&E; 40x)

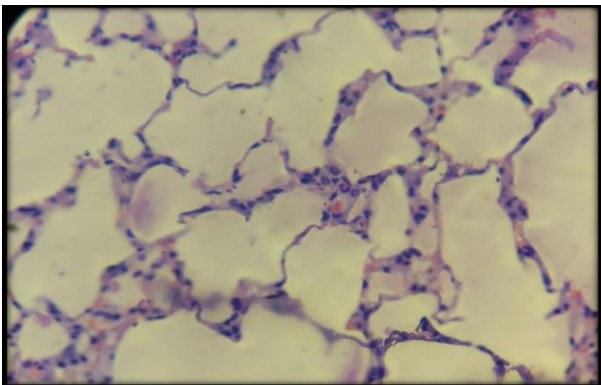


Figure 12. Histological structure of lung in the control group; normal structure of alveoli (H&E; 40x)

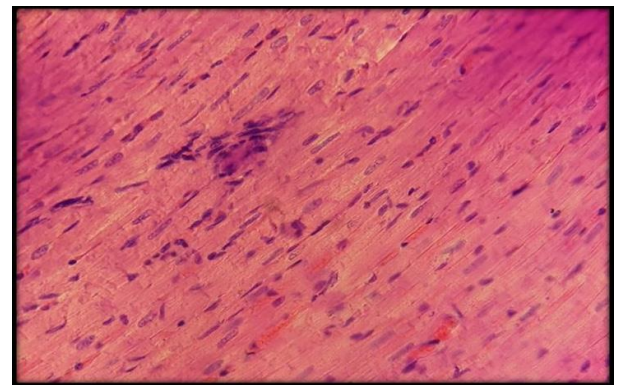


Figure 15. Histological structure of heart in the treatment group; normal structure of cardiac muscle (H&E; 40x)

Authors' Contribution

Study concept and design: F. A. A.

Acquisition of data: N. A. S.

Analysis and interpretation of data: B. A. A.

Drafting of the manuscript: D. A. K.

Critical revision of the manuscript for important intellectual content: M. S. G.

Statistical analysis: F. A. A.

Administrative, technical, and material support: B. A. A.

Ethics

This study was evaluated by the Ethics Committee of the Department of Histology, Faculty of Veterinary Medicine, University of Basrah, Basrah, Iraq. During the experiment, daily checks and inspections were performed by an authorized and certified person from the Ethics Committee.

Conflict of Interest

The authors declare that they have no conflict of interest.

References

- Ahmed TA, Suso H-P, Hincke MT. In-depth comparative analysis of the chicken eggshell membrane proteome. *J Proteomics*. 2017;155:49-62.
- Alcaraz-Espinoza JJ, de Melo CP, de Oliveira HP. Fabrication of highly flexible hierarchical polypyrrole/carbon nanotube on eggshell membranes for supercapacitors. *Acs Omega*. 2017;2(6):2866-77.
- Baláz M, Ficeriová J, Briančin J. Influence of milling on the adsorption ability of eggshell waste. *Chemosphere*. 2016;146:458-71.
- Declerck V, Nun P, Martinez J, Lamaty F. Solvent-free synthesis of peptides. *Angew Chem Int*. 2009;48(49):9318-21.
- Li Y, Zhou J, Fan Y, Ye Y, Tang B. Preparation of environment-friendly 3D eggshell membrane-supported anatase TiO₂ as a reusable photocatalyst for degradation of organic dyes. *Chem Phys Lett*. 2017;689:142-7.
- Khairol NF, Sapawe N, Danish M. Excellent performance integrated both adsorption and photocatalytic reaction toward degradation of congo red by CuO/eggshell. *Materials Today: Proceedings*. 2019;19:1340-5.
- Morgan EF, De Giacomo A, Gerstenfeld LC. Overview of Skeletal Repair (Fracture Healing and Its Assessment). *Skeletal Development and Repair*: Springer; 2021. p. 17-37.
- Campbell-Ward ML. Gastrointestinal physiology and nutrition. *Ferrets, rabbits, and rodents*: Elsevier; 2012. p. 183-92.
- Zakaria AB, Hammoodi OT. A new approach to synthesis of nanoparticles derived from eggshell effect on brain of mice. 2020.
- Fayaz HC, Giannoudis PV, Vrahas MS, Smith RM, Moran C, Pape HC, et al. The role of stem cells in fracture healing and nonunion. *Int Orthop*. 2011;35(11):1587-97.
- Rahal SC, Volpi RS, Ciani RB, Vulcano LC. Use of the Ilizarov method of distraction osteogenesis for the treatment of radial hemimelia in a dog. *J Am Vet Med Assoc*. 2005;226(1):65-8.
- Passeri G, Cacchioli A, Ravanetti F, Galli C, Elezi E, Macaluso GM. Adhesion pattern and growth of primary human osteoblastic cells on five commercially available titanium surfaces. *Clin Oral Implants Res*. 2010;21(7):756-65.
- Tarantino U, Celi M, Saturnino L, Scialdoni A, Cerocchi I. Strontium ranelate and bone healing: report of two cases. *Clin Cases Miner Bone Metab*. 2010;7(1):65.
- Caston SC, Reinertson EL, Kersh K. How to make, place, and remove transphyseal staples. 2011.
- Urban IA, Jovanovic SA, Lozada JL. Vertical ridge augmentation using guided bone regeneration (GBR) in three clinical scenarios prior to implant placement: a retrospective study of 35 patients 12 to 72 months after loading. *Int J Oral Maxillofac Implants*. 2009;24(3).
- Limpaphayom N, Prasongchin P. Surgical technique: Lower limb-length equalization by periosteal stripping and periosteal division. *Clin Orthop Relat Res*. 2011;469(11):3181-9.
- Hernandez J, Serrano S, Marinoso M, Aubia J, Lloreta J, Marrugat J, et al. Bone growth and modeling changes induced by periosteal stripping in the rat. *Clin Orthop Relat Res*. 1995(320):211-9.
- Fu S, Yang L, Li P, Hofmann O, Dicker L, Hide W, et al. Aberrant lipid metabolism disrupts calcium homeostasis causing liver endoplasmic reticulum stress in obesity. *Nature*. 2011;473(7348):528-31.
- Khan M, Mostofa M, Jahan M, Sayed M, Hossain M. Effect of garlic and vitamin B-complex in lead acetate

- induced toxicities in mice. Bangladesh J Vet Med. 2008;6(2):203-10.
20. Gattoo MA, Naseem S, Arfat MY, Mahmood Dar A, Qasim K, Zubair S. Physicochemical properties of nanomaterials: implication in associated toxic manifestations. Biomed Res Int. 2014;2014.
21. Guarch CP, López DR, Salse JS, Linares JG, Suárez MB, de Lapuente Pérez J. Basis for the toxicological evaluation of engineered nanomaterials. Rev Toxicol. 2014;31(1):9-22.
22. Yang H, Liu C, Yang D, Zhang H, Xi Z. Comparative study of cytotoxicity, oxidative stress and genotoxicity induced by four typical nanomaterials: the role of particle size, shape and composition. J Appl Toxicol. 2009;29(1):69-78.
23. Brunner TJ, Wick P, Manser P, Spohn P, Grass RN, Limbach LK, et al. In vitro cytotoxicity of oxide nanoparticles: comparison to asbestos, silica, and the effect of particle solubility. Environ Sci Technol. 2006;40(14):4374-81.