

**Original Article**

# Effect of Kisspeptin-54 on Testicular Degeneration Induced by Cadmium Chloride

Ali Hameed, M<sup>1</sup>, Sabah AL-Khalidi, Z<sup>1</sup>, Abdulhussein Hasan, M<sup>2</sup>, Sabah Bustani, G<sup>3,4\*</sup>

1. Medical Laboratory Technology Department, College of Medical Technology, the Islamic University, Najaf, Iraq

2. College of Medicine, University of Al-Ameed, Karbala, Iraq

3. College of Dentistry, the Islamic University, Najaf, Iraq

4. College of Nursing, Altoosi University College, Najaf, Iraq

Received 15 November 2021; Accepted 4 December 2021

Corresponding Author: bustani@iunajaf.edu.iq

---

## Abstract

Adult males are considered the main causes of infertility defects in the world; therefore, scientists are searching for factors that play a role in male fertility, such as kisspeptin, which acts as one of the master controllers and regulators of gonadotropin secretion from the hypothalamus in mammalian species. Furthermore, it has been shown that the kisspeptin receptor is mainly localized in the interstitial and germ cells of the testicles and has a role in the regulation of gonadal development and function. This study aimed to investigate the effect of kisspeptin on testicular degeneration syndrome induced by cadmium chloride in male Wistar rats and identify the best concentration of kisspeptin to cure this syndrome. A total of 40 male rats were divided into four equal groups of negative control (n=10) that was injected subcutaneously (SC) with normal saline solution twice a week for 42 days; positive control (n=10) that was intraperitoneally injected with cadmium chloride (1 mg/kg B.W., once a week for two weeks); T<sub>1</sub> that was intraperitoneally injected with cadmium chloride (1 mg/kg B.W., once a week for two weeks), and after 14 days, 20 nmol/rat of kisspeptins were injected SC twice a week for 42 days in all animals; and T<sub>2</sub> that was intraperitoneally injected with cadmium chloride (1 mg/kg B.W. once a week for two weeks), and after 14 days, 40 nmol/rat of kisspeptins were injected SC twice a week for 42 days in all animals. All animals were then euthanized after 42 days, and their testes were dissected for a histological study. The results of the present study confirmed that cadmium chloride affected the male testes and sperm parameters, while the administration of kisspeptin at doses of 20 and 40 nmol/rat (twice a week) by SC injection showed a significant effect in restoring the reproduction feature and histology of the rats' testicular tissue.

**Keywords:** Cadmium chloride, Fertility, Kisspeptin, Testicular degeneration

---

## 1. Introduction

Infertility is a worldwide problem, in which reproductive vigor is deteriorating and has an effect on the physical and social wellbeing of an infertile double couple (1). Nowadays, scientists are searching for factors that play a role in adult male fertility, such as kisspeptin (2). The kisspeptins are peptide hormones (3) and neuromodulator peptides that regulate gonadotropin-releasing hormone (GnRH) secretion and mediate endocrine function to control reproduction (4).

Kisspeptin initially was called Metastin since it has the ability to suppress metastasis of melanomas (5). Accordingly, kisspeptin pathways lead to a better prognosis in patients with malignant disease (6). Researchers during the last two decades have indicated the role of kisspeptin in the central nervous system and reproduction organs (7). Kisspeptin receptor GPR54 was shown of high expression in the pancreas, particularly in the hypothalamus, midbrain, medulla, thalamus, pons, hippocampus, pituitary amygdala,

cortex, frontal cortex, brain regions, and striatum, as well as spinal cord and placenta (8).

Hypogonadotropic hypogonadism (HH) due to problems with either the hypothalamus or pituitary gland, affect the hypothalamic-pituitary-gonadal axis (HPG axis). HH may occur due to the mutations of KISS1 or GPR54. The kisspeptin may be used as a treatment to cure HH infertility (9). Moreover, it exerts its effect through the stimulation of the GnRH secretion from the hypothalamus; thereafter, due to the activation of the HPG axis, steroidogenesis is increased, and consequently, it may lead to an increase in the secretion of the luteinizing hormone and testosterone that causes either pubertal activation of senescence in testis (10). Infertility is a predominant illness affecting a valued 70 million people worldwide. The World Health Organization estimates that the male factor contributes to 50% of infertility (11). Testicular degeneration is regarded as a major problem of infertility and sperm production in which the overall sperms are damaged and defected in their functions, such as general motility, viability, and concentration in the eventual loss of capitation on fertility (12). In fact, kisspeptin reinforces and enhances spermatogenesis cell generation in testis and has a positive potential role as a pharmacological target in the treatment of human spermatogenesis abnormalities (2). Given the potential indication for reproductive health and an unconventional strategy for the treatment of infertility (13), as well as the pivotal role the Leydig cells play in peripheral and neuroendocrine modulation of male reproduction (14), this study aimed to find the effect of kisspeptin as a treatment for testicular degeneration syndrome in male rats induced by cadmium chloride (CdCl<sub>2</sub>) and identify the best concentration of treatment for this syndrome.

## 2. Materials and Methods

### 2.1. Animals

A total of 40 adult male Wistar rats were used in this study (body weight: 250-350 gr). The animals were housed in clean cages kept in the animal house at the Faculty of Veterinary Medicine, University of Kufa,

Kufa, Iraq. Animals had *ad-libitum* access to food and water during the experiments. The animals were maintained at about two weeks for adaptation before starting the experiment.

### 2.2. Experiment Design

A total of 40 male rats were divided into four equal groups of negative control (n=10) that was injected subcutaneously (SC) with normal saline solution twice a week for 42 days; positive control (n=10) that was intraperitoneally injected with cadmium chloride (1 mg/kg B.W., once a week for two weeks); T<sub>1</sub> that was intraperitoneally injected with cadmium chloride (1 mg/kg B.W., once a week for two weeks), and after 14 days, 20 nmol/rat of kisspeptins were injected SC twice a week for 42 days in all the animals; and T<sub>2</sub> that was intraperitoneally injected with cadmium chloride (1 mg/kg B.W., once a week for two weeks), and after 14 days, 40 nmol/rat of kisspeptins were injected SC twice a week for 42 days in all animals. All animals were euthanized after 42 days, and the testes were dissected for a histological study (15).

### 2.3. Histopathological Study

The testes were excised and opened longitudinally and preserved in 10% formalin solution until the preparation of the histological sections. Several tissue sections were prepared according to Lee and Luna (16). The tissue samples taken from organs and specimens were fixed in 10% formalin-buffered for 48 h at room temperature. After the procedures of fixation, the tissues were dehydrated in alcohol, cleared at two stages of xylene, and implanted in liquid paraffin for 2 h at 56°C. The tissues were then cut at 5 micrometers by a microtome for sectioning. In the end, they were dewaxed and stained with Eosin and Harris Haematoxylin (H&E), and the sections were studied using 4×, 10×, and 40× objectives of light microscopy.

### 2.4. Statistical Analysis

Statistical analysis of the experimental results was conducted according to Prism (17). Moreover, t-test and one-way ANOVA were used to assess the significance of differences among groups and within times. The data were expressed as mean±standard

errors (SE), and a *P*-value less than 0.05 was considered statistically significant. It is worth mentioning that LSD was carried out to test the significant level among the means of treatment (17).

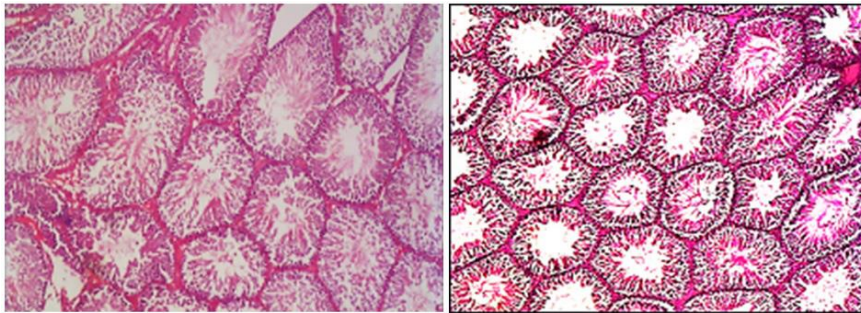
### 3. Results

The results of the histopathology study showed that the testicular differentiation occurred during the study. Figure 1 illustrates the normal section of the control group, while figure 2 depicts the induction of testicular degeneration by the injection of CdCl<sub>2</sub> (1 mg/kg B.W., intraperitoneally, once a week for two weeks), which caused clear blood vessel congestion and a significant decrease in the wall thickness leading to testicular degeneration, compared to figure 1 which showed no

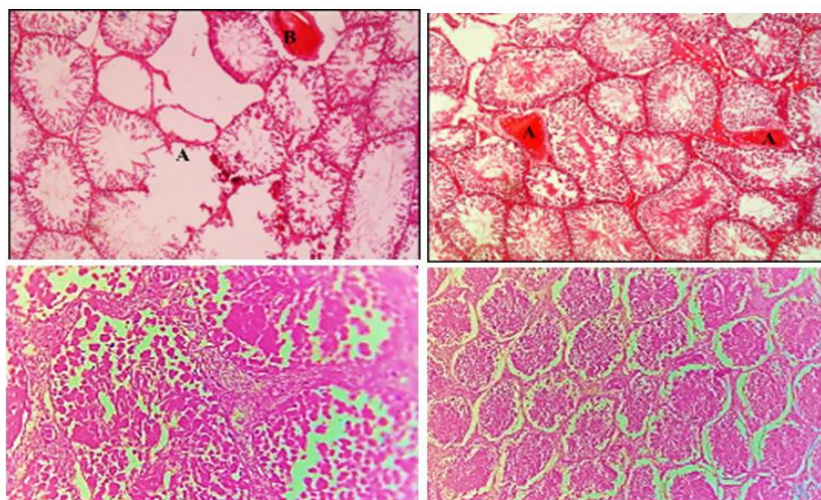
significant occupied lesion in the histological section of the testis in the control group.

On the other hand, figures 3 and 4 depict that the testicular germinal layers come back to the normal state through the regeneration activities after treatment with 20 and 40 umol of kisspeptin in which testicular tissue gets back to the normal texture (regenerative process) after 42 days. On the other hand, the histopathological section of the positive control group in figure 1 shows that the losing of germinal epithelial and blood vessels is congested with dilation of its wall and an increase in thickness.

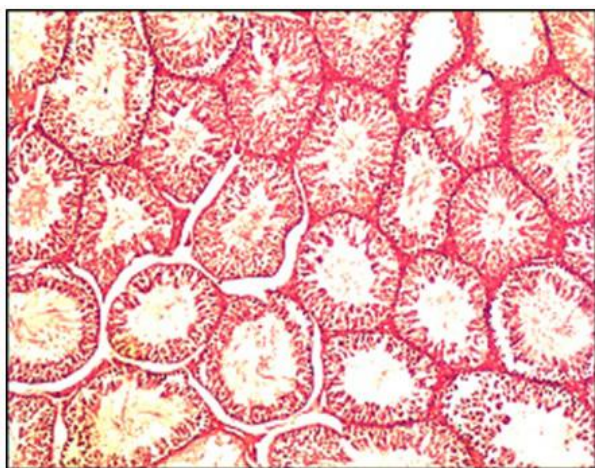
Figures 3 and 4 illustrate the completely reaped normal lesion of the testicular tissue treatment with 20 and 40 umol of kisspeptin, compared to the positive control group in figure 1 and the negative control group in figure 2.



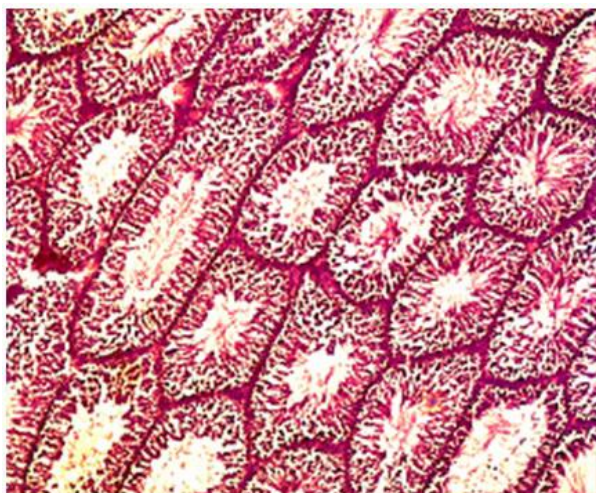
**Figure 1.** Histological section of testis in the negative control group shows no significant occupied lesion. The rats in this group were injected with normal saline. The section is stained with H&E stain and is captured with a 20× magnifier scale.



**Figure 2.** Histopathological section of the testis in the positive control group (induction of testicular degeneration). The histopathological section of the testis shows clear blood vessel congestion and decreased wall thickness. Moreover, it shows damages in the testicular septa, clear sloughing of germinal epithelium, and interstitial cells of Leydig. The section is stained with H&E stain and is captured with a 20× magnifier.



**Figure 3.** Histopathological section of the testis shows that the testicular tissue gets back to the normal texture (regenerative process) after treatment with 20 mg of kisspeptin for 42 days. The section is stained with H&E stain and is captured with a 20× magnifier scale.



**Figure 4.** Histopathological section of the testis shows that the testicular tissue gets back to the normal texture (regenerative process) after treatment with 40 mg of kisspeptin for 42 days. The section is stained with H&E stain and is captured with a 20× magnifier scale.

#### 4. Discussion

An initial objective of this study was to identify the effects of kisspeptin on the testicular degeneration syndrome treatment and find the effective dose of kisspeptin administration. This is the first detailed study to evaluate and investigate the effectiveness of different concentrations of kisspeptin in the rats' testis tissues. Our data suggest that the administration of

kisspeptin-54 can relieve testicular degeneration and target the kisspeptin system to treat diseases. The beneficial effects of kisspeptin to cure induced testicular degeneration in male rats were previously mentioned in the literature (18).

According to Mahmoud, Al-Dhalimy (19), CdCl<sub>2</sub> at a dose of 1 mg/kg B.W. intraperitoneally injected once a week for two weeks can induce testicular degeneration in male rats. Several studies have revealed that CdCl<sub>2</sub> causes histological changes in the testis (20). These histological damages occurred via the production of reactive oxygen species (ROS), known as oxidative stress, which plays a key role in apoptosis and cell damages. Among the mechanisms of the toxicity of CdCl<sub>2</sub> on testes, a failure in blood circulation is considered another damaging mechanism. This is because of vascular damage and a drop in zinc utilization by spermatogenic cells due to the competitive sorption of cadmium and zinc (20). Due to this competition between Cd and Zn, lipid flexibility and sperm membrane stabilization are reduced (21).

Overall, in the present study, the results in figures 1 and 2 indicate that cadmium chloride causes reversible testicular degeneration after 14 days. All these results are in line with the findings of previous studies (22) which found that cadmium significantly destroyed the sperms, as well as Leydig and Sertoli cells. Moreover, it caused an increase in the death of cells and a reduction in the germinal layer, which decreased the thickness in the seminiferous tubules (23).

In general, the protective effect of kisspeptin on the hypothalamic-pituitary-testicular axis and the testicles was clearly demonstrated in this study. Kisspeptin can decrease apoptosis and cellular damage due to oxidative stress in the Leydig and spermatogenic cells in the seminiferous tubules. Accordingly, the kisspeptin administration leads to a significant increase in testosterone concentration, and it can improve the activities of antioxidants and inhibits the generation of ROS (24).

Kisspeptin helps to reduce the damage to the DNA, the testicular tissue, and sperm membrane lipids which

reduce the lipid peroxidation (LPO) and enhance antioxidant levels in rats (25). The degeneration of testicles following CdCl<sub>2</sub> exposure due to the reinforcement of ROS action and LPO in the present study was treated with the function of antioxidant effect and regulatory effect of kisspeptin to decrease the oxidative stress. Oxidative stress and lipid peroxidation are decreased by kisspeptin. Therefore, it prevents induced damages on the DNA of spermatozoa and seminiferous tubules (13, 24).

The result of the pathological examination showed that CdCl<sub>2</sub> caused hemorrhage in the capillaries of testes, degeneration of the seminiferous tubules, as well as testicular infarction and degeneration. The testis is extremely sensitive to CdCl<sub>2</sub> toxicity, and researchers showed that it led to testicular edema, germ cell loss, hemorrhage, interstitial fibrosis, and sterility in a few mammalian species (26). Histological examination of our pilot test indicated that the administration of 1 mg/kg B.W of CdCl<sub>2</sub> caused reversible histological changes, which is in line with the results of previously published studies showing that the CdCl<sub>2</sub> led to testicular toxicity and degeneration at a dose of 1 mg/kg B.W in the male rats (25).

Several studies have revealed that kisspeptin improved spermatogenic cell proliferation (27). In our study, spermatogonia within the seminiferous tubules were increased by using kisspeptin in two concentrations as shown in figures 3 and 4. These findings are in agreement with the results of previously published studies (28, 29). In general, it is confirmed that CdCl<sub>2</sub> affects the male testes and sperm parameters, while the administration of the kisspeptin at the doses of 20 and 40 nmol/rat (twice a week) by SC injection showed a significant effect in restoring the reproduction features and histology of the rats' testicular tissue.

#### Authors' Contribution

Study concept and design: M. A. H.

Acquisition of data: Z. S. A.

Analysis and interpretation of data: M. A. H.

Drafting of the manuscript: G. S. B.

Critical revision of the manuscript for important intellectual content: M. A. H.

Statistical analysis: M. A. H.

Administrative, technical, and material support: M. A. H.

#### Ethics

This research was approved by the College of Medical Technology, the Islamic University, Najaf, Iraq

#### Conflict of Interest

The authors declare that they have no conflict of interest.

#### References

1. Alam F, Khan TA, Rehman R. Stress of infertility: Can the couple cope? 2018.
2. Feng T, Bai JH, Xu XL, Liu Y. Kisspeptin and its effect on mammalian spermatogenesis. *Curr Drug Metab* 2019;20(1):9-14.
3. Kumar M, Basumatary G, Ram RK, Singh DK, Udit UK. Comparative Studies on Kisspeptin Receptor and Their Physicochemical Characterization. *Int J Curr Microbiol Appl Sci*. 2018;7(5).
4. Skorupskaite K, George JT, Anderson RA. The kisspeptin-GnRH pathway in human reproductive health and disease. *Hum Reprod Update*. 2014;20(4):485-500.
5. Lee J-H, Miele ME, Hicks DJ, Phillips KK, Trent JM, Weissman BE, et al. KiSS-1, a novel human malignant melanoma metastasis-suppressor gene. *J Natl Cancer Inst*. 1996;88(23):1731-7.
6. Stathaki M, Stamatou ME, Magioris G, Simantiris S, Syrigos N, Dourakis S, et al. The role of kisspeptin system in cancer biology. *Crit Rev Oncol Hematol*. 2019;142:130-40.
7. Wassie T, Liu G, Jiang X, Tesema B, Han Y, Zhao J, et al. Immunization against Kisspeptin-54 perturb hypothalamic–pituitary–testicular signaling pathway in ram lambs. *Theriogenology*. 2019;125:193-202.
8. Thompson EL, Murphy KG. Modulation of the hypothalamic-pituitary-gonadal axis by selective ligands of the KISS1R. *Curr Opin Investig Drugs*. 2010;11(4):432-9.

9. Trevisan CM, Montagna E, de Oliveira R, Christofolini DM, Barbosa CP, Crandall KA, et al. Kisspeptin/GPR54 system: what do we know about its role in human reproduction? *Cell Physiol Biochem*. 2018;49(4):1259-76.
10. Patterson M, Murphy K, Thompson E, Patel S, Ghatei M, Bloom S. Administration of kisspeptin-54 into discrete regions of the hypothalamus potently increases plasma luteinising hormone and testosterone in male adult rats. *J Neuroendocrinol*. 2006;18(5):349-54.
11. Fainberg J, Kashanian JA. Recent advances in understanding and managing male infertility. *F1000Res*. 2019;8.
12. Baiee F, Al-Wahab BA, Almusawi AA, Yu LL, Fitri W-N, Bustani GS. Effect of vitrification on spermatozoa quality in bull semen. *EurAsian J Biosci*. 2020;14(2):3897-904.
13. Bustani GS, Baiee FH. Semen extenders: An evaluative overview of preservative mechanisms of semen and semen extenders. *Vet World*. 2021;14(5):1220.
14. Salehi S, Adeshina I, Chen H, Zirkin BR, Hussain MA, Wondisford F, et al. Developmental and endocrine regulation of kisspeptin expression in mouse Leydig cells. *Endocrinology*. 2015;156(4):1514-22.
15. Sharma A, Thaventhiran T, Minhas S, Dhillo WS, Jayasena CN. Kisspeptin and Testicular Function—Is It Necessary? *Int J Mol Sci*. 2020;21(8):2958.
16. Lee G, Luna H. Manual of histological staining methods of the armed forces. New York, Toronto, London, Sydney: Institute of Pathology, American Registry of Pathology. 1968:68-9.
17. Prism G. Prism 8 for windows. GraphPad Software Inc. 2019.
18. Khafaga AF, Abd El-Hack ME, Taha AE, Elnesr SS, Alagawany M. The potential modulatory role of herbal additives against Cd toxicity in human, animal, and poultry: A review. *Environ Sci Pollut Res Int*. 2019;26(5):4588-604.
19. Mahmoud M, Al-Dhalimy A, Al-Dujaily A. Study of hematological and biochemical changes in sheep and goats infected with theileriosis at Al-Najaf province, Iraq. *Biochem Cell Arch*. 2019;19(1):803-6.
20. Amara S, Abdelmelek H, Garrel C, Guiraud P, Douki T, Ravanat J-L, et al. Preventive effect of zinc against cadmium-induced oxidative stress in the rat testis. *J Reprod Dev*. 2008;54(2):129-34.
21. Ali H, Ahmed M, Baig M, Ali M. Relationship of zinc concentrations in blood and seminal plasma with various semen parameters in infertile subjects. *Pak J Med Sci*. 2007;23(1):111.
22. Nna VU, Ujah GA, Mohamed M, Etim KB, Igba BO, Augustine ER, et al. Cadmium chloride-induced testicular toxicity in male wistar rats; prophylactic effect of quercetin, and assessment of testicular recovery following cadmium chloride withdrawal. *Biomed Pharmacother*. 2017;94:109-23.
23. Mahmoudi R, Azizi A, Abedini S, Jahromi VH, Abidi H, Barmak MJ. Green tea improves rat sperm quality and reduced cadmium chloride damage effect in spermatogenesis cycle. *J Med Life*. 2018;11(4):371.
24. Abou Khalil NS, Mahmoud GB. Reproductive, antioxidant and metabolic responses of Ossimi rams to kisspeptin. *Theriogenology*. 2020;142:414-20.
25. Gupta SC, Mishra M, Sharma A, Balaji TD, Kumar R, Mishra RK, et al. Chlorpyrifos induces apoptosis and DNA damage in *Drosophila* through generation of reactive oxygen species. *Ecotoxicol Environ Saf*. 2010;73(6):1415-23.
26. Hassanzadeh N, Mortazavi S. Sublethal effects of cadmium chloride to testis of zebrafish (*Danio rerio*). *J Persian Gulf*. 2016;7(23):51-60.
27. Delbarco-Trillo J, Tourmente M, Varea-Sánchez M, Roldan ER. Is male reproductive senescence minimized in *Mus* species with high levels of sperm competition? *Biol J Linn Soc*. 2018;123(2):463-70.
28. Khamis T, Abdelalim AF, Abdallah SH, Saeed AA, Edress NM, Arisha AH. Early intervention with breast milk mesenchymal stem cells attenuates the development of diabetic-induced testicular dysfunction via hypothalamic Kisspeptin/Kiss1r-GnRH/GnIH system in male rats. *Biochim Biophys Acta Mol Basis Dis*. 2020;1866(1):165577.
29. Azizi V, Oryan S, Khazali H, Hosseini A. Central injection of neuropeptide Y modulates sexual behavior in male rats: interaction with GnRH and kisspeptin/neurokinin B/dynorphin. *Int J Neurosci*. 2021;131(8):780-8.