

Original Article

Experimental Evaluation of Mouse Hind Paw Edema Induced by Iranian *Naja oxiana* Venom

**Esmaili, A¹, Kamyab, M², Fatemikia, H³, Ahmadzadeh, H⁴, Movahed, A⁵, Kim, E⁶,
Mohammadpour Dounighi, N⁷, Salemy, A⁷, Seyedian, R^{8*}**

1. Department of Pathology, Bushehr University of Medical Sciences, Bushehr, Iran

2. Department of Aquatic Biotechnology, Faculty of Life Sciences and Biotechnology, Shahid Beheshti University, Tehran, Iran

3. Department of Physiology, Medical School, Shiraz University of Medical Sciences, Shiraz, Iran

4. School of Medicine, Bushehr University of Medical Sciences, Bushehr, Iran

5. Biochemistry Group, The Persian Gulf Tropical Research Center, Bushehr University of Medical Sciences, Bushehr, Iran

6. College of Veterinary Medicine, Gyeongsang National University, Jinju, South Korea

7. Department of Human Vaccine and Serum, Razi Vaccine and Serum Research Institute, Agricultural Research, Education and Extension Organization (AREEO), Karaj, Iran

8. Department of Pharmacology, Bushehr University of Medical Sciences, Bushehr, Iran

Received 7 September 2019; Accepted 26 November 2019

Corresponding Author: raminseyedian@gmail.com

Abstract

Iranian *Naja oxiana* (the Elapidae family) known as cobra snake inhabits in the northwestern part of Iran. This study aimed to evaluate the edematogenic potency of the crude venom with intraplantar injection into mice. Additionally, the inhibitory effects of three different drugs (i.e., promethazine, dexamethasone, and piroxicam) on paw edema were examined. Moreover, the gelatinase activity of this venom was assessed using the zymography method. Paw edema was induced by the intraplantar injection of different concentrations of the venom (0.5-5 µg dissolved in 50 µl of normal saline) into the mice (six in each group). It was estimated through the measurement of the increase in the paw thickness (%) with a digital caliper. The paws were pretreated and the rate of changes was measured after the venom injection. Pathological findings in the treated paws were evaluated with hematoxylin and eosin staining. Paw thickness reached its maximum amount within 5 min and resolved after 1 h. This venom had no gelatinase activity using the zymography method ruling out its role in edema. It caused non-hemorrhagic diffuse edema with the infiltration of inflammatory cells (i.e., leukocytes and lymphocytes) in the dermis. Intraperitoneal pretreatment with drugs significantly inhibited the venom-induced (1 µg/paw) edema; however, all the mice died unexpectedly a day after piroxicam injection. This in vitro and in vivo preliminary study demonstrated for the first time that *N. oxiana* venom-induced non-hemorrhagic edema in a short time. Dexamethasone (phospholipase A2 inhibitor; 1 mg/kg) and promethazine (H1 inhibitor; 5 mg/kg) decreased the venom-induced edema (P<0.001). It is suggested to carry out further studies to identify different mediators in venom-induced edema formation.

Keywords: Iranian *Naja oxiana*, Gelatinase, Paw edema, Venom, Phospholipase A2

Évaluation Expérimentale de L'œdème de la Patte Postérieure de Souris Induit par le Venin Iranien de *Naja oxiana*

Résumé: Le *Naja oxiana* iranien (la famille des *Elapidae*) connu sous le nom de serpent cobra habite dans la partie nord-ouest de l'Iran. Cette étude visait à évaluer le pouvoir œdémogène du venin brut par injection intraplantaire chez les souris. De plus, les effets inhibiteurs de trois médicaments différents (c.-à-d., prométhazine, dexaméthasone et piroxicam) sur l'œdème de la patte ont été examinés. De plus, l'activité

gélatinase de ce venin a été évaluée à l'aide de la méthode de zymographie. L'œdème de la patte a été induit par l'injection intraplantaire de différentes concentrations de venin (0.5-5 µg dissous dans 50 µl de solution saline normale) chez les souris (six dans chaque groupe). Il a été estimé par la mesure de l'augmentation de l'épaisseur de la patte (%) avec un pied à coulisse numérique. Les pattes ont été prétraitées et le taux de changement a été mesuré après l'injection de venin. Les résultats pathologiques dans les pattes traitées ont été évalués par coloration à l'hématoxyline et à l'éosine. L'épaisseur de la patte a atteint sa quantité maximale en 5 min et s'est résolue après 1 h. Ce venin n'avait aucune activité gélatinase en utilisant la méthode de zymographie excluant son rôle dans l'œdème. Il a provoqué un œdème diffus non hémorragique avec infiltration de cellules inflammatoires (c'est-à-dire, leucocytes et lymphocytes) dans le derme. Le prétraitement intrapéritonéal avec des médicaments a inhibé de manière significative l'œdème induit par le venin (1 µg/patte); cependant, toutes les souris sont mortes de manière inattendue un jour après l'injection de piroxicam. Cette étude préliminaire in vitro et in vivo a démontré pour la première fois que le venin de *N. oxiana* induisait un œdème non hémorragique en peu de temps. La dexaméthasone (inhibiteur de la phospholipase A2; 1 mg/kg) et la prométhazine (inhibiteur de H1; 5 mg/kg) ont diminué l'œdème provoqué par le venin ($P < 0,001$). Il est suggéré de mener des études supplémentaires pour identifier différents médiateurs dans la formation d'œdème induit par le venin.

Mots-clés: *Naja oxiana* iranien, Gélatinase, œdème de la patte, venin, phospholipase A2

Introduction

Several studies suggest that snake envenomation is a major threat to humans in the tropical and subtropical areas of the world. It is estimated that more than 5 million individuals are annually bitten by this animal; nevertheless, the number of mortalities is within the range of 20,000-125,000 due to a lack of accurate information in some countries (Warrell, 2010; Longbottom et al., 2018). Iranian *N. oxiana* (Caspian cobra) belongs to the Elapidae family and usually inhabits the Transcaspian region in the northwestern parts of Iran.

The results of a 10-year survey revealed that the number of mortalities due to snake envenomation was 67 in Iran (Dehghani et al., 2014). However, such approaches have failed to address the definite number of individuals envenomed with the *N. oxiana* in which the venom yield is more than other snakes living in Iran (Latifi, 1984). Furthermore, the lowest level of lethal dose 50% makes this venomous animal more deadly than other cobras (Akbari et al., 2010). The evidence suggests that snakebites cause many regional (i.e., edema, erythema, and ecchymosis) and general complications, such as cardiac arrest, respiratory paralysis, neurotoxicity, coagulopathies, and shock (Monzavi et al., 2014). Envenomation usually causes

severe pain and edema accompanied by neurological complications, including weakness, ataxia, and peripheral nerve palsy (Kularatne et al., 2009).

Numerous studies have been carried out on the toxicological profiles of different snakes, including the Elapidae family; nonetheless, there has been no experimental study conducted on biochemical events contributing to edema formation in *N. oxiana*. The primary purpose of the present study was to identify the dose-dependent and time-course elements in inflammation in mice paw edema as a model. In addition, the protective effects of dexamethasone, promethazine, and piroxicam on paw edema were evaluated. For the first time, the present study aimed to determine the biochemical and pathological events responsible for *N. oxiana* envenomation.

Material and Methods

Animals and Chemicals. The crude venom was obtained from adult specimens in Razi Vaccine and Serum Research Institute, Karaj, Iran. The latex coating method was used to milk the venom since the fangs of this snake do not move and are fixed in the upper jaw. It was lyophilized and stored at a temperature of -20°C. The venom solutions were prepared with physiological saline at the moment of use, and the protein content was measured according to the method of Bradford

(Bradford, 1976). Dexamethasone, promethazine, and piroxicam were purchased from Santa Cruz Biotechnology Incorporation (Shanghai, China). Other reagents were analytical grades from commercial sources.

SDS-PAGE and Proteolytic Activities. A sample of *N. oxiana* venom was heated at a temperature of 95°C for 5 min and cooled on ice. Electrophoresis was performed using sodium dodecyl sulfate-polyacrylamide gel electrophoresis (SDS-PAGE) with 12.5% acrylamide by the method of Laemmli (1970). The gels were stained for 1 h by Coomassie Blue R-250 (C.I. 42660, Sigma-Aldrich, USA) and silver nitrate for the detection of protein bands. Protein quantitation was performed using a prestained protein ladder (CSL-BBL; Cleaver Co., UK) within the range of 11-245 kDa. In order to evaluate the gelatinolytic properties of the venom, SDS-PAGE was copolymerized with 0.1% gelatin as a substrate in the 12.5% gel. Different concentrations of the venom were prepared using Tris-Glycine sample buffer (2X, Catalog number LC2673, USA) and remained at room temperature for 5 min. Electrophoresis was performed at cold temperature, and the gels were washed in the incubation buffer containing Triton X-100 for 1 h in order to remove SDS. They were incubated at reaction buffer (Triton X-100 1%, Tris HCl 50 mM, pH 7.5, and 5 mM CaCl₂ dissolved in 250 ml of distilled water) at a temperature of 37°C for 16 h. They were stained with 0.125% Coomassie Blue G-250 for 1 h and destained in methanol (400 ml) and acetic acid (100 ml) dissolved in 1 L. The clear zone of the gel showed the gelatinolytic capacities of *N. oxiana* venom.

Experimental Protocol. Venom in different doses (range: 0.5-5 µg) dissolved in normal saline (50 µl) was subcutaneously injected into the subplantar region in the right hind paw among different groups of mice (six in each group). The contralateral paws received the same amount of normal saline as a negative control. Paw thickness was measured at different times (i.e., 5, 10, 15, 30, and 60 min) after venom

injection with the aid of a digital caliper (Guanglu Co., China). The edema was measured as the percentage of the difference in paw thickness between the right hind paw and contralateral paws. More than 1 µg/paw of venom was not used in further experiments since it was lethal.

Effects of Drugs on Edema. This study was performed according to previous articles with minor modifications (de Faria et al., 2001; Lopes et al., 2017). Groups of mice were intraperitoneally (IP) pretreated with dexamethasone (phospholipase A2 inhibitor; Santa Cruz Biotechnology Incorporation; 1 mg/kg) and piroxicam (cyclooxygenase inhibitor; Santa Cruz Biotechnology Incorporation; 1 mg/kg) 30 min before venom injection (1 µg/paw). In the case of the promethazine (H1 inhibitor; Santa Cruz Biotechnology Incorporation; 5 mg/kg), it was IP injected 15 min before venom instillation. Paw thickness was measured and analyzed within 1 h after the venom injection in different time intervals.

Pathological Examination. The animals' right paws were cut off at the tibiotarsal points in this experiment. They were immediately kept in 10% formaldehyde solution for hematoxylin and eosin staining in order to evaluate subplantar edema, leukocyte infiltration, and hemorrhagic areas with light microscopy (Olympus CX22, USA). The processed sections (with a thickness of 5 µm) were analyzed by a pathologist unaware of the experiment. Three specimens were examined from each mouse for the evaluation of the above-mentioned criteria. The physiological saline was injected with the same volume to the left paw and considered the control experiment.

Statistical Analysis. The test results were expressed as mean±standard deviation. In addition, the data were analyzed using analysis of variance and SPSS software (version 16) followed by the Bonferroni test. The differences were considered statistically significant at P<0.01.

Results

Electrophoretic Analysis and Gelatinase Activities. The snake venom was analyzed using the SDS-PAGE

(12.5%) method with a constant voltage (100 Mv) and stained with Coomassie Blue and silver nitrate. In this case, seven different protein bands were revealed within the range of 11-120 kDa (Figure 1A). There were two major bands located below 17 kDa as well as four minor bands with approximate weights of 23, 56, 73, and 120 kDa. The protein bands were revealed again after silver nitrate staining (Figure 1B). As shown in Figure 2, this venom had no gelatinolytic activities (20 μ g); however, there was a clear band within the range of 40-60 kDa with increasing doses up to 200 μ g.

Increase in Paw Thickness (%). During the current experiment, there was non-hemorrhagic edema after venom injection into the mouse paw. Moreover, Figure 3A illustrates the dose-response curve of the paw thickness with different amounts of *N. oxiana* venom. One μ g/paw of the venom caused a significant increase ($P < 0.01$) in paw edema, compared to the control. The injection of the escalating doses of the venom caused time- and dose-dependent increases in the paw thickness without obvious signs of hemorrhage. There was mortality in amounts more than 1 μ g/paw within

24 h after the intraplantar injection. Paw thickness reached its maximum amount within 5 min, compared to that of the control (Figure 3B).

Effects of Drugs on Venom-Induced Edema.

According to Figure 4, promethazine (5 mg/kg, IP, 15 min before venom injection), dexamethasone (1 mg/kg, IP, 30 min before venom injection), and piroxicam (1 mg/kg, IP, 30 min before venom injection) had significant inhibitory effects on the paw thickness ($P < 0.01$). Unexpectedly, all the animals expired following the piroxicam pretreatment after 1 day.

Histopathological Analysis. The sections from mice treated with *N. oxiana* venom (1 μ g/paw; intraplantarly) showed marked edema with moderate infiltration of the inflammatory cells, including neutrophils and lymphocytes. Furthermore, vascular congestion was observed in the dermal area. There was no evidence of hemorrhage and/or red blood cell extravasation (Figure 5A). In addition, there were no signs of pathological changes, such as edema, leukocyte infiltration, and vascular congestion, in the control-treated animals (Figure 5B).

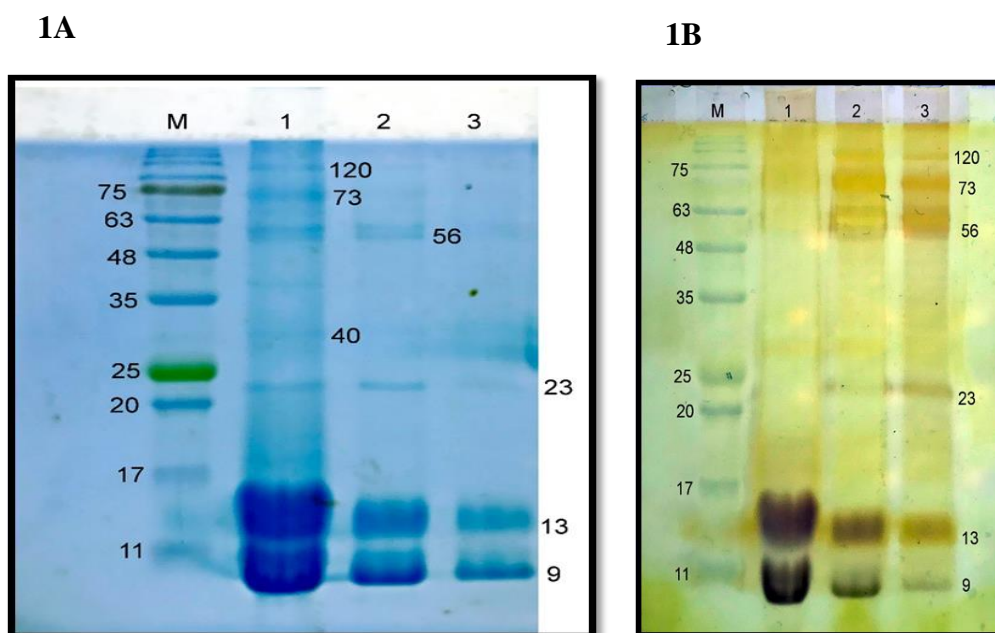


Figure 1. Protein components of *N. oxiana* venom separated by sodium dodecyl sulfate-polyacrylamide gel electrophoresis (12.5%) and stained with Coomassie Blue (lane 1:20, lane 2:10, and lane 3:5 μ g) and silver nitrate (figures 1A and 1B); numbers indicating the molecular weight of size marker (CSL-BBL prestained protein ladder)

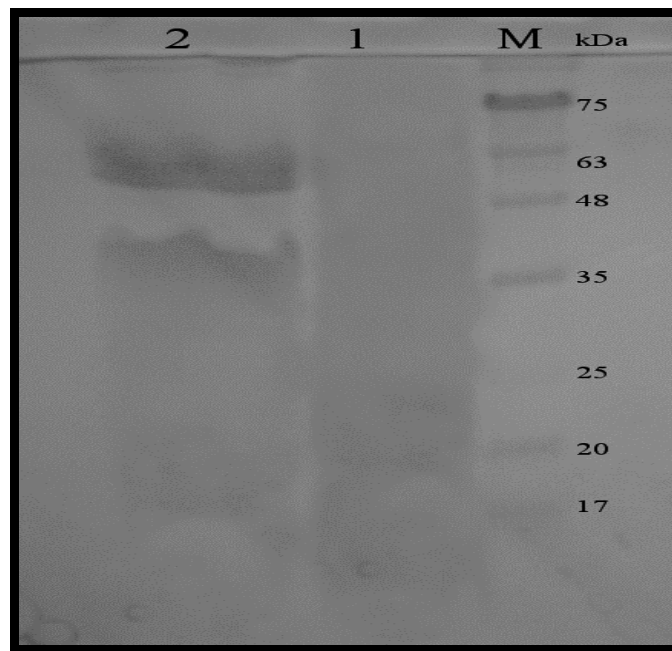
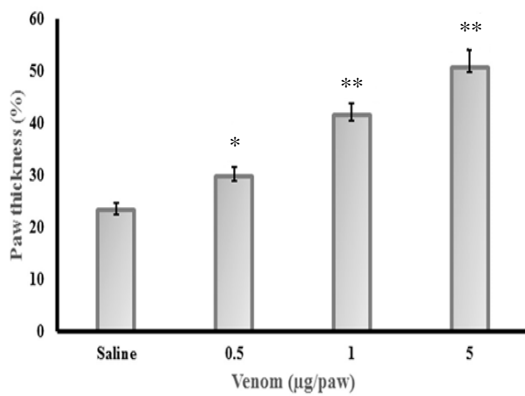
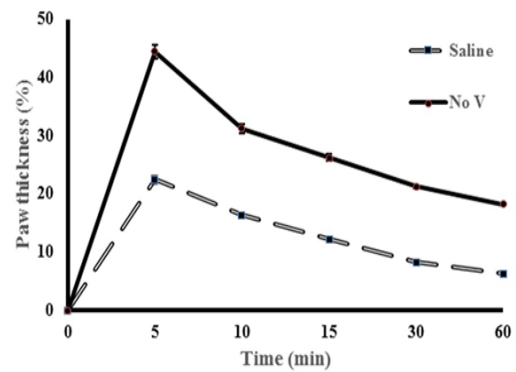


Figure 2. Gelatinase activities of *N. oxiana* venom using zymography method; *N. oxiana* venom (lane 1:20 µg and lane 2:200 µg) run on 12.5% sodium dodecyl sulfate-polyacrylamide gel electrophoresis containing substrates as previously mentioned; clear zone illustrating gelatinase activity; numbers on the right indicating molecular weight



3A



3B

Figure 3A. Intensity of paw thickness in different doses of the venom (range: 0.5-5 µg) at 5 min; control group receiving saline with the same volume (50 µl); each point representing the mean±standard deviation of 6 mice; *P<0.01 and **P<0.001, compared to those reported for the control

Figure 3B. Time course of paw thickness in mouse after intraplantar injection of saline (■) or *N. oxiana* venom (1 µg; ●)

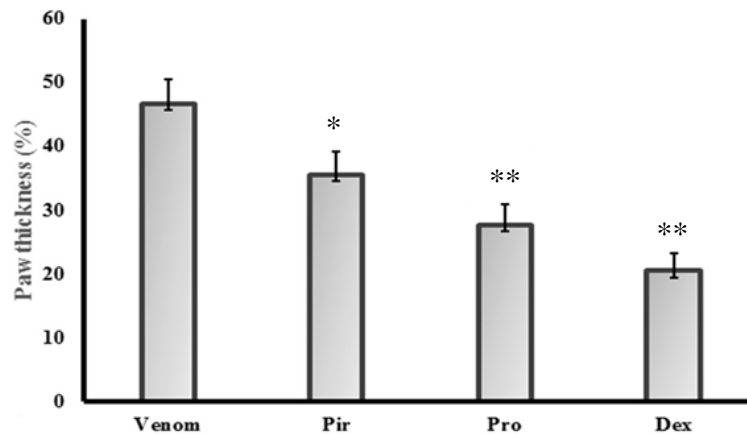
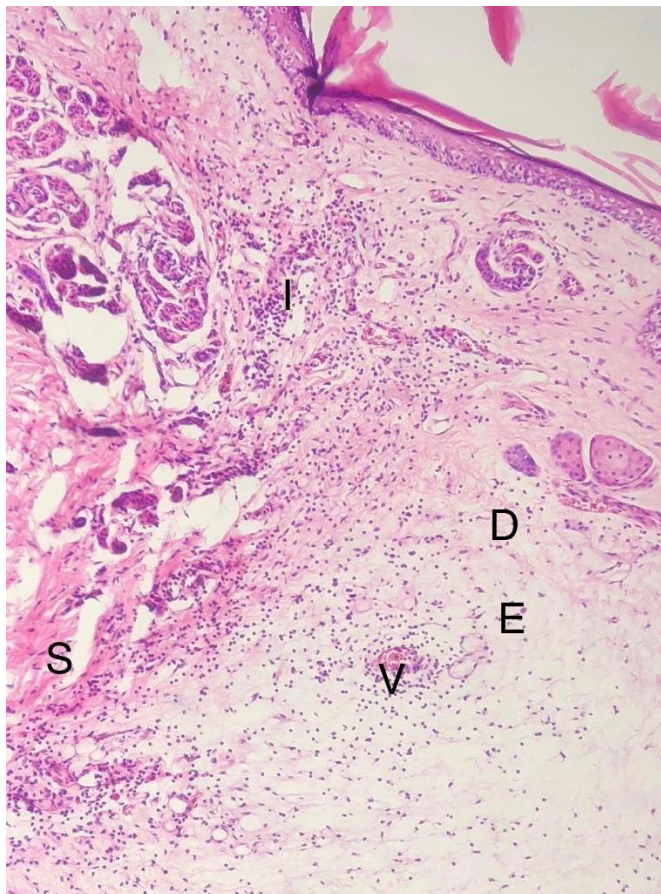


Figure 4. Inhibitory effects of piroxicam (1 mg/kg; intraperitoneally), promethazine (5 mg/kg; intraperitoneally), and dexamethasone (1 mg/kg; intraperitoneally) on venom-induced paw thickness determined 5 min after venom injection (1 μ g/paw); each column representing the mean \pm standard deviation of 6 mice; * P <0.01 and ** P <0.001, compared to those reported for the control

5A



5B

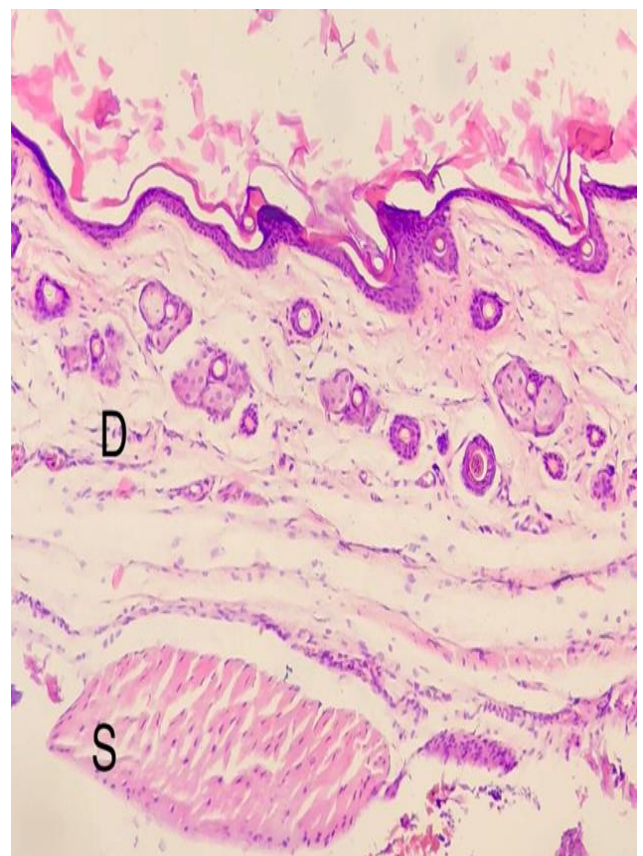


Figure 5. Histopathological appearance of mouse food pad 5 min after intraplantar injection of physiological saline (7B; 50 μ l) as a control and *N. oxiana* venom (7A; 1 μ g/paw); in 7B, epidermis, dermis, and subdermis having a normal appearance; in 7A, extensive thickening of subdermis due to edema despite scattered infiltration of inflammatory cells (i.e., leukocytes and lymphocytes) in the loosened tissue; hemorrhagic area due to extravascular red blood cells; D: dermis; E: edema; V: vascular; S: subdermis

Discussion

Snake venoms are composed of different substances and enzymes, such as serine proteases, metalloproteinases (SVMP), phospholipases, and oxidases, which all together induce different kinds of clinical manifestations following envenomation (Burin et al., 2018). In reviewing the literature, several reports have shown that cobras (the Elapidae family) are distinguished by their neurotoxins causing different kinds of disorders, such as ptosis, respiratory paralysis, and drooling, in comparison to other snakes (Tan, 1983). In addition, cutaneous necrosis, local inflammation, and edema are induced, especially in the lower extremities due to their cytotoxins (Feofanov et al., 2004).

To date, no studies have been carried out on the role of *N. oxiana* venom in edema formation. The present study evaluated pathological malformations (i.e., edema, hemorrhage, and infiltration of inflammatory cells) in addition to the attenuated effects of the three different drugs (i.e., dexamethasone, promethazine, and piroxicam) on paw thickness. The electrophoretic profiles of the crude venom showed at least two major bands below 17 kDa, explaining its probable neurotoxic properties (Akbari et al., 2010). The presence of four minor bands (i.e., 23, 56, 73, and 120 kDa) in the present study (figures 1A and 1B) may stem from intraspecific variations (Abdel-Rahman et al., 2009).

The gelatinase activity of this venom was assessed using the zymography method due to its possible involvement in edema. As depicted in Figure 2, this capacity was very low, compared to that of other snakes, ruling out its responsibilities in this process (Bee et al., 2001). The results of the current study revealed that the subplantar injection of the venom in mice caused paw edema which reduced after 1 h following envenomation (Figure 3). Furthermore, edema was accompanied by the abundant presence of the inflammatory cells, such as leukocytes and lymphocytes; nonetheless, there was no sign of hemorrhage (Figure 5). This pathological profile was similar to a previous experiment on *Naja haje Arabica*

snake venom (Al-Asmari, 2005). In addition, the edematogenic potency of this venom in mice was more than that reported in a previous experiment carried out on *Bothrops lanceolatus* venom (1 µg/paw versus 12.5 µg/paw) (de Faria et al., 2001).

Previous studies have demonstrated the essential and integral role of the snake venom SVMP in hemorrhagic phenomenon after envenomation with viperid snake bites (Kularatne et al., 2009; Escalante et al., 2011). However, *N. oxiana* (Elapidae) had no gelatinase activity similar to another experiment performed on *Naja haje Arabica* (Al-Asmari and Abdo, 2006). Secretory phospholipase A2 is present in different snake venoms, including *Vipera lebetina*, *Vipera berus*, and *Naja oxiana* (Samel et al., 2013). The rapid onset of paw thickness (5 min) in this study and its decrease after 1 h showed the importance of the mediators, such as phospholipase A2, histamine, and serotonin, in this phenomenon (Cirino et al., 1989; de Faria et al., 2001).

Additionally, the roles of the arachidonic acid metabolites and corticosteroids were considered in the present study. Piroxicam as a cyclooxygenase inhibitor significantly decreased the paw thickness (Figure 4), thereby implying that arachidonic acid metabolites via the cyclooxygenase pathway had a detrimental role in this process similar to previous experiments (Trebien and Calixto, 1989). Unexpectedly, in this experimental study, all the animals died 1 day after this intervention. It is required to carry out further experiments in order to determine the exact causes of mortality. Both promethazine as a histamine receptor antagonist and dexamethasone as a corticosteroid agent inhibited paw thickness more than piroxicam after the intraplantar venom injection (Figure 4). Therefore, it is evident that different kinds of receptors are involved in this process (Cirino et al., 1989; Trebien and Calixto, 1989; Al-Asmari, 2003).

Overall, the obtained findings of the present study indicated that *N. oxiana* venom-induced non-hemorrhagic paw edema following intraplantar injection and reached its maximum amount 5 min following envenomation. This observational study

introduced promethazine and dexamethasone as effective drugs to counteract the edematogenic effect; however, there are still numerous unanswered questions about other responsible drugs and role of the polyvalent antivenom in this process.

Authors' Contribution

Study concept and design: E. K., A. M. and R. S.

Acquisition of data: A. E., M. K., H. F. and A. H.

Analysis and interpretation of data: A. S. and N. M. D.

Drafting of the manuscript: E. K. and R. S.

Critical revision of the manuscript for important intellectual content: E. K. and R. S.

Statistical analysis: R. S.

Ethics

This animal study was conducted by the local research ethics committee of the Bushehr University of Medical Sciences.

Conflict of Interest

The authors declare that there is no conflict of interest.

Grant Support

This study was funded by the Bushehr University of Medical Sciences (IR.BPUMS.REC.1398.043).

Acknowledgment

The authors express their gratitude to Bushehr University of Medical Sciences for providing facilities.

References

- Abdel-Rahman, M.A., Omran, M.A., Abdel-Nabi, I.M., Ueda, H., McVean, A., 2009. Intraspecific variation in the Egyptian scorpion *Scorpio maurus palmatus* venom collected from different biotopes. *Toxicon* 53, 349-359.
- Akbari, A., Rabiei, H., Hedayat, A., Mohammadpour, N., Zolfagharian, H., Teimorzadeh, S.J.a.o.r.i., 2010. Production of effective antivenin to treat cobra snake (*Naja naja oxiana*) envenoming. *Arch Razi Inst* 65 (1), 33-37.
- Al-Asmari, A., 2003. Pharmacological Characterization of the Rat's Paw Oedema Induced by *Echis coloratus* Venom. *J Biol Sci* 3, 309-319.
- Al-Asmari, A.K., 2005. Pharmacological characterization of rat paw edema induced by *Naja haje arabica* venom. *J Venom Anim Toxins Incl Trop Dis* 11, 51-67.
- Al-Asmari, A.K., Abdo, N.M., 2006. Pharmacological characterization of rat paw edema induced by *Cerastes gasperettii* (cerastes) venom. *J Venom Anim Toxins Incl Trop Dis* 12, 400-417.
- Bee, A., Theakston, R.D.G., Harrison, R.A., Carter, S.D., 2001. Novel in vitro assays for assessing the haemorrhagic activity of snake venoms and for demonstration of venom metalloproteinase inhibitors. *Toxicon* 39, 1429-1434.
- Bradford, M.M., 1976. A rapid and sensitive method for the quantitation of microgram quantities of protein utilizing the principle of protein-dye binding. *Anal Biochem* 72, 248-254.
- Burin, S.M., Menaldo, D.L., Sampaio, S.V., Frantz, F.G., Castro, F.A., 2018. An overview of the immune modulating effects of enzymatic toxins from snake venoms. *Int J Biol Macromol* 109, 664-671.
- Cirino, G., Peers, S.H., Wallace, J.L., Flower, R.J., 1989. A study of phospholipase A2-induced oedema in rat paw. *Eur J Pharmacol* 166, 505-510.
- de Faria, L., Antunes, E., Bon, C., Lobo de Araújo, A., 2001. Pharmacological characterization of the rat paw edema induced by *Bothrops lanceolatus* (Fer de lance) venom. *Toxicon* 39, 825-830.
- Dehghani, R., Fathi, B., Shahi, M.P., Jazayeri, M., 2014. Ten years of snakebites in Iran. *Toxicon* 9, 298-291.
- Escalante, T., Rucavado, A., Fox, J.W., Gutierrez, J.M., 2011. Key events in microvascular damage induced by snake venom hemorrhagic metalloproteinases. *J Proteomics* 74, 1781-1794.
- Feofanov, A.V., Sharonov, G.V., Dubinnyi, M.A., Astapova, M.V., Kudelina, I.A., Dubovskii, P.V., et al., 2004. Comparative study of structure and activity of cytotoxins from venom of the cobras *Naja oxiana*, *Naja kaouthia*, and *Naja haje*. *Biochemistry (Mosc)* 69, 1148-1157.
- Kularatne, S.A., Budagoda, B.D., Gawarammana, I.B., Kularatne, W.K., 2009. Epidemiology, clinical profile and management issues of cobra (*Naja naja*) bites in Sri Lanka: first authenticated case series. *Trans R Soc Trop Med Hyg* 103, 924-930.
- Laemmli, U.K., 1970. Cleavage of structural proteins during the assembly of the head of bacteriophage T4. *Nature* 227,

- 680-685.
- Latifi, M., 1984. Variation in yield and lethality of venoms from Iranian snakes. *Toxicon* 22, 373-380.
- Longbottom, J., Shearer, F.M., Devine, M., Alcoba, G., Chappuis, F., Weiss, D.J., *et al.*, 2018. Vulnerability to snakebite envenoming: a global mapping of hotspots. *The Lancet* 392, 673-684.
- Lopes, P.H., Rocha, M.M.T., Kuniyoshi, A.K., Portaro, F.C.V., Goncalves, L.R.C., 2017. Edema and Nociception Induced by *Philodryas patagoniensis* Venom in Mice: A Pharmacological Evaluation with Implications for the Accident Treatment. *J Pharmacol Exp Ther* 361, 349-354.
- Monzavi, S.M., Dadpour, B., Afshari, R., 2014. Snakebite management in Iran: Devising a protocol. *J Res Med Sci* 19, 153-163.
- Samel, M., Vija, H., Kurvet, I., Kunis-Beres, K., Trummal, K., Subbi, J., *et al.*, 2013. Interactions of PLA2-s from *Vipera lebetina*, *Vipera berus berus* and *Naja naja oxiana* venom with platelets, bacterial and cancer cells. *Toxins (Basel)* 5, 203-223.
- Tan, N.-H., 1983. Isolation and characterization of two toxins from the venom of the Malayan cobra (*Naja naja sputatrix*). *Toxicon* 21, 201-207.
- Trebien, H.A., Calixto, J.B., 1989. Pharmacological evaluation of rat paw oedema induced by *Bothrops jararaca* venom. *Agents Actions* 26, 292-300.
- Warrell, D.A., 2010. Snake bite. *The Lancet* 375, 77-88.