

## ***Eosinophilic myositis Associated with Sarcocystis in Sheep***

Ezzi, A., Gholami, M.R., Ahourai, P.

**Summary:** Three skeletal and heart muscle specimens of sheep from different parts of Iran were submitted to the pathology Department of the Razi Institute, Iran, Microscopical findings indicated sub-acute and chronic feature of eosinophilic myositis associated with sarcocystis Spp.

**Keywords:** *Myositis / sarcocystis / Sheep / Cattle / Diseases / Iran*

### **Introduction**

*Sarcosporidia* Spp. is a protozoan parasite whose life cycle includes schizogony in the muscle of herbivores (sheep and Cattle) and sporogony in the intestine of carnivores (dogs and cats Jensen, 1974).

The parasite form ellipsoid cyst in the heart and skeletal muscle of intermediate hosts (sheep and Cattle). The cyst contains many hundreds of merozoites and measures up to 1 centimeter in length. (Jensen 1974).

Myositis due to sarcosporidia spp. has been reported in sheep (Harcourt & Bradley 1973, Jensen et al 1986), Cattle (Hamilton & Mc Cance 1968, Frelief, Mayhew & Pollock 1979, Gajadhar, yates & Allen 1987) pig (Daugachies, Jacobs & Rommel 1989) and monkey (Terrell & Stookey 1972).

To the best of the authors knowledge this is the first report of

sarcosporidial myositis in Iran.

## **Materials and Methods**

The skeletal and heart muscle from sheep (Case no.67.2450 and 68.1973) and lamb (Case no.67.4116) from different parts of the country (north, west and south) were sent to the pathology Department of the Razi Institute, during December 1988-September 1989. Specimens were processed and embedded in paraffin and 6/μ sections were cut on a rotary microtom. The sections were stained by Hematoxylin and Eosin, Masson Trichrome and Periodic Acid schiff (P.A.S.)

## **Results**

### ***Gross pathology:***

Whitish or yellowish streaked muscle had been observed in the sections by the practitioner.

### ***Histopathology:***

The following lesions were observed:

#### ***Case no.67.4116.***

Skeletal muscle fibers were fragmented and granulomas which contained central necrosis with or without amorphous granules and cell debris. The granulomas were surrounded by moderate macrophages and eosinophilic infiltration plus proliferation of plasma cells and fibrous tissue.

#### ***Case no.68.1973.***

**Skeletal muscle:** The lesions included atrophic myocyte, multiple necrotic foci. The normal architectures were replaced by loose connective tissue and oedema. There was also hyaline degeneration associated with moderate eosinophilic infiltration.

#### ***Case no.67.2450:***

**Heart muscle:** The lesions consisted of fragmented muscle fibers associated

with numerous encysted sarcocysts, one of which was opened and merozoites were observed in this area, (Figure 1). Also, granulomas with central necrosis and intact sarcocyst within the purkinje nerve were found to be present.

## Discussion

Sarcocystosis has great economic importance in regard to meat producing and packing industries. In fact intestine infection occurs in human due to ingesting raw or poorly cooked beef and lamb (Gracey 1981).

The encysted organisms are common in the muscles of cattle and sheep and usually don't provoke myositis (Markus, 1979), unless severe infection of sarcocystis has occurred in immune animals (Jeffrey, Low & Uggla 1989). Jensen and others in 1986 suggested that the muscular sarcocysts have both cytotoxin and eosinophil chemotactic factor. In the early stage of granuloma, the cyst wall is ruptured, due to enhancing osmotic pressure. Later, numerous bradyzoites in addition to the above mentioned substance within the cyst are diffused into the surrounding tissue. Subsequently massive cellular infiltration mostly eosinophilic type is found to happen.

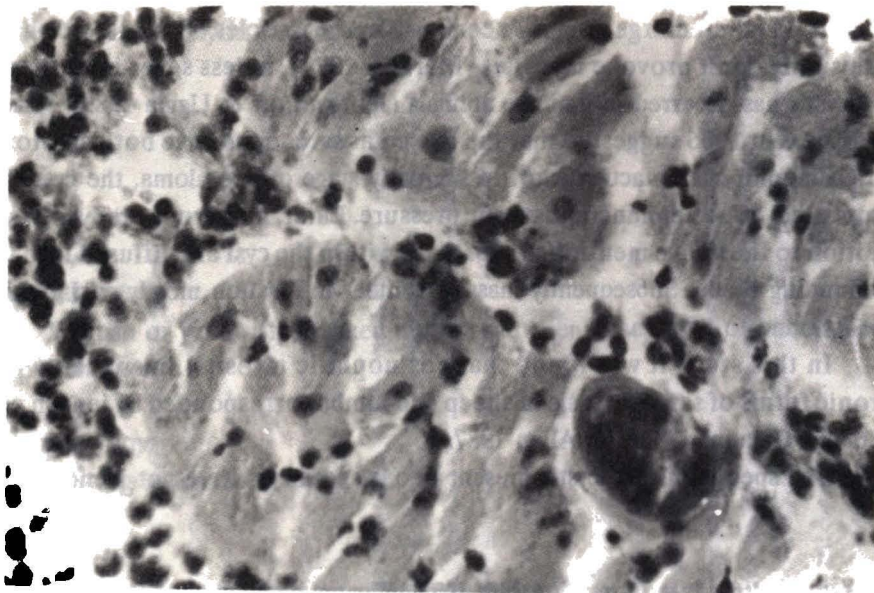
In this study it was found that eosinophilic myositis in subacute and chronic forms of sarcocystosis in sheep and lambs corresponded by Jensen et al 1986 and Gajadhar, Yates & Allen 1987.

The species of sarcocystis present in our specimens were not identified.

## References

1. Dauschies A., Jacobs M., Rommel M. (1989), *Ein Fallbericht, Berliner und Munchener Tierärztliche Wochenschrift* 102 (6) 184-187.
2. Frelier P.F., Mayhew I.G. & Pollock R. (1979), *American Journal of Veterinary Research* 40, 651-657.
3. Gajadhar A.A., Yates W.D.G. and Allen J.R. (1987), *Canadian Journal of Veterinary Research* 51:373-378.
4. Gracey J.F. (1981), *Thornton's Meat Hygiene, 7edn. Bailliere, Tindall, London.*
5. Hamilton J.M. & McCance C.B. (1968), *Veterinary Record* 83:471-472.
6. Harcourt R.A. & Bradley R. (1973). *Veterinary Record* 92:233-234.
7. Jeffrey M., Low J.C. & Uggla A. (1989), *Veterinary Record* 124, 422-426.

8. Jensen R. (1974), *diseases of sheep*, Lea & Febiger, U.S.A.
9. Jensen R., Alexander A.F., Dahlgren r.r., Jolley W.R. Marquardt W.C. Flock D.E., Bennett B.W., Cox M.F. Harris C.W., Hoffman g.A, Troutman R.S., Hoff r.L. Jones R.L., Collins J.K., Hamar D.W., Cravans R.L. (1986), *American Journal of Veterinary Research* 47, No.3, 587-597.
10. Markus M.B. (1978), *Advances in Veterinary Science and Comparative Medicine* 22, 159.
11. Terrel T.G. & Stookey J.L. (1972), *Veterinary Pathology* 9:266-271.



*Figure 1: Photomicrograph of case no.67.2450 heart muscle, showing an opened encysted sarcocyst which provoked infiltration of mononuclear and eosinophil cells.*