

SUBACUTE SCLEROSING PANENCEPHALITIS IMMUNOLOGICAL FINDINGS IN SALIVA AND SALIVARY GLANDS(*)

Irag Derakhshan, Hossain Mirchamsy and abbas Shafyi

Key Words. SSPE. Immunofluorescence. Salivary gland. Saliva

Abstract. Antimeasles antibody was detected in the saliva of 14 patients with subacute sclerosing panencephalitis. Immunofluorescent staining showed antibody in salivary gland biopsy of 7 patients.

INTRODUCTION

SSPE is prevalent among children in Iran. In 2 years, 30 cases were diagnosed at the Dariush Kabir Hospital. We found antimeasles antibodies in the saliva and salivary glands of these patients

Patients, Materials and Methods

2 ml of saliva, blood and cerebrospinal fluid (CSF) were obtained from 14 patients with subacute sclerosing panencephalitis (SSPE) in various stages of the disease (table 1). Hemagglutination inhibition (HI) test was done on the saliva of patients and controls without pretreatment of the saliva, using standard methods (7).

Salivary Gland Biopsy. Informed written consent was obtained from all parents. Under general anesthesia, a piece of submandibular gland was obtained from 7 patients. Another specimen was obtained from a child who underwent a ventriculojugular shunt for a different neurological disorder and was used as a control for immunofluorescent (IF) staining. Immediately after the biopsy, an appropriate piece was prepared for each of the following examinations:

IF Staining. A small piece of the tissue was cut and washed with cold normal saline. At least 10 consecutive frozen sections of 8-10 μm thickness were prepared and stained by a standard method (4) for indirect IF using fluorescent antihuman IgG, IgA, IgM, and IgG+IgA+IgM ('whole') from a commercial source (Behringwerke, FRG). The sections were viewed with a Zeiss fluorescent photomicroscope.

Co-Cultivation of the Salivary Glands from SSPE Patients. A piece of the tissue was put in basal medium Eagle (BME) solution and sent to the Razi Institute. Co-cultivation by fresh vero cells was done within 1 h after the operation.

* Reprinted from: Eur. Neurol. 18: 79-83 (1979)

Light and Electron Microscopy (EM). A piece of tissue was processed for hematoxylin and eosin staining. Thin sections for EM were made after sequential fixation in 2% glutaraldehyde and osmium tetroxide, dehydration with graded ethanol alcohol and embedding in plastic. The sections were stained with uranium acetate and lead citrate.

Table 1. Clinical and laboratory data on SSPE patients

| Name sex age | Duration (months) of disease | History of natural measles before diagnosis | EEG ¹ | Measles serum | HI titer ² CSF | saliva | Tissue diagnosis | Remarkable feature |
|--------------------|------------------------------------|--|------------------|-------------------------|------------------------------|---------------|----------------------|-----------------------|
| RB,M,10 | 12 | + | + | 2,048 9,192 | 48 | 24 | B | cystic astrocytoma |
| SI,M,8 | 4 | +,age 4 | + | 4,096 | 64 | 24 | B ³ | |
| JH,M,9 | 24 | +,age 2 | + | 2,048 3,072 | 96 | 128 | B & S | |
| MB,F,11 | 8 | +,age 2 | + | 1,024 4,096 | 64 | 16 | B & S | chorio- retinitis |
| AY,M,12 | 6 | - | + | 1,024 8,196 3,072 | 192 | 8 | | chorio- retinitis |
| RP,M,16 | 2 | unknown | + | 2,048 | 64 | 8 | B & A | chorio- retinitis |
| AM,F,12 | 8 | +,age 1.5 | + | 1,024 12 | 16 24 | S 24 | chorio- retinitis | |
| SA,F,14 | 4 | + | + | 2,048 | 192 | 6 12 | B ³ | |
| FJ,F,10 | 12 | + | + | 2,048 | 128 | 48 | B & S | |
| NS,F,24 | 8 | unknown | - | 2,048 | 128 | 8 | B | normal EEG |
| HK,M,12 | 18 | +,age 3 | + | 4,096 | 1,024 | 8 32 64 | S | |
| MM,M,8 | 18 | + | + | 4,096 | 64 | 8 12 | S | papilledema |
| SE,F,8 | 1 | +,age 4 | + | 2,048 | 32 | 32 | | |
| FZ,M,18 | 12 | +,age 3 | + | 4,096 | 512 | 24 | S | |

A = Autopsy; B = brain biopsy; S = salivary gland biopsy. + = History, sign, or test result positive; with history of natural measles, age in years at time of measles is given; - = History absent, sign or test result negative.

¹ Characteristic pattern.

² Reciprocal of the highest dilution.

³ Virus isolated.

Fig. 1. IgG staining, X 380. Staining of the cells lining a number of salivary ducts can be seen.

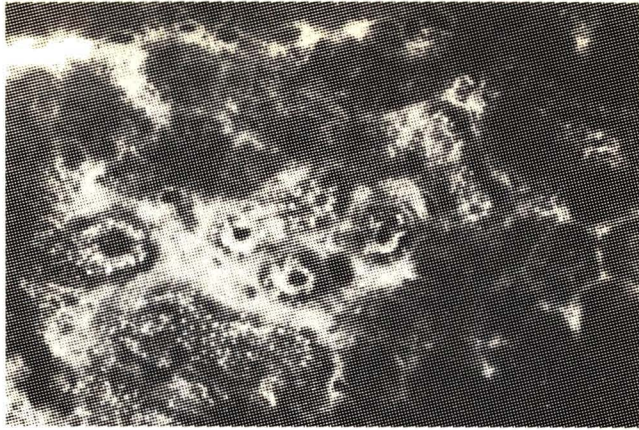


Fig. 3. IgG staining, X 130. Normal salivary gland. No fluorescent staining is seen. The salivary ducts are outlined by auto-fluorescence of the tissue.

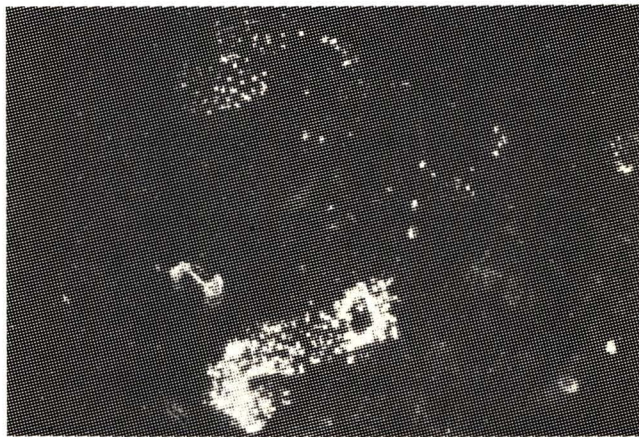


Fig. 2. IgG staining, X 380. Intense staining of the cells lining a centrally located duct is seen.



RESULTS

Measles antibody was detected in saliva of all SSPE patients at various stages of the disease (table I). HI titer in saliva of 14 control patients (adults and children) with unrelated disorders ranged from nil (12 cases) to 1:3 dilutions (2 cases). Titers below 1:4 dilution are considered nonspecific (negative) in our laboratory. HI titers in the sera of control patients were as follows: 1:32, 1:48, 1:28, 1:192, 1:768, 1:2,046 (1 case in each dilution), 1:24, 1:64, 1:96, 1:512 (2 cases in each dilution). Saliva from the 4 control patients having highest serum HI titers did not contain measles antibody.

Attempts to isolate virus by co-cultivation of the biopsy material remained negative after 10 passages.

Cells lining the salivary ducts stained for IgG (fig. 1, 2), IgA and IgM, with an intensity in that order. Judging from the regularity of the bright dots along the lumen, the cells lining the latter seemed to be the site of immunologic interaction. The exact intracellular site of the immune complex formation remained uncertain, however. Though there was some fluorescent staining within the glandular substance, the intense staining of the cells lining the ducts was not explained. There was no fluorescent staining of the salivary ducts of the acini with any of the fluorescent antibodies in the control specimen (fig. 3). Neither intracytoplasmic nor intranuclear inclusions were present in the cells forming the acini or lining the salivary ducts by light or EM.

DISCUSSION

Although the brain is the most heavily involved organ in SSPE, immunological data indicate the systemic nature of the disease (2,3,6). Antibody in salivary glands and antimeasles antibody in saliva provide more evidence. The finding of viral antibody in the salivary glands raises the possibility that viral antigen is present on the glandular cell membranes.

Nasopharyngeal and salivary secretions are among the infective sources in the transmission of viral disease. This is true in measles (9), rabies (1) and hepatitis B (5). Isolation of papova virus in the urine of patients with progressive multifocal leukoencephalopathy is another example of a viral brain disease in which the agent has been demonstrated in a distant site (8). The comparatively low titer of antibody in the saliva may suggest that the salivary antibodies leak from circulating antibodies into the saliva. However, intracellular antibodies, as shown by the indirect staining method, and the absence of antibody in the saliva of control patients with highest HI titers in their sera, argues against such a possibility.

Search for virus in the saliva of these patients, using intracerebral inoculation and co-cultivation techniques, would be useful in further delineation of the probable pathogenetic implications of the findings described in this article.

REFERENCES

- 1 Bahmanyar, M.; Fayaz, A.; Noorsalehi, S., et al.: Successful treatment of humans exposed to rabies infection. *J. Am. med. Ass.* **236**: 2751 – 2754 (1976).
- 2 Connolly, J.H.: Subacute sclerosing panencephalitis. *J. clin. Path., suppl.* **6**, pp. 73-77 (1972).
- 3 Dayan, A.D. and Stokes, M.I.: Immune complexes and visceral deposits of measles antigens in subacute sclerosing panencephalitis. *Br. med. J.* **ii**: 374-376 (1972).
- 4 Gardner, P.S. and Mc Quillin, J.: Rapid virus diagnosis, application of immunofluorescence (Butterworths, London 1974).
- 5 Heathcote, J.; Cameron, C.H., and Dane, D.S.: Hepatitis-B antigen in saliva and semen. *Lancet* **i**: 71 – 73 (1974).
- 6 Lapointe, N.; Geoffroy, G., and Mongeau, J.G.: Immune complexes in subacute sclerosing panencephalitis. *New Engl. J. Med.* **287**: 823 (1972).
- 7 Michamsy, H.; Bahrami, M.; Shafiyi, A., et al.: Isolation and characterization of a defective measles virus from brain biopsies of three patients in Iran with subacute sclerosing panencephalitis. *Intervirology* **9**:106 – 118 (1978).
- 8 Rand, K.H.; Johnson, K.P.; Rubinstein, L.J., et al.: Adenarabioside in the treatment of progressive multifocal leukoencephalopathy. *Ann. Neurol.* **1**: 458 – 462 (1977).
- 9 Riddle, J.C.: Measles (rubeola); in Wintrobe, Harrison's principles of internal medicine, 7th ed., pp. 961 – 963 (McGraw-Hill, New York 1974).