

## MYCOTIC DERMATITIS OF SHEEP IN IRAN

By :

**GH. MAGHAMI , M . BAHARSEFAT & A . R . AMJADI**

Mycotic dermatitis « lumpy wool » of sheep causes economical losses , sometimes very serious, in some parts of the world, and has drawn the attention of many investigators in countries such as South Africa ( Bekker, 1928 ; Steyn , 1931 ; Mason & Bekker , 1934 ) , Australia ( Seddon, 1929 ; Bull , 1929 ) , New Zealand ( Waters , 1932 ) , India ( Lall & Rajagopalan , 1949 ) , Britain (Nisbet & Bannatyne , 1955 ; Austwick , 1958 ; Austwick & Davies , 1958 ) , Norway ( Slagsvold , 1933 ) and other countries ( Stewart , 1972 ).

In Iran our knowledge on the subject was practically nil up to 1962 when sporadic cases of sheep dermatomycosis were observed, and it was not until 1973 that the disease turned out to be a veterinary problem.

The aim of the present communication is to describe the clinical signs, the histopathological changes, and record of the disease for the first time in this country.

### MATERIALS AND METHODS

Materials were obtained from five different infected flocks , separately located. The skin of affected areas from dead or slaughtered infected animals was taken off, preserved and fixed in 10% formol saline, processed by paraffine embedding method, for histopathological sectioning . The sections were cut in 5 microns thickness and were stained by Hematoxlin & Eosin, Gridly,s fungal and Gram,s methods.

Scabs were collected for direct microscopical examination , culture and determination of fungi. Skin lesions were thoroughly cleansed with a sponge moistened in alcohol. Scrapings were made, deeply enough , from the edge of

lesion with a sterile scalpel , and collected into a petri dish . The material was taken to the laboratory, as soon as possible , for microscopic examination and cultural study for fungus parasites.

**Direct examination:** As sheep mange in Iran is prevalent , and in many cases the dermatomycosis may appear very much like an infestation with parasitic mites, so the skins craping materials were examined both for mange mite as well as fungi.

For this purpose , a suitable quantity of skin scabs and brocken off hairs were placed in 2 drops of 20 per cent potassium hydroxide (KOH ) on a glass slide and covered with coverslip and pressed lightly. The crusty materials were mashed with clean tooth - pick before putting the coverslip . The so prepared slide was heated gently by holding a few moment, over a Bensen burner flame ,for clearing , and examined under the low power objective (10 x ) of a microscope, with reduced light. If spore like bodies within or around the hair roots or inside the hair shaft was found , the material would be examined with a higher dry objective ( 40 x ) to see the details of the spores formation .

**Culture :** Some scabs as well as hairs and wool fibres from fresh scraping , particularly, with appearence of greyish colour at the base were ground in sterile physiological saline and cultured into Sabouraud, s medium . The cultures were incubated at 20 c . for 2 months and checked at weekly intervals .

## **OUTBREAKS AND CLINICAL FEATURES**

The Table presents the collected data on the occurence of mycotic dermatitis in Iran .

Table: Incidence of mycotic dermatitis of sheep in Iran , since 1962 to 1975

Date	Lacation	Numer of animal in flock	Number of animal affected	Form of the lesions on the body
Nov.1962	Hashtguer, 65 km . West of Tehran	39	3 ewes	Dry squamous lesions on the back along lumbar region
Jan. 1973	Shiraz , 895 Km . South of Tehran	750	65 lambs	Scabby lesions on ears ,nose and all woolly parts of the body
Oct. 1974	Zanjan , 350 Km . West of Tehran	200	21 sheep	Squamous lesions on the face and thoracique region
May 1975	Shahdasht , 35 Km. West of Tehran	242	15 lambs	Dry squamous lesions on ears, nose and face
Oct. 1975	Marvdasht, 950 Km . South of Tehran	835	253 sheep and lambs	Pustular and exudative lesions on ears , nose and all woolly parts of the body including legs

As shown in the table , we observed 5 outbreaks of mycotic dermatitis of sheep in the country in which the clinical features varied in different flocks as well as in different weather conditions . In some flocks , the infection was mild with dry scabby lesions confined to ears , face and nose, and in the others , the dry squamous lesions were seen on the back along lumbar region with intermittent pruritis and partial loss of the wool .

In severe cases , mostly in lambs aged less than 6 months, the most noticeable clinical feature were pustular and exudative lesions on ears and face which spread rapidly and covered , within one month , all woolly parts of the body including the legs ( Fig . 1 & 2 ) . The lesions first were covered with scabs , and at later stage the exudate caused binding of the wool fibres into a hard mass varying in colour from pale yellow on the top to somewhat greyish at base . Some of the affected lambs died and the skin was showing multiple zones of well developed lesions with dry scabby material which had bound the wool fibres firmly together forming hard mass and crust .

In all of 5 outbreaks the field veterinarians had suspected the disease to be mange mite infestation , and despite the use of gamma BHC dip , they had failed to cure the disease .

**Microscopical examination :** Skin scraping samples on the slide , after being treated with KOH, were examined directly under microscope. They were negative for mange mites , but inside some hairs and wool fibres numerous fungus spores very similar to **Dermatophilus dermatonomus** , appearing as highly refractile , spherical and round bodies arranged in chain position , in maiz or mosaic shape were observed .

We failed to isolate the organism by the culture of samples in the specific medium .

**Pathological findings :** There was extensive purulent exudate beneath the epidermis which separated it from dermis . While a new epidermis was forming under exudate, the old epidermis was invaded by the fungus and the organisms were seen as branching filaments. On the surface, the dermis was covered by thick scabs which consisted of alternate of cornified epidermis and exudate. The organism could be seen in sections stained by Heamatoxylin & Eosin , and it would be much clear when stained with Gram,s technique ( Fig . 3 & 4 ) .

## CONCLUSION AND DISCUSSION

Bull ( 1929 ) first isolated the causative organism of lumpy wool in sheep and called it **Actinomyces dermatonomus**. Austwick ( 1958 ) considered the only valid name ,for this causative agent ,to be **Dermatophilus dermatonomus** . Micros-bopical findings of dermatophilus filaments in the scabs as well as typical fungal spores in the affected and wool fibres, in the cases reported here , were very

similar to **Dermatophilus dermatonomus** , and taking the clinical findings into consideration as well, we could conclude that the dermatitis occurring amongst 5 different flocks of sheep in Iran, was most probably mycotic dermatitis due to

#### **D . dermatonomus .**

It is probable that the importation of sheep, on a large scale , from countries wher mycotic dermatitis is prevalent , might have a factor contributing to the increase in the number of cases that observed since 1973.

As mycotic dermatitis in sheep, resembles in many respect to other dermatitis such as : mite infestation, eczema , vitamin deficiencies etc . , therefore an accurate diagnosis of the disease for the control is very important.

We observed that the seasonal peak of the activity of the disease in Iran was associated with wet weather. Dipping animals with gamma BHC or other insecticide for control of ectoparasites, perhabe was favorable to othe spread and transmission of the disease, whereas in warm dry months spontaneous recovery of lightly infected animals ocured and the incidence of the desease decreased.

Dipping sheep in copper sulphate solution ( 1 in 500 ), recommended by Bull ( 1929 ) controlled further spread, but failed to cure the affected animals.

#### **ABSTRACT**

The occurence of mycotic dermatitis « lumpy wool» of sheep due to **Dermatophilus dermatonomus** is recorded for the first time from ditfferent parts of Iran. The clinical features of light and server infections, the pathological changes and direct microscopical findings are discussed .

#### **REFERENCES**

- Austwick , P . K . C . (1958) . Vet . Rev . Annot . , **4**, 33 - 48 .
- Austwick , P . K . C . & Davies , E . T . (1958). Vet. Rec . , **70** , 1081 - 1086.
- Bekker , J . G . (1928). J . S . Afric . Vet . Med . Ass . , **1** , 51-57 .
- Bull , I . B . (1929) . Aust . J . exp . Biol . Med . Sci . ,**6**, 301-314 .
- Lall , H . K . & Rajagopalan , V . R . (1949) . Indian J . Vet . Sci . , **19**, 1-4 .
- Mason , J . H . & Bekker , J . G . (1934) . Onderstepoort J . Vet . Sci . Animal Ind . , **3**, 211-216 .
- Nisbet , D . I . & Bannatyne , C . C . A . (1955) . Vet . Rec . , **67**, 713-715 .
- Seddon , H . R . (1929) . Vet . Res . Rep . N . S . W . 1927-8 , **5** , 10-18.
- Slagsvold , L . (1933). Norsk Vet . - tisskr . **45**, 3-1-373. Abst . Vet . Bull . , **4** ,504 .
- Steyn , D . G . (1931) . 17th Rept . Director Vet . Serv . Animal Ind . , Union S . Africa , 205-213 .
- Stewwart , G . H . (1972) . Vet , Rec . , **91** , 537-544 and 555-561.
- Waters , R . (1932) . New zealand J . Sci . Technol . , **13**, 309-310 .

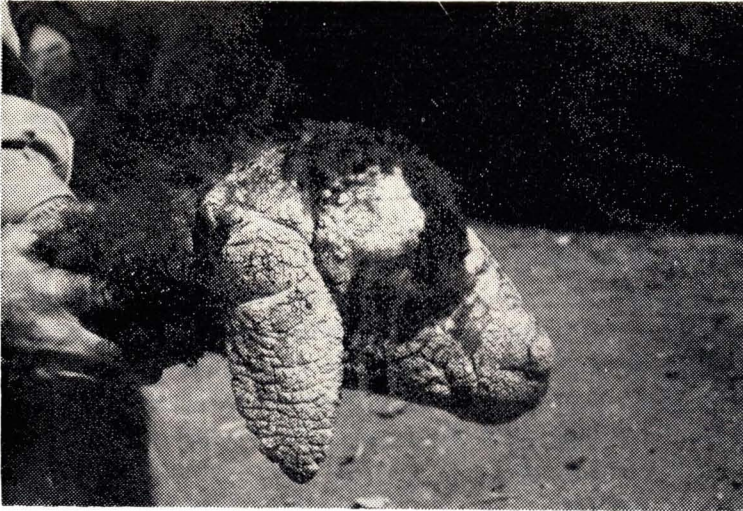

Fig. 1. Lamb showing lesions of severe dermatitis due to *D. dermatonomus* on ears and face



Fig. 2. Lesions of dermatitis due to *D. dermatonomus* on the leg of lamb.

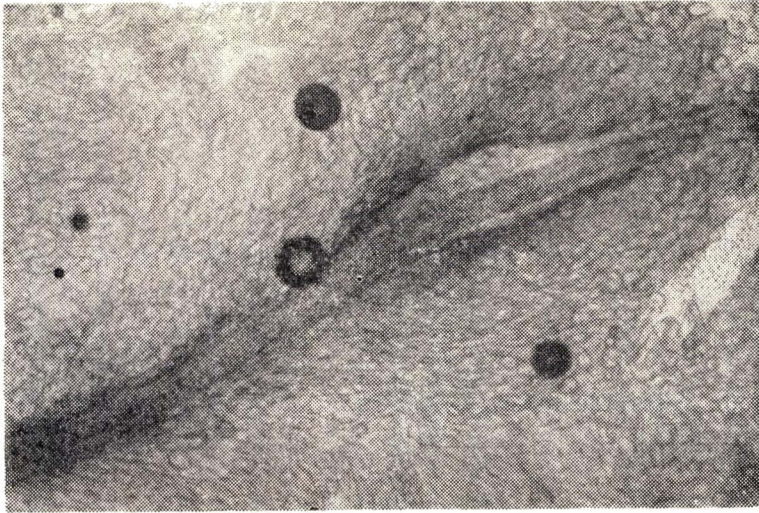


Fig. 3. Potassium hydroxide preparation of a hair showing spores of *D. dermatonomus* (low magnification)

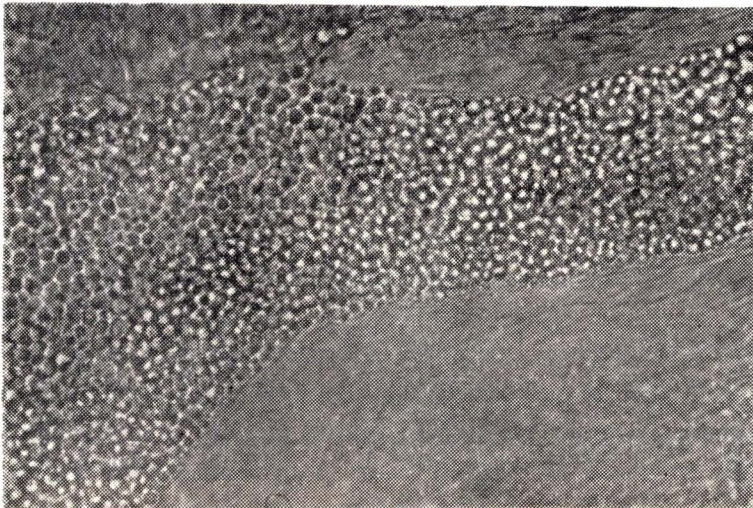


Fig. 4. Potassium hydroxide preparation of a hair showing spores of *D. dermatonomus* (high magnification)