

THE FIRST REPORT OF *CLOSTRIDIUM OEDEMATIENS* INFECTION IN SHEEP IN IRAN BY THE USE OF FLUORESCENT LABELLED ANTIBODY (*)

M. Ardehali and H. Darakhshan

Black disease or infectious necrotic hepatitis is an acute toxemia of sheep, cattle and occasionally pigs caused by the toxin of *Clostridium oedematiens* type B. The distribution of the disease is world-wide and is always fatal in sheep, cattle and pigs.

This paper attempts to describe the occurrence of black disease in sheep in Iran with an emphasis on the clinical, pathological pictures and the diagnosis of the disease by fluorescent antibody technique.

Symptoms

Black disease is one of the most acute and fatal diseases in sheep in some parts of Iran. Sporadic outbreaks of disease have been observed in areas where animals are exposed to liver fluke infestation.

The disease occurs in autumn and winter, affects sheep of 2 to 4 years of age in a good bodily condition. The animals show little clinical symptoms. The period of illness is very short and associated with rapid respiration and disinclination to move. Death occurs within 1 to 2 hours.

Post-mortem changes

In post-mortem examination, the subcutaneous blood vessels were found to be very engorged. A varying amount of straw-coloured fluid in the pleural

(*) Reprinted from Indian Vet. J. 52, 1975; 600-601

and abdominal cavities was observed. Gelatinous fluid in the pericardial sac and haemorrhages on the epicardium and endocardium were observed. The visceral wall of the abomasum was oedematous with haemorrhages. Characteristic changes were found in the liver. It was dark brown in colour, consisted of one or more necrotic areas of 10–40 mm in diameter and greyish yellow surrounded by a well-defined zone of congestion. This lesion was often under capsule of the liver and found only by cutting the liver. In most cases the liver showed the presence of various numbers of immature fluke infestation.

Laboratory findings

Isolation of the causative agent:

Immediately after death materials were taken from freshly cut area of the liver, just between the necrotic zone and the haemorrhagic zone and aseptically streaked on a freshly solidified medium (Moore 1968), and incubated anaerobically for 48 hours at 37°C. The typical *Cl. oedematiens* colonies were picked up and transferred to a liver medium and kept as freeze dried ampoules for further study. Up to the present time ten strains of *Cl. oedematiens* type B have been isolated at Razi Institute from fresh carcasses and specimens received from different parts of the country for diagnosis of sudden death in sheep.

Fluorescent Antibody Staining Technique:

The fluorescent antibody staining technique was used for rapid diagnosis of black disease in sheep (Batty and Walker 1964). Smears were prepared directly from the necrotic areas of the suspected liver lesions stained by specific *Cl. oedematiens*, *Cl. septicum* and *Cl. chauvoei* fluorescent antibodies (*) and observed under fluorescent microscope. The organisms which were stained by *Cl. oedematiens* fluorescent antibody fluoresced brightly and were identified as *Cl. oedematiens* (Fig1). No fluorescence was observed with *Cl. septicum* and *Cl. chauvoei* fluorescent labelled antibodies. After isolation of organisms, smears were prepared and stained with specific fluorescent antibody and was found positive for *Cl. oedematiens* under the fluorescent microscope.

Discussion

Many cases of suspected black disease in sheep have been received for diagnosis at Razi Institute, but the causative agent was first isolated in 1969 from the liver lesion of a sheep belonging to a herd of about 500 sheep. Up to now, 42 specimens were received for diagnosis of black disease from provinces of Iran like Isfahan, East-Azarbaijan, West-Azarbaijan, Hamadan, Tehran Kerman and Lorestan and out of them, 27 were positive for black disease. The

* Fluorescent Anti - Clostridial Globulins, Wellcome, Beckenham, Kent, England.

above mentioned provinces are highly infested with *Fasciola hepatica* (Elizian 1974). The incidence of death rate is high in autumn and winter and the flukes may cause a favourable environment for the black diseases in sheep in Iran.

Summary

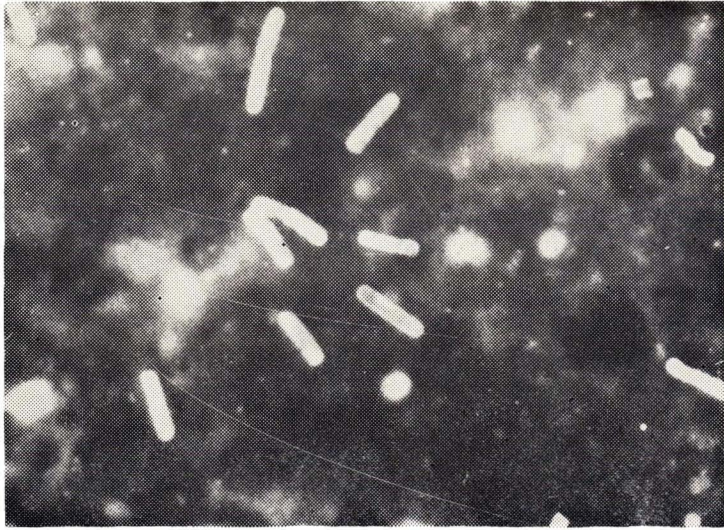
The occurrence and diagnosis of *Clostridium oedematiens* infection in sheep in Iran, based on clinical post-mortem findings, isolation and rapid fluorescent antibody technique, are described. Correlation with *Fasciola infestaion* with the black disease in same provinces of Iran is also described.

Acknowledgment

The authors are grateful to Mr. Walker, Wellcome Research Laboratories for typing the *Clostridium oedematiens* and to Mr. Dowran for his technical assistance in this work.

REFERENCES

- | | |
|-----------------------------------|--|
| Batty, I. and Walker, P.D. (1964) | ... <i>J. Path, Bact.</i> 88: 327. |
| Elizian, M. (1974) | ... Personal communication. |
| Moore, W.B. (1968) | ... <i>J. gen. Microbiol.</i> 53: 415. |



A typical cases of black disease in sheep. Smear from liver lesion stained with a fluorescent labelled *Cl. oedematiens antisertum* (X 1000).