

## THE FIRST REPORT OF LUMBAR PARALYSIS IN SHEEP DUE TO NEMATODE LARVAE INFESTATION IN IRAN (\*)

By

M. BAHARSEFAT, A. R. AMJADI, B. YAMINI and P. AHOURAI

**ABSTRACT**-An outbreak of lumbar paralysis in sheep caused by infestation with parasite larvae occurred in sheep in northern Iran. The causative parasite was diagnosed as nematode larvae. Diethylcarbamazine was effective in treatment and control of the disease.

PARALYTIC disorder in sheep, goats and horses due to invasion of the central nervous system by immature nematodes (*Setaria* spp.) was first reported by Japanese workers (9,10), and later in Ceylon (3), in India (4) and in Israel (7). Kennedy *et al.* (6) described a paralytic disease in sheep in the U.S. caused by the nematode now properly called *Odocoileostrongylus tenuis* (1).

In Iran an enzootic neuroparalysis of goats was reported (2), but the clinical and pathological data were inadequate to clarify the cause.

The present report describes the first occurrence of lumbar paralysis in sheep due to helminth infestation in Iran.

### HISTORY

An outbreak of lumbar paralysis occurred in sheep of a newly established farm, Sephid-Rood Husbandry Farm, in August, 1971. The disease started in a flock of 500 sheep kept in an area near the Caspian Sea for grazing where it had previously been jungle. The sheep were of a native breed and had been brought from Sangsar, 200 Km east of the area, two months earlier. About 7 per cent of the animals were affected and showed motor weakness, bilateral or unilateral incoordination, sometimes leading to posterior paralysis. Some sheep fell down on one side and were unable to rise. A very few of them showed

---

(\*) Reprinted from The Cornell Veterinarian, Vol. 63: No. 1. (1973)

severe incoordination and complete paralysis of the legs and some tried desperately to rise on their front legs (Fig. 1).



*Fig. 1.* Lumbar paralysis in a sheep.

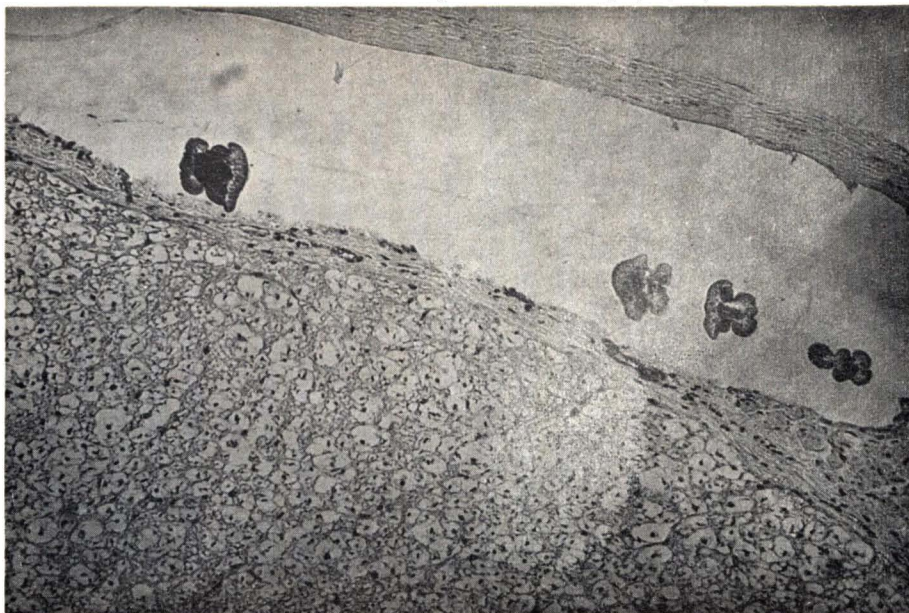
Two sheep which died after being paralysed for one week were delivered to the Pathology Department of Razi State Institute for diagnosis.

### NECROPSY

No macroscopic changes were observed in the internal organs or nervous system, except that the spinal fluid was increased about two times.

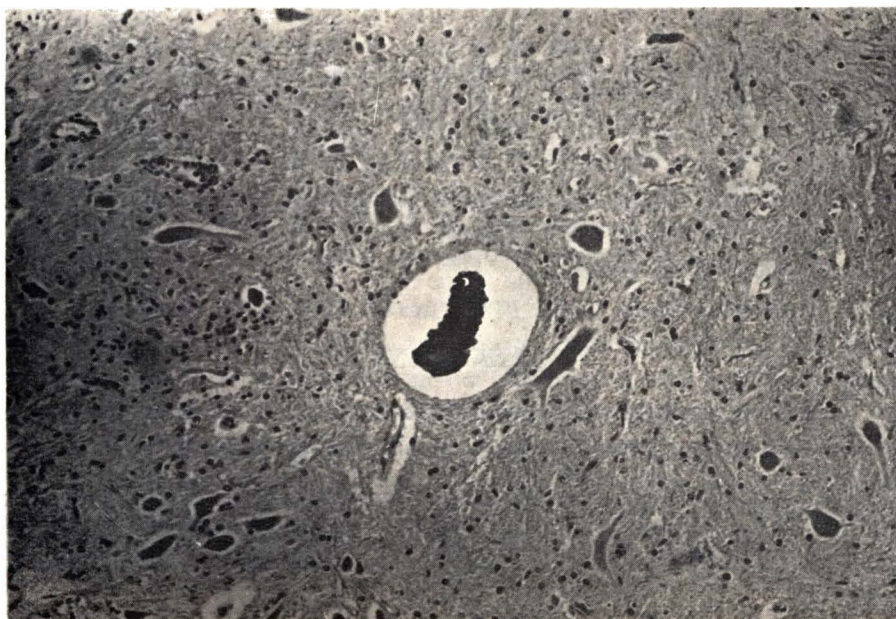
The spinal cords were cut in slices 5 mm thick. Paraffin blocks were prepared and many histological slides were cut from each block and stained with hematoxylin and eosin (H and E). The sections were examined for parasite infestation. Four sections of one or more parasites measuring from 80 to 100 microns in diameter were present between the pia mater and the arachnoidea

with cellular infiltration of the meninges in one sheep (Fig. 2). A remnant of a



*Fig. 2.* Four larvae in the subarachnoid space of spinal cord. H and E. Original magnification  $\times 100$ ; reduced to  $\frac{3}{4}$ .

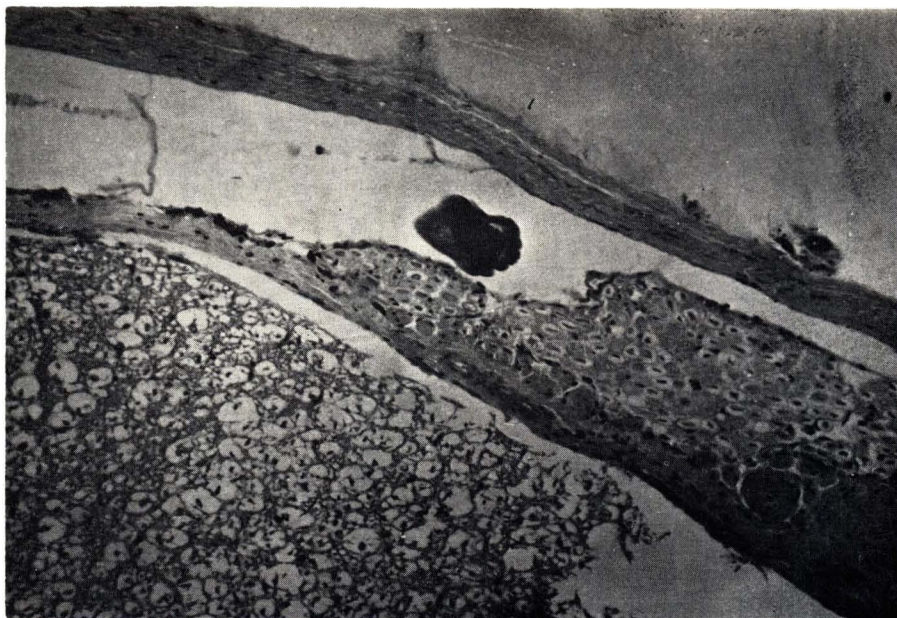dead parasite was noted in the white matter of the dorsal portion of the lumbar enlargement of the spinal cord of the same sheep (Fig. 3). A enlargement of



*Fig. 3.* Parasite in dorsal horn of lumbar spinal cord. Note lymphocyte infiltration and glial proliferation. H and E. Original magnification  $\times 100$ ; reduced to  $\frac{3}{4}$ .



parasite adjacent to the dorsal root of the spinal nerve was found in the lumbar the second sheep (Fig. 4).



*Fig. 4.* Parasite adjacent to the dorsal root of a lumbar spinal nerve. H and E. Original magnification  $\times 100$ ; reduced to  $\frac{3}{4}$ .

Focal hemorrhage and liquefaction leading to microcavitation, eosinophilic and lymphocytic meningitis, vascular cuffing, neuronal degeneration and swelling of axis cylinders were noted in different parts of the lumbar enlargement and the thoracic region (Fig. 5) of the spinal cord of both sheep. Moderate congestion, hemorrhages and eosinophilic cuffings were found in the white matter and fissures of the cerebellum of the first sheep. No significant changes were found elsewhere in the brain.

## TREATMENT

Shoho (8) recommended diethylcarbamazine which he had shown to be useful in the treatment and control of cerebrospinal nematodiasis.

We used diethylcarbamazine citrate (Franocid) successfully for treatment. : 1 ml per 20 Kg bodyweight for three days, the first dose intramuscularly and the next two orally and then 0.5 ml per 20Kg bodyweight orally for three more days.

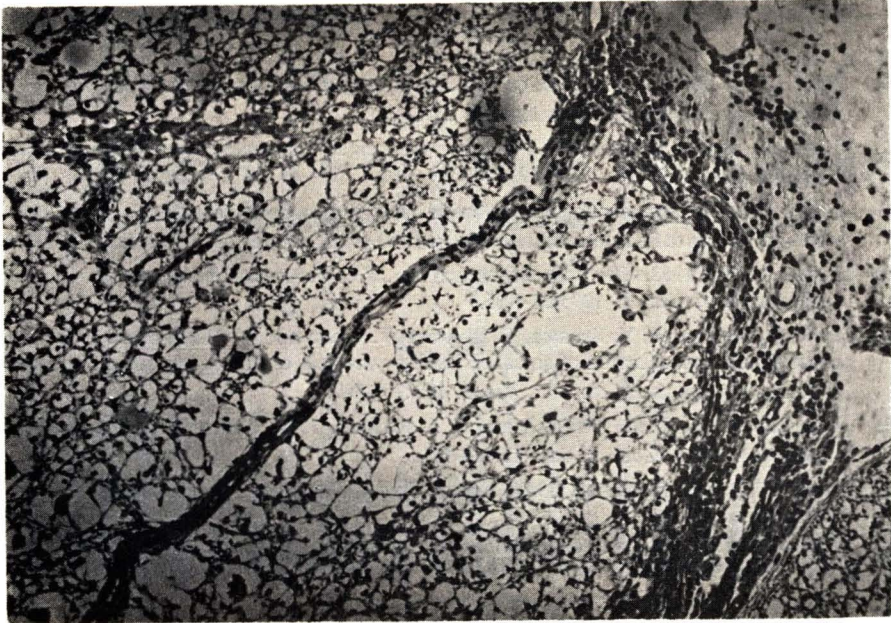


Fig. 5. Eosinophilic and lymphocytic leptomeingitis in thoracic spinal cord. Note involvement at ventral fissure in lower right area. Focal hemorrhages with liquefaction. H and E. Original magnification  $\times 100$ ; reduced to  $\frac{3}{4}$ .

## DISCUSSION

According to Japanese authors (5), the adult form of *Setaria digitata* is found in the peritoneal cavity of cattle. Their microfilariae disperse in the peripheral blood of the bovine, where they are ingested in a blood meal by mosquito vectors such as *Anopheles hyrcanus sinensis* and *Armigeres obturans*. The infestive larvae are introduced into hosts such as sheep and goats and, after an incubation period of 14 to 30 days in these animals, the parasite reaches the spinal canal where, by traumatic damage, it causes paralytic disorders.

The aim of this communication was to report lumbar paralysis in sheep caused by parasite larvae infestation. Since *Anopheles hyrcanus* and *Aedes* genus are the dominant mosquitos in the Caspian Sea area and since *Setaria digitata* has been found in cattle and buffalos in this region and, especially, because the observed larvae resembled *Setaria spp.*, it would be reasonable to state that the larvae probably were *S. digitata*. The therapeutic and prophylactic effect of diethylcarbamazine, an antiparasitic drug, confirms the interpretation that the cause of the paralysis in the flock was parasitic infestation.

## REFERENCES

1. Boer, C. H. 1968. Reconstruction of the subfamily Elaphostrongylinae parasite of the Brsing deer. *Parasitologia (Leningrad)*. 2:312-316.
2. Delpy, L. and M. Kaveh. 1937. Neuraxite enzootique des jeunes chevreaux. *Bull. Acad. Vet. France*. 10:332-338.
3. Innes, J. R. M. Necrotising encephalomyelitis of unknown aetiology in goats in Ceylon with similarities to Setariasis of sheep, horses and goats in Japan. *Brit. Vet. J.* 107:187-203.
4. Innes, J.R.M. 1953. The possible occurrence of cerebrospinal Nematodiasis in goats in India. *Brit. Vet. J.* 109:451-455.
5. Ishii, S., A. Yajima, Y. Sugawa, T. Ishiwara, T. Ogata and Y. Hashiguchi. 1953. The experimental reproduction of so-called lumbar paralysis-epizootic cerebrospinal Nematodiasis-in goats in Japan. *Brit. Vet. J.* 109:160-167.
6. Kennedy, P. C., J. R. Whitlock and S. J. Roberts. 1952. Neurofilariasis, a paralytic disease of sheep. *Cornell Vet.* 42:118-124.
7. Nobel, T. A. and P. Olafson. 1956. Spinal Nematodiasis in sheep. First report in Israel. *Refuah Vet.* 13:1-3.
8. Shoho, C. 1952. Further observations on epizootic cerebrospinal Nematodiasis. *Brit. Vet. J.* 108:134-141.
9. Tanaka, S., S. Suu, C. Shoho and S. Yamagiwa. 1945. Equine Setariasis. *Jap. J. Vet. Sci.* 7:117-130.
10. Yamagiwa, S. and C. Shoho. 1944. Ovine Setariasis. *Jap. J. Vet. Sci.* 6:413-422.