

FIRST REPORT ON THE CAPILLARIA ANNULATA IN IRAN (*)

By :

A. R. Amjadi

Pathology Department of Razi Institute

Tehran - Iran

Introduction

Capillariasis is one of the important parasitic condition which causes considerable economic losses in various part of the world as well as in Iran. Since the description of *C. annulata* by Molin in 1885, many workers have devoted much time to study the mode of its transmission⁽⁵⁾ the pathogenicity⁽¹⁾ of the parasite and the various problems associated with its control^(2,3,4).

The object of this note is to report a field case of this parasitism in 42 turkeys of native breed with emphasize on the pathological findings and the control measure which has been applied.

Material and Method

Material consisting of sick and dead turkeys was received in the pathology department for diagnosis. There were 42 six months old local breed bronze turkeys in the flock being kept in free range system.

Tissues from oesophagus crop, intestine, skeletal muscle, liver, heart proventriculus and gizzard were collected and fixed in 10% formol saline solution for histopathological examination and a few impression smears made from mucous membrane of the oesophagus and crop scraping for direct microscopic examination.

The tissues were processed by Parafine embedding methode. The sections cut in 5μ in thickness and stained with Hematoxylin and eosine.

Results

1) Clinical symptoms :

The whole flock showed symptoms of various stages of a sickness. They

(*) Presented in 3rd Cento Vet. Path. Sem. Pendik. Turkey Nov. 7 - 12, 1966.

were depressed with droopy wings. Some of them were laying down not inclined to move unless being disturbed, the rest moved but very slowly. Signs of weakness, watery diarrhea and weight losses were visible; the average body weight of the birds being about 1 kg. The disease developed in one week and four birds were death during that period.

2) Autopsy findings:

Sick birds were sacrificed and autopsy done immediately afterwards. The carcasses being pale and emaciation associated with sever anemia were present.

The main lesions were confined to the upper digestive tract; specially the mucosa of the crop being immensely thickened, roughened and badly macerated. (Fig. 1) Direct microscopic examination of the fresh impression smears made from scrapings of the crop mucous membrane revealed, a large number of Angular worm eggs and with more macroscopic investigation masses of thread like worms which were embeded under the necrotic tissues of the crop epithelial layer could easily be seen with naked eyes.

3) Histopathological changes:

Microscopically many cysts like vacuols containing cross sections of the worms were observed (Fig. 2).

Thickening of the epithelial layer was initiated by the invading worms burrowing into the crop mucosa, enlargement of the glands in the areas in which the worms were located and severe inflammatory reactions caused by this intensive worm infestation.

The isolated recovered worms were identified and found to be *C. annulata* which had not been diagnosed in this country before.

Treatment :

Methyridine (I.C.I) has been used as an antihelminthic in different worm infestation of cattle, sheep, calf, lamb and for intestinal parasite in turkey⁽²⁾, pigeons and chickens⁽⁴⁾ by subcutaneous or oral administration. The dosage of Methyridine recommended by Walley (1961)⁽⁶⁾ for cattle and sheep is 200 mg per kg. of the live body weight. The drug being available commercially as a 90% solution in water, which is too concentrated to allow accurate dosage for birds. Therefore the commercially available sample of the drug was diluted to 47.9% and 1% from this dilution was added to drinking water. The resulting medicated water was given to the whole flock for period of 8 hours. The activity of the drug was investigate, 3 days after administration of the drug, by examination faecal samples at 3 days intervals. Not a single worm egg was found at any time after medication.

RESUME

Pour la première fois, en Iran, nous avons observé *Capillaria annulata* chez un troupeau de dindonneaux composé de 41 dindonneaux âgés de 6 mois.

Le parasite a été observé dans les coupes histologiques préparées de jabot

ainsi que dans les tissus d'oesophage. Quatre de ces dindonneaux ont été morts avant le traitement et les autres sont guéris par l'application de Methyridine fabriquée par ICI (Angleterre).

Acknowledgement

The author gratefully acknowledges the encouragement given to him by Dr. M. Kaveh Director general and Dr. V. Sohrab, head of the Department of Poultry Pathology of Razi Institute.

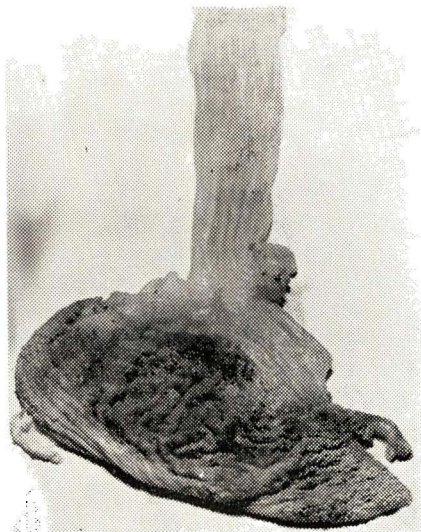


Fig-1: Crop of the turkey heavily infested by *C. annulata* note the rough and macerated mucosa.

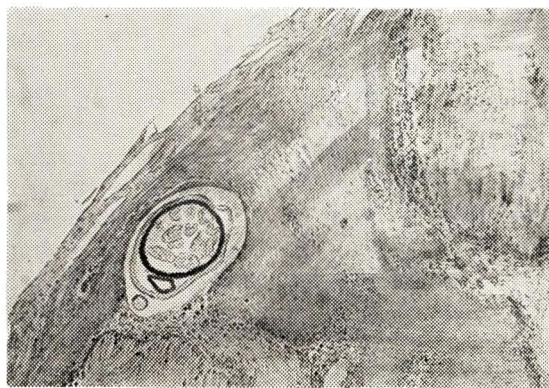


Fig-2: The same crop showing the parasite and Angular worm eggs in the stratified squamous epithelium of the crop.

REFERENCES

- 1— Emmel M.W. : Observations on *Capillaria contorta* in Turkey. Jour. Am. Vet. Med. Assn. **94**-612 (1939).
- 2— Fernando S.D.A. & Jayasinghe. J.B. 1964: The control of intestinal helminth parasite in Turkey by the Methyridine. Indian Vet J. **41**, 102-104.
- 3— Norton. C.C. & Joyner, L.P. (1965): Experimental chemotherapy of infection with *Capillaria Obsingata*. J. Comp. Path. **75**, 137-145.
- 4— Thienpont. D. & Mortelman. J. (1962): Methyridine in the control of intestinal *Capillaria* in birds Vet. Rec. **74**, 850-852.