

Experimental Pathology of *Ornithobilharzia turkestanicum* in Sheep

Short Communication

Ezzi,¹ A., Karimi G.H.² and Gholami, M.R.¹

1. Pathology Dept., Razi Vaccine & Serum Research Institute,
P.O.Box 11365-1558, Tehran, Iran

2. Parasitology Dept., Razi Institute

Received 2 Dec 2003, accepted 23 Apr 2004

Summary

To study the experimental pathology of *Ornithobilharzia turkestanicum* (*O.turkestanicum*) in sheep, 15 healthy sheep were chosen and classified into three groups at 5 each. Group 1 was dermal contacted with *O.turkestanicum* infected snail cercaria, group 2 was injected with the cercaria intra dermally and group 3 was considered as control. Clinical signs and egg counts were recorded continually. After one year they were sacrificed, autopsied and the tissues such as lung, liver, intestine and lymph nodes were examined grossly and microscopically. Granulomatous nodules were revealed in liver and intestine. Thrombophlebitis and the section of adult parasite within the veins were observed in liver tissue. Also the rosette formation around the egg larva was prominent at the center of the granuloma. By comparison two routes of applying the experiment we found out massive destruction of the liver and intestine was in group two rather than group one.

Key words: *Ornithobilharzia turkestanicum*, pathology, sheep

Introduction

Ornithobilharzia turkestanicum (*O.turkestanicum*) is a trematod that live in the mesenteric veins of sheep. The intermediate host is snail (*Lymnea gedrosiana*) and the definite hosts are sheep, goat, and cattle (Soulsby 1982, Jubb *et al* 1985, McGavin *et al* 2001). The parasite has a great economic importance in sheep

*Author for correspondence. E-mail:ezzi@rvsri.com

because of severe losses in meat and wool and also damaging of intestine makes useless for processing as sausage skin (Massoud 1973). *O.turkestanicum* was first found in cattle from Russian Turkestan and named *Schistosoma turkestanicum* (SkrJabin 1913). Isolation of the parasite was reported from North China (Hsu 1938), Pakistan (Abdussalam & Sarvar 1952), and various parts of the southern Russia (Zakhrylov 1964, Azimov *et al* 1965). In Iran the infection rate of 28% was first reported from Dezful, north of Khuzestan province (Arfa 1965), and 15.6% in the northern and central parts of the province (Massoud 1973). Malaki *et al* (1994) described pathology of the natural infection of the parasite in Fars province (south west of Iran). In this study the experimental pathology comparing the lesions of two forms of *O.turkestanicum* infection, dermal contact and intra dermal injection, was discussed.

Materials and Methods

During one year (2001-2002) fifteen healthy sheep aged 6 months were chosen, kept at the Research Center of Razi Institute, and were fed hay, straw and barley. They were classified in to 3 groups each of 5 as follow. *O.turkestanicum* infected snails were gotten and collected in a Petri dish with tapping and stimulating them. Five sheep were infected with 5000-10000 of the prepared cercaria by a leg immersion technique (dermal contact). The left front leg of each animal was closely clipped by 3 inches above the knee and a thick polythene bag containing the cercaria suspension was immersed. Five sheep were inoculated by 5000-10000 suspension of the cercaria under the shoulder intra dermally and five sheep were used as control. During one year the clinical conditions of all the animals were examined precisely. At the end of the experiment they were sacrificed and autopsied. The contents of the digestive tract were sent to the Parasitology Department for egg counting. The organs such as liver, lung, spleen, rumen, reticulum, omasum, abomasums, deodenom, jejunum, ileum, caecum, and colon were examined then fixed in

formalin saline 10%. In order to detect the lesions histopathologically the fixed tissues were trimmed 6 μ by rotary Microtome. The slides were stained by Haematoxylin and Eosin.

Results and Discussion

Clinical signs. During the experiment there was only harsh hair and a hollow appearance of the abdomen. Gross lesions indicated many minute grayish foci on the surface and section of the liver. There were hemorrhagic foci in small and large intestine. The lung tissue was shown mildly congested.

Histopathology. There were considerable lesions in liver and intestine. Lung tissue showed thickening of plevre membrane and alveoli wall as well as scattered hemorrhages. There was also mononuclear infiltration within the alveoli wall. In liver the hepatic cells were showed cloudy swelling and also scattered hemorrhages were noted. Numerous nodules including parasite eggs arrested at the center of granulomas (mostly eosinophile and giant cell infiltration) were intermingled together in liver and intestine (Figure 1). Some of the egg larva was degenerated (Figure 2).

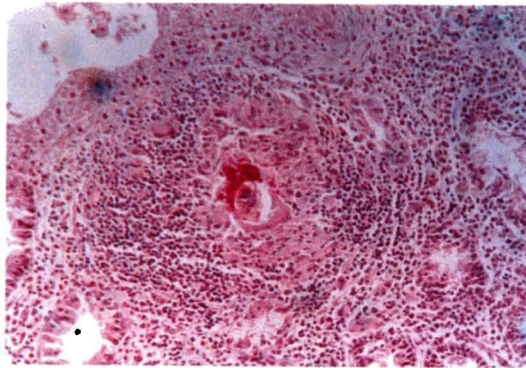


Figure 1. *Granuloma formation including the parasite egg in intestine H&E (200 \times)*

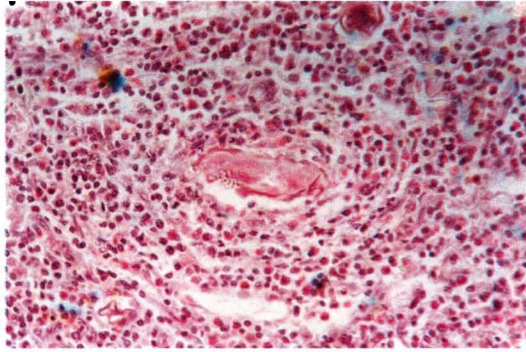


Figure 2. Granuloma formation including the degenerated parasite egg in intestine H&E (200×)

Surrounding few of them was showed rod shaped eosinophilic bodies (rosette form) in liver (Figure 3) and intestine. The connective tissue was influenced in to some of the partial necrotized granuloms in liver. Phelebitis (Figure 4), thrombosis, and the section of adult parasites were occluded within the hepatic veins (Figure 5). Also focal bile duct hyperplasia was prominent. The intense attraction of eosinophil infiltration to the situe of released eggs has been reported due to delayed hypersensitivity (Meleney *et al* 1953, Warren *et al* 1967).

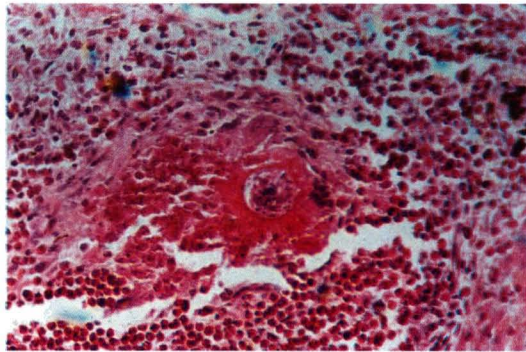


Figure 3. Granuloma formation. Rosette form around the egg larva and infiltration of eosinophils in liver H&E (400×)

This study was carried out basically on pathology of *O.turkestanicum* originated from Shadegan (northern and center of Khuzestan province). Comparison of two different types of *O.turkestanicum* infection in sheep indicates that the severe lesions

revealed in intra dermal route of the infection. Endophelebitis and thrombosis appearance and rosette formation are in accordance with Massoud (1973).

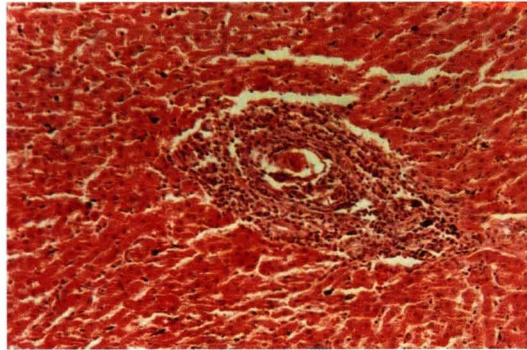


Figure 4. *Phelebitis and infiltration eosinophils in liver H&E (200×)*

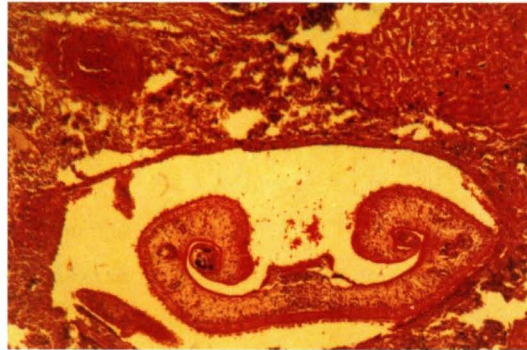


Figure 5. *Section of adult parasites within the vein of liver H&E (100×)*

Acknowledgement

The authors wish to thanks to Dr. H. Paykari, Head of Parasitology Dept., Razi Institute for reviewing the manuscript.

References

Abdussalam, M., Sarvar, M.H. (1952). Occurrence of *Ornithobilharzia turkestanicum* in Pakestan. *Proceedings of 4th. Science Conference, Pakistan.*

- Arfa, F., Sabbaghian, H. and AleDawood, H. (1965). Studies on *Ornithobilharzia turkestanicum*. *Annual Parasitology & Human Competitive* 40:45-50.
- Azmov, D.A., Nurmukhamedov, K.H. (1965). *Ornithobilharzia turkestanicum* in sheep and cattle in Uzebeckestan. *Nauchnoissled Inst.Veterinary* 17:9-10.
- Hsu, H.F. (1938). *Schistosoma turkestanicum* in North China. *Chinese Medical Journal* 54:568-570.
- Jubb, K.V.I., Kennedy, P.C. and Palmer, N. (1985). *Pathology of Domestic Animals*. (3rd edn.), vol.3. Academic Press, INC., U.S.A.
- Maleki, M., Khodokaram, A., Oryan, A., Aslani, M., Housseinzadeh, S.A. and Sadjadi, S.M. (1994). Pathological findings in Ornithobilharziasis in the herds of sheep and goat of Assyrians in Fars Province, Iran. *Research & Reconstruction* 24:143. (In Persian).
- Massoud, J. (1973). Studies on the Schistosomes of Domestic Animals in Iran, 1- Observation on *Ornithobilharzia turkestanicum* in Khuzestan. *Journal of Helminthology* vol.xivii (2):165-180.
- McGavin, M.D., Carlton, W.W. and Zachary, J.F. (2001). *Thomsons Special Veterinary Pathology* (3rd edn.). Mosby, U.S.A.
- Meleney, H.E., Moore, D.V. (1953). Observations on immunity to superinfectuin with *S.mansoni* and *S.haematobium* in Monkeys. *Experimental Parasitology* 3:128-139.
- SkrJabin, K.I. (1913). *Schistosoma turkestanicum*, non.ap.ein.neuri.Parasit.de Rinde.aus Russisch Turkestan , *Zeit.F. Infektions Krank* 13:451-468.
- Soulsby, E.J.L. (1982). *Helminthes, Arthropods and Protozoa of Domesticated Animals* (7th edn.) Bailliere Tindall, London, U.K.
- Warren, K.S., Domingo, P.J. and Cowan, R.T.B. (1967). Granuloma formation around *Schistosoma* egg as a manifestation of delayed hyper-sensitivity. *American Journal of Pathology* 51:735-767
- Zakrylov, Ya.N. (1964). On the distribution of *Ornithobilharzia turkestanicum* in the Far East. *Obshch Gelminth* Pp:128-131