

Full Article

Experimental studies of pathogenicity of Chicken Infectious Anaemia Virus (3 isolates) in Iran

Ezzi¹, A., Shoushtari*², A., Marjanmehr³, H., Toroghi⁴, R., Tavasoly³, A., Bahmani-nejad², M.A.

1. Department of Pathology, Veterinary Medicine, Razi Vaccine & Serum Research Institute, Karaj, Iran

2. Department of Avian Diseases, Research & Diagnosis, Razi Vaccine & Serum Research Institute, Karaj, Iran

3. Department of Pathology, Veterinary medicine, University of Tehran, Tehran, Iran

4. Department of Biotechnology, Razi Vaccine and Serum Research Institute, Mashad, Iran.

Received 02 Jun 2010; accepted 07 June 2011

ABSTRACT

To evaluate pathogenicity of 3 Chicken Anemia Virus isolates-CV1, CV2 and CV3 respectively - the current experiment carried out. After titrating of the viruses, 30 one day old SPF chicks were grouped and intramuscularly inoculated with each isolate in a separate group. Two other groups as positive and control groups were inoculate with a live vaccine virus and normal saline respectively. During the study the birds in first three groups clinically showed ruffling feathers, depression and body weight reduction. After 18 days they were weighed, bled and euthanized. Three birds were found dead during the experiment (one in each tested group). Antibodies against CAV in the serum of all 3 groups were detected while no antibody found in negative control group. Hematocrit Values of the three tested groups were under the normal. Grossly the thymus and bursa tissues were severely atrophied. Bone marrow became yellowish and pale. In histopathological study we found aplasia and devoid of erythroid and myeloid cells replacing by fat cells in bone marrow. Severe atrophy and depletion in thymus ,bursa of Fabricius and bone marrow tissues statistically were analyzed and showed that the significance difference in comparing with control groups ($p<0.05$). By using a type specific Polymerase Chain Reaction (PCR) assay the occurrence of virus was confirmed in thymus and liver tissues. In conclusion the authors interpreted that the 3 strains of CAV were able to infect and induce a wide range of damages in one day old SPF chickens

Keywords: Chicken Anaemia Virus, PCR, Competitive Elisa Test, Hematocrit Value, Pathology

INTRODUCTION

Chicken Anaemia Virus (CAV) is a small non enveloped icosahedral virus with a negative sense, single stranded circular DNA genome. It has been classified as the only member of the genus Gyrovirus of the family Giroviridae (Pringle 1999, Oluwayelu *et*

al 2005). The genome of the virus encodes one structural (VP1) and two nonstructural (VP2 and VP3) proteins(Todd *et al* 2002). VP3 or apoptin induces apoptosis in infecting cells (Noteborn *et al* 1994). It is not only the causative agent of chicken infectious anaemia (CIA) and an immunosuppressive disease of young chickens, but also infects the chickens of all age groups.

It has been originally isolated by Yuasa *et al.* 1979. Chicken is the only recognized natural host, but

* Author for correspondence. Email: m. Hamid1342ir@yahoo.com

serological survey has revealed the prevalence of this disease in domestic and wild birds (Farkas *et al* 1998). CAV is important because of its potential for inducing immunosuppressant (Rosenberger & Cloud 1998). The first occurrence of CAV in Iranian broiler chicken flocks has been reported by Toroghi *et al.* in 2003. However the pathogenesis of these viruses remained obscure. Dual infection of Chickens has been reported by Shoushtari and his colleagues in 2006. CAV can be transmitted horizontally (lack of maternal antibodies) and vertical (hens infected by egg born) routes (Rosenberger & Cloud 1989).

This paper describes the experimental pathogenesis study of 3 isolates of chicken anemia virus (CAV) on SPF chicks which were isolated from different flocks in slaughter house in Tehran province. The pathogenesis of the disease had been obscure. Therefore it was carried out to induce the infection of CAVs in one day old SPF chicks. Also pathological atrophy ratios in thymus, spleen, bursa of Fabricius and bone marrow tissues in comparison with the control groups have been discussed carefully.

MATERIALS AND METHODS

The Preparation, viral isolation and titration procedures. Liver was homogenized and treated with antibiotics, heating (72 °C in 10 minutes) and chloroform. The liver suspensions were prepared in PBS and antibiotic (100 Iu penicillin and 100 µg dihydrostreptomycin per ml) and chloroform were added (0.05 ml CHCl per 1 ml of homogenate). The mixture was centrifuged at low speed (4000 rpm at 40 min.). The supernatants were harvested and incubated in 70 °C for 10 minutes and finally isolated the CAVs. (CAV1, CAV2 and CAV3) respectively. Then day old SPF chicks were intramuscularly inoculated by 0.1 ml of each sample. To confirm that samples were free from influenza, IBD (Infectious Bursal Disease) and Newcastle disease viruses. The liver homogenates was passaged in SPF embryonated eggs three times. The absence of Marek Disease virus confirmed by a specific

PCR assay. The Chicken Infectious Dose (CID) was measured by inoculation of one day old chicks, using Reed and Mouch method (Reed & Mouch 1938).

Design of experiment. Fifty one day old SPF chicks were grouped into five groups and kept in 5 isolated cages through 18 days of this study. The first three groups were inoculated intramuscularly with 0.1 ml of the three CAV isolates respectively. Each inoculum contained 10^2 CID₅₀ of each isolate. The fourth group was inoculated with the same dose of a commercial wide used live CAV vaccine. The last group considered as control negative group which inoculated with normal saline. After 18 days all live chicks were weighed and collected blood samples. Then they were euthanized for clearly consideration and examination for gross and histopathological changes.

Packed blood cell volume and ELISA. By using the microhematocrit method, the packed cell volumes (Hematocrit) were determined on a blood samples collected from each bird (18 days after inoculation). CAV antibodies were measured using the Competitive Eliza Test, FlockChek® CAV (IDEXX, USA) according to the manufacturer instruction at a 1:10 serum dilution

DNA extraction and PCR. The presences of CAVs in samples were confirmed by a described type specific PCR method using primers C1 (CCAAGAAGATACTCCACCCG) and C2 (TACGATACCGCTGTCTCCTC) as described (Imai *et al* 1998). Viral DNA was extracted from 200 µl homogenate tissue samples using the High Pure Viral Nucleic Acid kit (Roche, Germany) and dissolved in 50 µl distilled water. The PCRs were performed with 4µl of the extracted DNA in a final volume of 50µl using the following condition: denaturation (94 °C, 1min.), annealing (48 °C, 2 min.), extension (72 °C, 90s), 25 cycles followed by a final extension (72 °C, 10min). The final products was analyzed by electrophoresis in a 2% agarose gel, stained with ethidium bromide and visualized by UV transillumination (UVP).

Histopathology. After 18 days the birds were euthanized. The liver, bursa of Fabricius, spleen, bone

Marrow, thymus and skeletal muscle were fixed at neutral buffered 10% formalin, processed and embedded in paraffin wax. The blocks were sectioned by rotary microtome in 5µm thickness and stained with Hematoxylin and Eosin. The lesions of bursa and thymus evaluated for lymphocyte depletion and scored as 1: normal, 2: mild, 3: moderate and 4: severe infections. The most severe lesion score was recorded for each flock (Hagood *et al* 2000).

Statistical analysis. The significance of data from body weight, Hematocrit value and atrophy index of thymus and bursa Fabricius were determined by one way analysis of variance using SPSS package (version 3.1).

RESULTS

Clinical and macroscopic findings. All chicks in three test groups showed ruffled feather and among them some showed hemorrhage in thigh muscles (Figure 1).

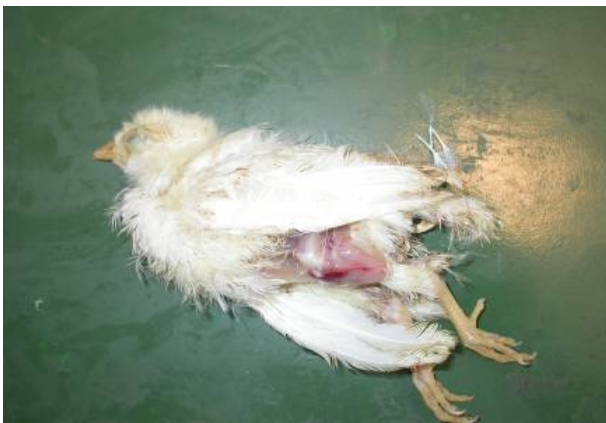

Figure 1. One chicks died in day 14 post inoculation in group one. The chick showed ruffled feather and hemorrhages in thigh.

Three chicks were found dead during the study in groups (1, 2 and 3) between days 11-15 after inoculation. The inoculated chicks became emaciated and depressed because of anemia and sever atrophy of the thymus (Figure 2). Bone marrow of the femur was hypoplastic and yellowish appearance (Figure 3). Liver tissue showed enlargement and discoloration. Bursa fabricius indicated atrophy about half normal size

(Figure 4). As it has been shown in table 1 the body weights of the tested groups were significantly less than those of the vaccine and the control groups ($P < 0.05$).

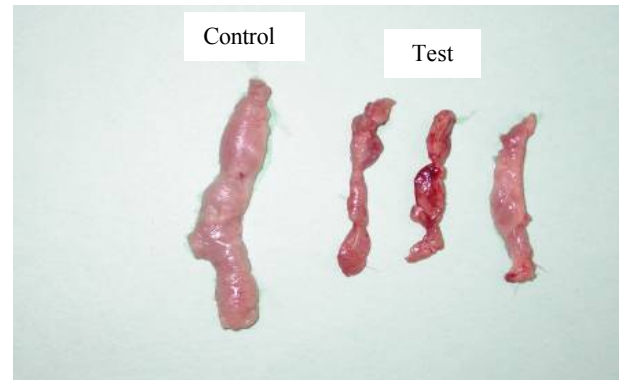


Figure 2. The chicks showed sever atrophy of the thymus (right side) comparing to the control one (left side).

Blood and serum investigation. The mean Hematocrit values (table 1) of all three tested groups were significantly reduced in comparison with control ones ($P < 0.05$). The competitive ELISA Test detected that all of the chicks had antibody against CAV (table 1). Also the occurrence of anisocytosis, reticulocytes and immature erythrocytes were observed which indicating of reversible anaemia.

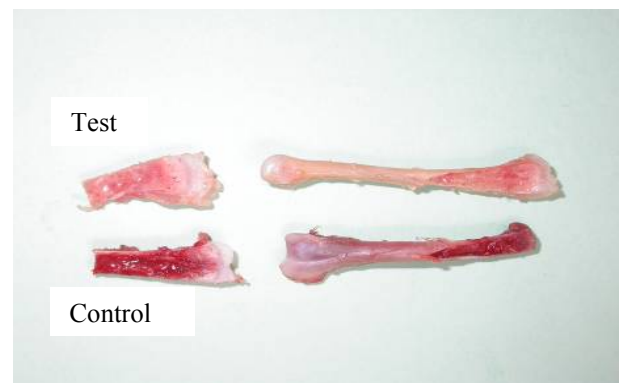

Figure 3. The femoral bone marrow showed hypoplastic and yellowish (top) from an infected chick, compared with that of a control bird (bottom), 18 day after day old inoculation.

The PCR assay technique. To follow the existence of the virus in different steps of this study, specific PCR with amplifying 450 base pairs PCR product was used. The presence of virus was confirmed by using PCR assay in liver, thymus, spleen, bone and bursal tissues (Figure 5).

Histological findings. Main histopathological lesions of the affected chicks were included: hyperplasia of immature hematopoietic cells undergoing to severe aplasia or hypoplasia replacing by fat cells (75%).

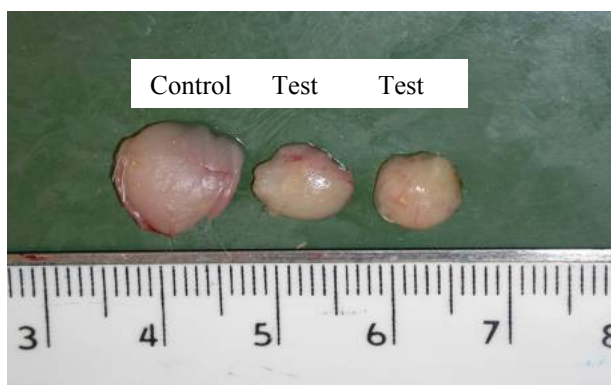

Figure 4. The infected bursa showed atrophy (about half normal size) compared with that of a control bird.

Depletion of the erythrocyte and granulocytic cells within the intra and extra vascular were also prominent in the bone marrow (Figure 6) .In the thymus severe depletion and karyorrhexis of lymphocytes were scattered in the cortex and lobular atrophy included hyperplasia of reticular cells were present (Figure 7).

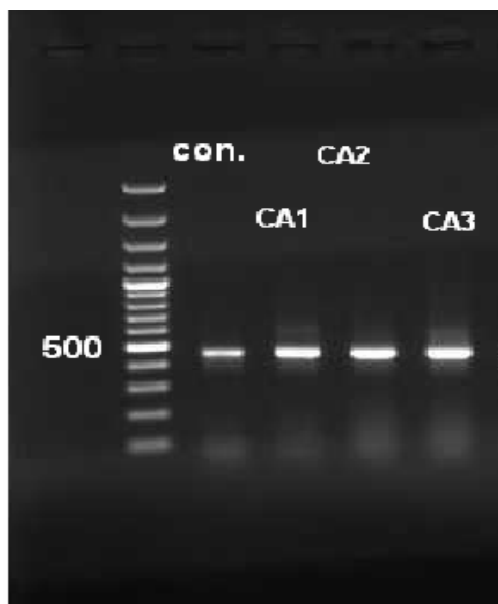

Figure 5. The typical result of molecular tests. The PCR products of 450 base pairs length were amplified to confirm the presence of CAV isolates in different tissues throughout the study. A Live vaccine virus used as positive control (cont.) sample.

A few cells had eosinophilic inclusion bodies in their nuclei (Figure 8). Shrinkage of follicles in the bursa which included moderate to severe depletion of lymphocytes with hyperplasia of reticular cells were observed (Figure 9).

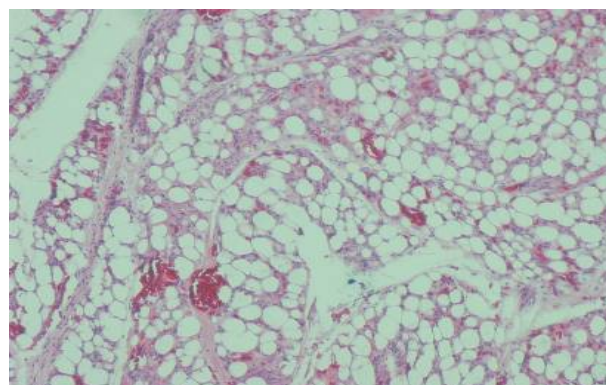


Figure 6. Bone marrow from 18 day old chickens showed severe aplasia or hypoplasia replacing by fat cells associated with scattered hemopoietic tissue (H&E 400x) .

In the spleen hyperplasia of reticular cells and repopulation of lymphocytes were observed. Also hepatocytes of the liver showed degeneration. Semi quantitative histological findings expressed the atrophy index for each tissue. However the data was statistically different in comparison with the thymus, bone marrow and bursa fabricius with control group, $P < 0.05$ (table2).

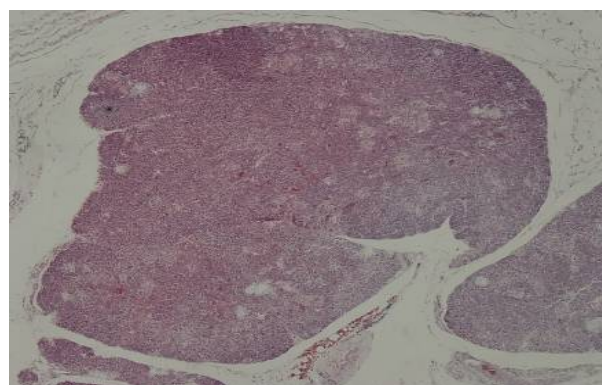


Figure 7. Thymus from 18 day old chickens showed severe depletion of lymphocytes in the cortex of thymus and the absence of demarcation between medulla and cortex (H&E 40x).

DISCUSSION

Yuasa and co-workers were first to report chicken anemia virus (CAV) in 1979. Since then a large number of published material have focused on serological

detection of CAV. Nevertheless only a few have successfully isolated and characterized viruses.

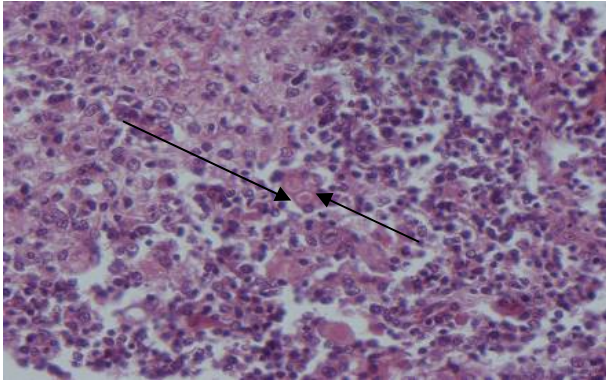


Figure 8. Thymus section of a 1 day old chicken 18 days after inoculation showed eosinophilic intranuclear inclusion bodies in thymocytes (arrows) (H&E 400x).

In Iran, the infection was initially noted by Toroghi at abattoir in 2003. He reported extensive hemorrhage in skeletal muscles of infected carcasses, a finding that was repeatedly reported by other Iranian workers (Farhoodi et al 2007) in the following years. While CAV infection is understood to be most pathogenic in young growing birds, until now the infection has only been traced in slaughter age chickens in Iran. The present work therefore, was conducted to investigate the pathogenicity of CAV in day-old chickens.

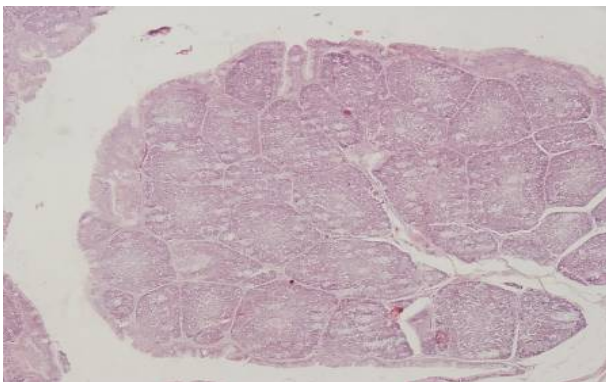


Figure 9. Bursa of Fabricius from 18 day old chickens showed shrinkage of follicles with moderate to severe depletion of lymphocytes (H&E 40x).

In the course of research, three clinical Iranian CAV isolates were used to infect chickens and in consequence, all the birds developed the expected clinical symptoms. In postmortem examination, lesions

induced by three viruses showed generally identical distribution pattern with only little difference in terms of severity and an observation that was previously highlighted by other investigators (Yuasa *et al* 1985, Schat & van Saton 2009).

Table 1. The body weight, hematocrit and ELISA values were presented.

Groups	CAV1	CAV2	CAV3	4 Vac.	5 Con.
Weight	91.3	89.5	88.9	120.2	124.8
Hematocrit	23.5	24.1	25.7	33.4	36.1
Elisa	10/10	8/10	7/10	9/10	-ve

Vac.=Vaccine , Con.=Control.

Another intriguing finding of this study was the fact that all infected birds in the three study groups, proved seropositive against CAV antibody at the end of study period when they were 18 days old. This is in contrast with observation of other works that despite apparent clinical symptoms, diseased chicken failed to develop seropositive blood test.

Table 2. Histopathologic lesion scores of thymus , bone marrow and bursal in the infected with CAV isolate and in uninoculated control chicks.

Groups & number	Thymus		Bone marrow		Bursal		
	Mean	SD	Mean	SD	Mean	SD	
CA1	9	3.20	1.03	3.20	1.03	2.40	0.69
CA2	9	3.40	1.07	3.40	1.07	2.60	0.69
CA3	9	2.70	1.33	2.70	1.33	2.60	1.26
Vaccine	10	1	0	1	0	1	0
Controls	10	1	0	1	0	1	0

This discrepancy might be explained by application of different antibody detection strategies used by researchers. (Toro *et al* 1997) We have used a Competitive ELISA method compared to immunofluorescence based systems that were employed by majority of other workers (Yuasa *et al* 1980, Yuasa *et al* 1985, McNulty *et al* 1989). The lower hematocrit counts seen in infected chickens here compared to the controls can be reasoned by virus tropism to hemopoietic cells which is materialized by extensive lesions in bone marrow. The yellowish appearance of bone marrow in diseased birds is an indication of replacing normal tissue with fat cells.

Following pathological changes in hemopoietic system, deficiency in oxygen supplying capability of blood will result in failure to gain weight. This condition was seen in chicken under test where infected birds suffered from severe cachexy compared to control group that gained normal weight. Practicing an evidence-based policy, the Iranian Veterinary Organization (IVO) currently encourages farmers to implement a prevention plan against CAV through vaccination of their breeder flocks. By the time CAV vaccination is conducted broadly at national scale, circulation of CAV in broiler farms is imminent. The fact that reports on clinical cases of CAV in week-old and younger chickens in this country are few most likely reflects an infection in the breeder farms. This infection would then have resulted in developing some level of protection in broiler chickens that passively received from the associated breeder farm. Obviously, this type of protection is transient and the growing chickens will eventually turn unprotected against CAV as they become older. Furthermore, the present study displayed the detrimental impacts of CAV on immune system of chickens with apparent concentration in thymus.

The supporting clues can be inferred from reports on secondary infection with bacterial and fungal agents and also vaccination failures in CAV-infected chickens (Otaki et al 1988, Jeurissen et al 1989, McNeilly et al 1995).

Shoushtari and co-workers in 2006 have described co-infection cases of CAV with Marek and influenza viruses in Iran. Taking all these observations into consideration, application of active immunization before maternal immunity of young chickens drops to its protective levels, seems to be necessary.

Acknowledgment

This project (7502013.6.4) was financed by Razi Vaccine and Serum Research Institute and supported by Veterinary Faculty; Tehran University. The authors thank Mr. Gharaghozloian M. and Mrs. Talebloo F. for preparing excellent histopathology techniques.

References

- Farhoodi, M., Toroghi, R., Bassami, M.R., Kianizadeh, M. (2007). Chicken infectious anemia virus among broiler flocks in Iran, *Archive of Razi Institute* 62:1 1-6.
- Farkas, T., Maeda, K., Sugiura, H., Kai, K., Hirai, K., Otsuki, K., Hayashi, T., (1998). A serological survey of chickens, Japanese quail, pigeons, ducks and crows for antibodies to chicken anaemia virus (CAV) in Japan. *Avian Pathology*. 27, 316-320.
- Hagood, L. T. Kelly, T.F. Wright, J.C. & Hoerr F.J. (2000). Evaluation of Chicken Infectious Anaemia Virus and associated risk factors with disease and Production losses in broilers, *Avian Disease* 44,803-808.
- Imai, K., Mase, M., Yamaguchi S. & Yuasa, N. (1998). Detection of chicken anemia virus DNA from formalin-fixed tissues by polymerase chain reaction. *Research in Veterinary Science* 64, 205-208.
- Jeurissen, S. H. M., J. M. A. Pol, and G. F. de Boer. (1989) Transient depletion of cortical thymocytes induced by chicken anaemia agent. *Thymus* 14:115-123.
- McNeilly, F., Smyth, J.A., Adair, B.M. & McNulty, M.S. (1995). Synergism between chicken anaemia virus (CAV) and avian reovirus following dual infection of 1 day old chicks by a natural route, *Avian Disease*, 39 : 532-537.
- McNulty, M. S., Connor T. J., McNeilly, F., and Spackman, D. (1989) b. Chicken anemia agent in the United States: Isolation of the virus and detection of antibody in broiler breeder flocks. *Avian Disease* 33:691-694.
- Noteborn, M.H.M., Todd, D., Verschuren, C.A. de Gauw, H.W.F.M., Curran, W.I. Veldkamp, S., Douglas, A.J. McNulty, y M.S. von der Eb, A.J. and Koch, G. (1994). A single Chicken Anaemia Virus protein induces apoptosis, *Journal of Virology* 63, 346- 351.
- Oluwayelu, D.O., Todd, D., Ball, N.W. Scatt, A.N.J. Oladele, O.A. Emikpe, B.O. Fagbohun, O.A. Owoade, A.A. Olaleye, O.D. (2005). Isolation and preliminary characterization of Chicken Anaemia Virus from chickens in Nigeria, *Avian Disease* 49, 449- 450.
- Otaki, Y., Tajima, M., Saito, K. & Nomura, K. (1988). Immune response of chicks inoculated with chicken anemia agent alone or in combination with Marek's disease virus or turkey herpesvirus. *Japanese Journal of Veterinary Science* 50, 1040-1047.
- Pringle, C.R. (1999), Virus taxonomy at the XI th. International Congress of Virology, Sydney, Australia *Archive of Virology* 144, 2065-2070.

- Reed, I.J. & Muench, H. (1938). A simple method of estimating fifty percent endpoints, *The American Journal of Hygiene* 27,493-497.
- Rosenberger, J.K. & Cloud S.S. (1989). The effects of age, route of exposure and co infection with transmissibility of Chicken Anaemia Agent (CAA), *Avian Disease* 33,753-759 .
- Rosenberger, J.K. & Cloud, S.S. (1998). Chicken Anaemia Virus, *Poultry Science* 77, 1190- 1192.
- Schat, K.A and van Santen, V.L.(2009). Chicken Infectious Anemia. In Saif, Y.M., Barns H.J., Gilsson, J. R., Fadly A.M., McDougald, L.R., Swayne. DE., *Disease of poultry*, 11ed .Ames, IA, Iowa State , University Press.
- Shoushtari, A.H., Ezzi, A., Bozorgmehri, M.H. and Gudarzi, H. (2006). Coinfection of broilers with Influeza ,chicken infectious anemia and Marek viruses. *3rd Iranian Congress of Virology*
- Todd, D., Alistair, N.J.S. Neris, W.B. Borghert, J.B. and Adai, B.M. (2002). Molecular basis of the attenuations exhibited by molecularly cloned highly passage chicken Anaemia virus isolates, *Journal of Virology* 7, 8472-8474.
- Toro, H ,Ramirez, AM ,Larenas, J . (1997). Pathogenicity of chicken anemia virus (isolate 10343) for young and older chickens *Avian Pathology* 26,485-499.
- Toroghi, R. Shoushtari, A.H.Charkhkar, S. Neyazi, M.H. (2003). The first report of Chicken Infectious Anaemia occurrence among Iranian broiler flocks, *Proceedings of 13th Iranian Veterinary Congress*, page 240, Iranian Veterinary Association.
- Yuasa, N., Imai, K. and Tezuka, H. (1985). Survey of antibody against Chicken Anaemia Agent (CAA) by an indirect immuno-fluorescent antibody technique in breeder flocks in Japan, *Avian Pathology* 14,521-530.
- Yuasa, N. Taniguchi, T. Noguchi, T. & Yoshida, I. (1980). Effect of infectious Bursal DiseaseVirus Infection on incidence of anaemia by Chicken Anemia Agent, *Avian Disease* 24,202-209.
- Yuasa N. Taniguchi T. Yoshida I. (1979). Isolation and characteristics of an agent inducing anaemia in chicks, *Avian Disease* 23, 366-385.