



## Bovine Pestivirus Infection: a Cause of Ovulatory Disturbance in Dairy Cows

M. Kafi<sup>\*1</sup>, M. R. McGown<sup>2</sup> and H. Bielefeldt-Ohmann<sup>3</sup>

<sup>1</sup>. School of Veterinary Medicine, Shiraz University, Shiraz V1352, Iran

<sup>2</sup>. School of Veterinary Science, The University of Queensland, Queensland, St. Lucia 4072, Australia

<sup>3</sup>. Department of Microbiology and Parasitology, The University of Queensland St. Lucia, Australia

Received 13 Mar 2010; accepted 5 Oct 2010

### ABSTRACT

Twelve (Experiment I) and four (Experiment II) multiparous dairy cows seronegative to pestivirus were selected and randomly assigned to either a control group which did not become infected or a treatment group in which all cows became infected following intranasal inoculation 9 days before AI. The experimental induction of infection was carried out with 2 ml of non-cytopathic pestivirus (BVD virus) suspension containing  $10^6$  log<sub>10</sub> TCID<sub>50</sub>/ml (Experiment I) and  $10^7$  log<sub>10</sub> TCID<sub>50</sub>/ml (Experiment II). In both experiments, the cows were superovulated on day 10±2 of the cycle using the standard procedures. The cows in Experiment I were artificially inseminated at 12 and 24 h after the onset of estrus and a non-surgical ova/embryo collection was performed 5 days after AI. In Experiment II, the cows were slaughtered on day 6 after superovulation-induced estrus and the ovaries submitted for gross and histopathological examination including immunohistochemistry. Mean (±SE) number of ovulatory sized follicles on day of AI and corpora lutea palpated on day 5 after AI were significantly ( $p < 0.05$ ) higher in control un-infected cows compared to that of the pestivirus infected cows ( $15.1 \pm 2.8$  vs  $9.2 \pm 1.1$  and  $12.2 \pm 2.2$  vs  $2.8 \pm 0.9$ ), respectively. On histopathological examinations, the mean (±SE) number of unovulated lutenised follicles ( $\geq 3$  mm in diameter) present on the ovaries of the control cows on day 6 after estrus was  $6.8 \pm 2.9$  compared to  $1.2 \pm 0.4$  for the infected cows. Further, many corpora lutea in the ovaries of infected cows had a hypoplastic or atrophic wall. In conclusion, the present study demonstrated that pestivirus infection during the period of final growth of preovulatory follicles results in a disturbance in ovulation and development of corpus luteum leading to a poor superovulatory response in multiparous dairy cows.

**Key words:** pestivirus infection, superovulation, immunohistochemistry, ovary, dairy cows



## INTRODUCTION

Non-cytopathic type ۱ bovine pestivirus infection is prevalent in the cattle populations of many countries (see Kafi ۱۹۸۸). In Iran, the prevalence of seropositive cows to pestivirus infection was reported between ۵۰ to ۷۰ percent (Sedigi-Nezhad ۱۹۹۶). Cattle undergoing pre- or postnatal infections are associated with a variety of disease syndromes that include immune suppression, congenital defects, abortion, and mucosal disease and, importantly, disruption of reproductive functions (see Kafi ۲۰۰۱).

It has been demonstrated that spontaneously infected (Virakul *et al* ۱۹۸۸) or experimentally (McGowan *et al* ۱۹۹۳a) induced pestivirus infection at approximately the time of artificial insemination (AI) significantly lower conception rate in dairy cattle. Field studies (McGowan *et al* ۱۹۹۳b; Rufenacht *et al* ۲۰۰۱) have also shown that pestivirus infection is a cause of reproductive loss in dairy cows. The adverse effect of bovine pestivirus infection on the final growth of ovulatory follicles was initially reported in superovulated Holstein heifers by Kafi *et al* (۱۹۹۷). Later, it was shown that acute pestivirus infection disturb follicular development (Grooms *et al* ۱۹۹۸) and corpus luteum development (Fray *et al* ۲۰۰۱ and McGowan *et al* ۲۰۰۳) following experimental infection of seronegative cattle with a non-cytopathic bovine pestivirus.

The aim of the present study was to determine a) the superovulatory response of dairy multiparous Holstein cows experimentally infected with a non-cytopathic isolate of bovine pestivirus (Experiment I). Further, the morphologic changes and the distribution of pestivirus antigens in ovarian structures of the infected cows were evaluated

using gross and histopathological examinations including immuno-histochemistry (Experiment II).

## MATERIALS AND METHODS

### Experiment I

Twelve multiparous Holstein cows, aged ۴ to ۶ years, were selected from a brucellosis free herd. To confirm that they are pestivirus antibody-free, all cows were bled before commencing the experiment. The cows were checked to determine their body condition scores (based on ۱ to ۵), all animals were in a range of ۴ to ۵ of condition score two weeks before breeding. After a general examination, the cows were randomly divided into two control and treatment groups, and placed in two paddocks. The cows were being fed by good quality pasture grass and supplemented based on the pasture condition.

**Experimental infection:** Inocula were prepared shortly before use by adding ۳ ml of bovine serum to ۰.۱۵ ml of virus culture media containing ۶.۵ log TCID<sub>50</sub>/ml to adjust final inoculum to ۵ log TCID<sub>50</sub>/ml of non-cytopathogenic pestivirus. The serum inoculum contained an Australian strain of non-cytopathogenic bovine pestivirus (BVD-type ۱) isolated from a persistently virus carrier Angus cow (McGowan *et al*. ۱۹۹۳a). All cows in the treatment group were infected by intranasal installation of ۲ mls of the inoculum (one ml in each nostril) ۵ days prior to AI. Shortly before inoculation, each cow was isolated from the remaining un-inoculated cows. This way of experimental infection was previously shown to have a high reliability and further the magnitude and duration of viremia-induced is similar to that observed following natural infection (Cook *et al* ۱۹۹۰).

**Sample collection:** All cows were blood sampled ۱۴ days before and immediately prior to virus inoculation. Also, blood sampling was

---

\* Author for correspondence. E-mail:

carried out every second day until day 9 after virus inoculation, and then on days 13, 16, 20 after virus inoculation. Blood samples were kept chilled and after clot formation, the sera were separated and stored frozen at  $-20^{\circ}\text{C}$  until assayed for detection of pestivirus or antibody to pestivirus. All unfertilized and degenerate embryo were stored in straws and frozen in order to examine for isolation of virus or virus-associated antigens. The above-mentioned specimens were shipped to the veterinary laboratory of Camden (N.S.W.) for serology and virus isolation.

**Serological examination:** The sera samples were examined by Gel Diffusion Precipitin (GDP) test to detect antibody to pestivirus. Also, ELISA test was carried out to confirm the GDP test results (Kirkland et al 1997).

**Virus isolation:** Virus isolation was carried out on 0.5 ml of each serum sample collected 2, 4, 6, 8 days after inoculation to identify the approximate time of onset of viraemia. A second quantitative examination of serum samples was attempted to measure the titer of virus in the serum samples (Kirkland et al 1997). In addition, the unfertilized and degenerate embryos were examined for pestivirus.

**Oestrus synchronization and superovulation:** Oestrus synchronization was performed by using syncromate (SMB) implant (Intervet, The Netherlands) containing 2 mg of progestagen norgestomet. After rectal palpation, those cows that had an active corpus luteum, were injected with 500  $\mu\text{g}$  of cloprostenol (Prostaglandin  $\text{F}_{2\alpha}$  analogue) intramuscularly to be prepared for a synchronization programme. Thus, at the time of SMB implant insertion, most cows were in luteal phase based on the findings of rectal palpation. One SMB implant was inserted on the outer surface of the ear of each cow by using the applicator (this was concomitant with intranasal inoculation of the virus in the treatment group).

On day 9 after SMB insertion, the implants were removed and at the same time all cows received 500  $\mu\text{g}$  cloprostenol intramuscularly to have more precise oestrus synchronization. At the time of removing the implants, the animals were tail painted to aid heat detection. The cows were observed for oestrus behaviour from 24 hours after removing the implants and the cloprostenol injection. Using one injection of equine chorionic gonadotrophin (eCG) was considered less stressful to the cows than handling and injecting them eight times, if FSH was used. All cows received 2500 IU eCG intramuscularly on day 10 after the induced oestrus, 4 days after using SMB implant, followed 48 hours later by an injection of 500  $\mu\text{g}$  cloprostenol i.m. to cause regression of the mid-cycle corpora lutea and induce oestrus.

**Artificial insemination:** Prior to AI, the amount of paint loss was scored and recorded. Approximately 48 and 56 hours after removing implants and cloprostenol injection, all animals were artificially inseminated twice (at 8 hours intervals). The frozen thawed semen used for insemination was from a Holstein pestivirus free bull of high fertility. It was examined to be free of pestivirus by seronegative sheep that was inoculated with whole blood from the bull. The sheep was then serially bled to monitor the occurrence of seroconversion. Further, whole blood from the bull was submitted for pestivirus antigen capture ELISA testing (Kirkland et al 1997).

**Ultrasonic examination of ovaries:** Immediately prior to AI, each cow was scanned to visualize the ovarian structures using a B-mode ultrasound machine equipped with a 5 MHz linear array transrectal transducer (SSD, 500 V, Aloka Co., Tokyo, Japan). The number of follicles ( $\geq 10$  mm) on the right and left ovary were determined.

**Embryo collection and evaluation:** On day 9 after AI, a transcervical ova/embryo collection was performed. Shortly before ova/embryo collection, the number of corpora lutea on the ovaries of each

cow was determined via rectal palpation. The flushing medium used was phosphate-buffered saline (PBS) supplemented with 1% fetal calf serum (FCS) and 100 µg streptomycin per milliliter and 20 µg of fungizone. Immediately after each collection, the flushed media was searched to find ova/embryos. They were then identified, counted and evaluated by gross morphological criteria using the classification below (Elsden 1980).

**Embryo culture:** All good quality embryos were held in the culture media at 37 °C prior to culture. Then, the embryos were cultured in Hams-F10 medium (CSL, Commonwealth, Australia) supplemented with 20% fetal calf serum in 35 mm plastic dishes in an atmosphere of 5% CO<sub>2</sub>, 5% O<sub>2</sub>, 90% N<sub>2</sub>. The temperature and relative humidity of incubator were 38.5 °C and 95%, respectively. The embryos were morphologically evaluated 48 h after the commencement of culture and their developmental stages were recorded.

#### Experiment II

Four Jersey cows aged 4-7 years were used in this experiment. Two days prior to commencement of the experiment the cows were blood sampled via coccygeal vein and serum or whole blood submitted for pestivirus serology and virus isolation. Then, two seropositive cows were assigned to the control group and two seronegative non-viremic cows to the infected group. The method and the timing of experimental infection for each cow in the infected group were similar to that described in Experiment I. Then, the cows in either group were treated for synchronization of oestrus and superovulation as previously described (Kafi et al 1997). As the cows were to be slaughtered on day 18 post-inoculation, infection was confirmed by virus isolation from plasma collected on days 4 to 10 post-inoculation. The procedure for virus isolation has been previously described (Kirkland et al 1997). The cows in the control and infected groups were all slaughtered on

day 18 post-inoculation (8 days after superovulatory-induced oestrus). The ovaries of the slaughtered cows were then collected and several longitudinal slices (5-6mm thickness) of tissue from each ovary were placed in 10% buffered formaldehyde. The ovarian slices contained both follicular and luteal structures. The ovarian slices were subsequently embedded in paraffin and 5 µm sections initially stained with haematoxylin and eosin.

**Immunohistochemistry:** Paraffin-embedded sections of the ovaries each cow was immunolabelled according to Swasdipan et al (2001). Briefly, formaldehyde-fixed paraffin-embedded tissues were immunolabeled for bovine pestivirus using the bovine pestivirus-specific monoclonal antibody 15C5. Cytospin preparations of bovine pestivirus-infected and noninfected bovine tracheal cells functioned as positive and negative controls, respectively. Other controls comprised substitution of specific antibodies with nonreactive antibodies (specific for alphaviruses) and omission of reagents.

**Statistical analysis:** The differences in the mean number of ovulatory-sized follicles on day of AI, mean number of corpora lutea on day 7 after AI, mean number of recovered ova/embryos, mean number of fertilised ova and mean number of transferable embryos for each group in Experiment I were compared using a t-test. Fischer exact test was used to statistically analyse the proportions for the results of the embryo culture. All statistical analyses were carried out using SAS programs package (SAS Inc., 1988, Cary, NC, USA). The level of significance was set at  $p < 0.05$ .

## **RESULTS**

**Clinical observations:** During the whole period of the present study, none of the cows showed any clinical signs of disease. Further, no sign of diarrhea, increased nasal or lacrimal discharge, or

other signs related to BVD/MD were not observed following the virus inoculation.

**Experimental infection:** In Experiment I, of 8 cows in the control group, 3 cows were seropositive and 3 cows were identified seronegative before commencing the experiment. Therefore, all these 8 cows were considered eligible for inclusion in the control group based on their serology results. All cows in the treatment group were also diagnosed as seronegative before commencing the experiment based on the results of the GDP test. Of 8 cows in the treatment group, 5 cows became infected (62.5%), as indicated by seroconversion within 19 days. Therefore the data of the cow that did not become infected was excluded from the statistical analyses. The mean time from intranasal inoculation to seroconversion was 23.4 ± 3.4 days (n=5). Of 5 seroconverted cows, three showed seroconversion in the fifteenth day after exposure and two cows had seroconverted by the twenty-ninth day after exposure.

Virus isolation was carried out on the sera samples on the second, fourth, sixth, eighth days after virus inoculation. The virus was isolated from 3 cows on day 8 after inoculation with a peak viraemia of 3 log TCID<sub>50</sub>/ml of serum and the titer of the virus in the 3 remaining cows were not detectable. In addition, no virus was isolated from the frozen unfertilized and degenerate embryos. In Experiment II, the two inoculated cows had a detectable viremia (≥ 10<sup>4</sup> log<sub>10</sub> TCID<sub>50</sub>/ml) between days -4 and -2 prior to day of superovulatory-induced oestrus.

Experiment I

**Superovulatory response:** All cows except two (one in the control and one in the treatment) showed oestrus behaviour at the time of first AI, as indicated by the degree of paint loss (62.5%, n=12). By the second AI on the same day (8 h interval), all cows (100%, n=12) were in heat as

detected by the degree of paint loss and secondary signs of oestrus.

A composite summary of the superovulatory response is given in **Table 1**.

**Table 1.** Comparison of the superovulatory response of the cows infected with pestivirus 9 days prior to AI and the uninfected control group

	Control (n=8)	Infected (n=5) <sup>#</sup>
Follicles* ≥ 1.0mm	17, 1 ± 2, 8 <sup>a</sup>	9, 2 ± 1, 1 <sup>b</sup>
Corpora lutea**	12, 2 ± 2, 8 <sup>c</sup>	2, 1 ± 0, 9 <sup>d</sup>
Recovered ova/emb	3, 0 ± 1, 9	1, 0 ± 1, 0
Fertilised ova	2, 1 ± 1, 0	1, 0 ± 1, 0
Transferable emb	2, 0 ± 1, 2	1, 0 ± 1, 0

\* scanned by ultrasonography on day of oestrus  
 \*\* Counted via rectal palpation # one cow failed to become infected  
 a, b, c, d; Means with different superscripts between columns show a significant difference (p < 0.05).

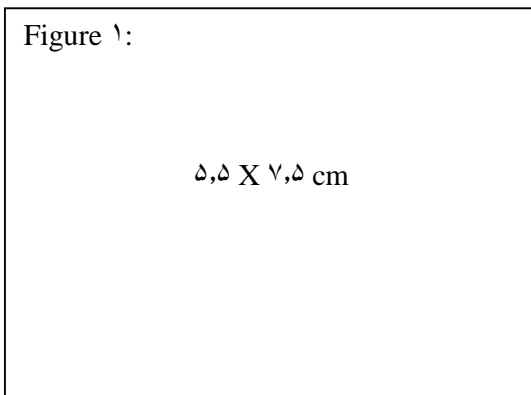
The mean (±SE) number of observed follicles (≥ 1.0 mm) on the day of AI for control and infected groups was 17, 1 ± 2, 8 and 9, 2 ± 1, 1, respectively (p < 0.05). Cows in the control group, had 12 corpora lutea (detected by rectal palpation), with a mean (±SE) number of 12, 2 ± 2, 8 and a range of 1 to 20 corpora lutea, whereas cows in the infected group had a total number of 2 corpora lutea on their ovaries on day 9 after AI, with a mean (±SE) number of 2, 1 ± 0, 9 and a range of 1 to 3 corpora lutea. The total of transferable embryos collected from the control and pestivirus infected cows was 12 and 1, respectively.

**Embryo culture:** Of 12 morphologically normal morula/blastocysts in the control group, 9 (75%) were developed to hatched blastocyst after 48 h. culture while of seven embryos in the infected group, only 1 embryo hatched (14.3%) after 48 h. culture.

Experiment II

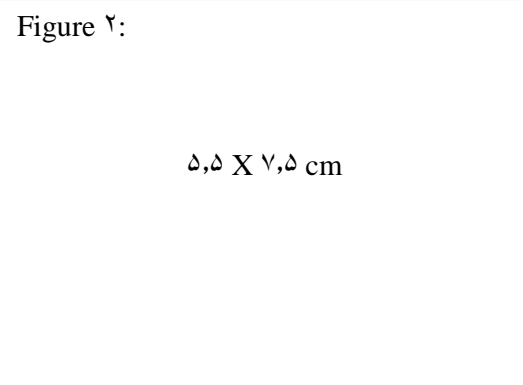
**Histopathological evaluation of the ovaries:** On slaughterhouse inspection (day 8 after superovulatory-induced oestrus), the proportion of grossly normal corpora lutea was significantly (p < 0.05) greater in the control cows (59%; n=44) than

in the infected cows (28% ; n=53). The mean ( $\pm$ SE) number of unovulated follicles  $\geq$  3mm in diameter present on the ovaries of the control cows were  $6,8 \pm 4,9$  compared to  $12,6 \pm 6,4$  for the infected cows. The ovaries of the infected cows contained fewer normally developed corpora lutea (crown  $\geq$  15mm) and a greater number of unovulated follicles, many of which were partially luteinized (Figure 1). Histologically the corpora lutea in the ovaries of the control cows slaughtered on day 14 after oestrus were normal, composed of solid luteal tissue. However, many corpora lutea in the ovaries of infected cows had a hypoplastic or atrophic wall and a comparatively large fluid filled central cavity. Even the relatively normal corpora lutea in the infected cows were smaller with a thinner layer of luteal cells and a larger central cavity compared to the corpora lutea in the ovaries of the control cows. Infiltration by mononuclear cells was evident in the wall of some of the unovulated luteinised follicles but minimal or absent in the others.



**Figure 1:** Cross sectional appearance of the superovulated ovaries of a control (A) and a pestivirus infected cow (B) slaughtered on day 14 after superovulatory induced oestrus. Note the well formed corpora lutea in the control cow's ovaries and the thin walled corpora lutea in the ovaries of the pestivirus infected cow. Also, the diameter of corpora lutea in the infected cows is smaller than in the control cows's ovaries.

**Immunohistochemistry findings:** In sections from the infected cows, bovine pestivirus antigen was detected focally in the granulose cells of apparently intact mature Graafian follicles as well



**Figure 2:** Immunohistochemical demonstration of bovine pestivirus antigen in ovarian follicles. Infected follicles with or without apparent lesions were often found adjacent to uninfected follicles (A). Virus antigen was present in degenerate, necrotic and detached granulosa cells (A, B) as well as in mononuclear cells, mainly monocyte-macrophages, infiltrating the interstitial parenchyma (arrow heads) as well as the follicles (B). Formaldehyde-fixed, paraffin-embedded tissue sections were labeled with a monoclonal antibody specific for nonstructural protein 5 (NS5). The reaction was visualised using AEC-substrate (red label), and counterstained with hematoxyline. N= normal uninfected follicle, I= bovine pestivirus infected follicle. Bar=3.5  $\mu$ m in A and 5.5  $\mu$ m in B.

as more uniformly in granulose cells and infiltrating macrophage in follicles with obvious pathological changes. Antigen positive follicles with or without apparent lesions were often found adjacent to antigen negative follicles (Figure 2). No antigen was detected in any of the sections from the control cow ovaries.

## DISCUSSION

The superovulation procedure used in the present study maximized the number of follicles at risk of pestivirus infection. Data obtained from the present study concerning effectivity of intranasal inoculation are comparable with the findings of Cook *et al* (1990) in that the intranasal inoculation can be considered as one of the effective methods of experimental induction of pestivirus infection. The results of the current study show a significantly higher mean number of the ovulatory

sized-follicles ( $\geq 1.0$  mm in diameter) in un-infected control cows on day of AI comparing to that of the pestivirus-infected cows on the corresponding day. Similarly, a lower mean number of ovulatory-sized follicles was observed in superovulated Holstein heifers when underwent an intranasal infection during the period of final growth of preovulatory follicles compared to uninfected control Holstein heifers (Kafi et al 1997). Further, Grooms et al (1998) reported that the maximum diameter and growth rate of dominant ovulatory follicles were significantly reduced during the two oestrous cycles subsequent to infection of seronegative cattle with a non-cytopathic bovine pestivirus isolate. A lower plasma oestradiol-17 $\beta$  concentration was observed in the period of the first dominant follicle of post-oestrus in pestivirus infected cows (Fray et al 1999). The results of the current study and the above-mentioned studies show that pestivirus infection adversely affects on normal development of preovulatory follicles in Holstein dairy heifers and cows.

A significantly lower number of ova/embryos recovered from the pestivirus infected cows comparing to that of control cows in the current study. This could be attributed to the lower number of ovulatory-sized follicles on day of oestrus in the infected cows. The ovulatory-sized follicles in the infected cows either did not ovulate and then regressed or became luteinised-unovulated follicles by day 9 after AI. This explanation is strengthened considering the results of our previous studies that showed an ovulatory disturbance (Kafi et al 1997) associated with a disturbance in preovulatory LH surge (McGowan et al 2003) in pestivirus infected heifers comparing to that of the uninfected control heifers. The reason for a low number of transferable embryos recovered from the control cows in the current study could be the long half-life of eCG in blood (Boland et al 1991). This has been shown to produce a highly oestrogenic uterine environment which this, in turn, may

adversely affect the quality of developing embryos (Schams et al 1998; Boland et al 1991).

The results of the embryo culture in the present study showed a significantly lower percentage of hatched blastocyst of the embryos collected from pestivirus infected cows compared to that of the embryos collected from the uninfected control cows. Although it has been shown that blastomeres are permissive to pestivirus infection (Vanroose et al 1998), there is no compelling evidence to indicate that blastomeres from in vivo-derived, zona pellucida-intact embryos can be infected with non-cytopathogenic BVDV. Studies in vitro have failed to show conclusively that non-cytopathogenic BVDV compromises embryo development directly (Zurovac et al 1994; Stringfellow et al 2000). Although the number of morula/blastocysts cultured in Experiment I of the present study was not high enough to make a strong conclusion however, the lower hatching rate in the embryos recovered from the pestivirus infected cows compared to that of the uninfected control cows shows that bovine pestivirus may adversely affect the normal development of the embryos. This finding is consistent with those of Bielanski and Dubuc (1995) who reported a lower in vitro developmental competence in the oocytes collected from experimentally pestivirus infected heifers.

The results obtained from the experiment II of the present study could help to explain the lower ovulation rate in pestivirus infected cattle. Pestivirus antigen was detected in granulosa cells and infiltrating macrophages in follicles between 11 and 17 days after inoculation. Interestingly, there were follicles with extensive virus infection accompanied by destruction of granulosa cells next to non-infected and intact follicles. This finding was similarly observed by Brownlie et al (1997) in the ovaries of persistently infected cattle. There is no clear explanation for this peculiar histopathological feature.

In conclusion, the present study demonstrated that pestivirus infection during the period of final growth of preovulatory follicles results in a disturbance in ovulation leading to abnormal development of corpus luteum in multiparous dairy cows. Further, results of embryo culture of the present study showed that superovulated dairy cows infected with pestivirus during the period of final growth of preovulatory follicles may produce embryos that are not developmentally competent.

### Acknowledgements

We would like to thank Professors P.D. Kirkland (Elizabeth Macarthur agricultural Institute) for allowing us to perform serology and virology examinations of the samples and also sincere thanks to Professor Ed Dubovi (Cornell University) for his kindly providing us the monoclonal antibody for the immunohistochemistry.

### References

- Bielanski, A. and Dubuc, C. (۱۹۹۵). In vitro fertilization of ova from cows experimentally infected with a non-cytopathic strain of bovine viral diarrhoea virus. *Animal Reproduction Science* ۳۸: ۲۱۵-۲۲۱.
- Boland, M. P., Goulding, D. and Roche, J.F. (۱۹۹۱). Alternative gonadotrophins for superovulation in cattle. *Theriogenology* ۳۵: ۵-۱۴.
- Brownlie, J. Booth P.J, Stevens D.A. and Collins M.E. (۱۹۹۷). Expression of non-cytopathogenic bovine viral diarrhoea virus (BVDV) in oocytes and follicles of persistently infected cattle. *Veterinary Record* ۱۴۱: ۳۳۵-۳۳۷.
- Cook, L.G., Littlejohns, I.R. and Jessep, T.M. (۱۹۹۰). Induced seroconversion in heifers with a field strain of bovine pestivirus. *Australian Veterinary Journal* ۶۷: ۳۹۳-۳۹۵.
- Elsden R.P. (۱۹۸۰). Bovine embryo transfer. In: Proceedings of Annual Meeting of Society of Theriogenology. Omaha, USA, Pp, ۱۰۱.
- Fray, M.D., Mann, G.E., Clark, M.C. and Charleston, B. (۱۹۹۹). Bovine viral diarrhoea virus: its effects on estradiol, progesterone, and prostaglandin secretion in the cow. *Theriogenology* ۵۱: ۱۵۳۳-۱۵۴۶.
- Fray, M.D., Mann, G.E., Bleach, E.C.L., Knight, P.G. Clark, M.C. and Charleston, B. (۲۰۰۱). Modulation of sex hormone secretion in cows by acute infection with bovine viral diarrhoea virus. *Reproduction* ۱۲۳: ۲۸۱-۲۸۹.
- Grooms, D.L., Brock, K.V., Pate, J.L. and Day, M.L. (۱۹۹۸). Changes in ovarian follicles following acute infection with bovine viral diarrhoea virus. *Theriogenology* ۴۹: ۵۹۵-۶۰۵.
- Kafi, M., McGowan, M.R., Kirkland, P.D. and Jillella, D. (۱۹۹۷). The effect of bovine pestivirus infection on the superovulatory response of Friesian heifers. *Theriogenology* ۴۸: ۹۸۵-۹۹۶.
- Kafi, M. (۱۹۹۸). An Update on current concepts of the epidemiology of bovine pestivirus infection in cattle. *Archives of Razi Institute* ۴۹: ۵۳-۶۴.
- Kafi, M. (۲۰۰۱). Recent findings and current hypotheses on the pathogenesis of low fertility in cattle associated with pestivirus infection around the time of artificial insemination: a review. *J. of Tehran Veterinary Faculty* ۵۶: ۱۱۳-۱۱۷.
- Kirkland, P.D., McGowan, M.R., Mackintosh, S. and Moyle, A. (۱۹۹۷). Insemination of cattle with semen from bulls transiently infected with pestivirus. *Veterinary Record* ۱۴۰: ۱۲۴-۱۲۷.
- McGowan, M. R., Kirkland, P. D., Richards, S. D. and Littlejohns. I.R. (۱۹۹۳a). Increased reproductive losses in cattle infected with bovine pestivirus around the time of insemination. *Veterinary Record* ۱۳۳: ۳۹-۴۳.
- McGowan, M.R., Kirkland, P.D., Rodwell, B. J., Kerr, D. and Carroll, C.L. (۱۹۹۳b). A field



- investigation of the effects of bovine viral diarrhoea virus infection around the time of insemination on the reproductive performance of cattle. *Theriogenology* 39: 443-449.
- McGowan, M.R., Kafi, M., Kirkland, P.D., Kelly, R., Bielefeldt-Ohmann, H. Occhio, M.D. and Jillella, D. (2003). Studies of the pathogenesis of bovine-pestivirus induced ovarian dysfunction in superovulated dairy cattle. *Theriogenology* 59: 1051-1066.
- Rufenacht, J. Rufenacht, Z. P., Schaller, L. Audige, B., Knutti, U. Kopfer and Peterhans E. (2001). The effect of infection with bovine viral diarrhoea virus on the fertility of Swiss dairy cattle. *Theriogenology* 55: 199-210.
- Schams, D., Menzer, E. Schallenberger, B., Hoffman, J. and Hann, R. (1978). Some studies on PMSG and endocrine response after application for superovulation in cattle. In: Control of reproduction in the cow. Pp: 122.
- Sedigi-Nezhad, S. (1996). A survey on BVD-MD in Iran. *Research and Reconstruction* 30: 128-131.
- Stringfellow, D.A., Ridderl, K.P., Galik, P.K., Damiani, P., Bishop, M.D. and Wright, J.C. (2000). Quality control for bovine viral diarrhoea virus-free IVF embryos. *Theriogenology* 53: 827-839.
- Swadipan, S., Bielefeldt-Ohmann, H. Philips, N., Kirkland, P.D. and McGowan, M.R. (2001). Rapid Transplacental Infection with Bovine Pestivirus following Intranasal inoculation of ewes in early pregnancy. *Veterinary Pathology* 38: 275-280.
- Vanroose G, Nauwynck H, Van Soom A, Vanopdenbosch E and de Kruif A. (1998). Replication of cytopathic and non-cytopathic bovine viral diarrhoea virus in zona-pellucida free and zona-intact in vitro-produced bovine embryos and the effects on embryo quality. *Biology of Reproduction* 58: 857-866.
- Virakul, P., Fahning, M. L., Joo, H. S. and Zemianis, R., (1988). Fertility of cows challenged with a cytopathic strain of bovine viral diarrhoea virus during an outbreak of spontaneous infection with a noncytopathic strain. *Theriogenology* 29: 441-449.
- Zurovac, O.V., Stringfellow, D.A., Brock K.V. Riddel, M.G. and Wright, J.C. (1994). Noncytopathic bovine viral diarrhoea virus in a system for in vitro production of bovine embryos. *Theriogenology* 41: 841-853.