

BACILLUS ANTHRACIS ISOLATED FROM ABORTED BOVINE FETUSES*

By

*I. Vand Yoosefi; I. Aarabi; A. H. Esterabadi; A. Ezzi ***

SUMMARY

In the course of a survey to determine the causes of bovine abortion in Iran, four cases of infection with *Bacillus anthracis* were detected with isolation of the micro organism from different tissues of fetuses. Identification of the micro organism has been carried out by means of culture and inoculation into guinea pigs.

INTRODUCTION

During the period of 1977 to 1979 a survey started at the Razi Institute to determine the causes of bovine abortion in Iran, Bacteriological investigations were carried out on specimens collected from 433 aborted bovine fetuses. In this study four Holstein Frisian pregnant cows from two different herds (Yoush farm in Shahriar & Jaff in Khoramdereh) were reported to be ill with, primary signs of fever (rectal temperture 41. 2.C). All four animals recovered when treated with antibiotics (Penicillin G), although they aborted after two weeks. The aborted tissues were examined for microbial contamination that could be regarded as the cause of abortion.

(*) This study was supported in part by the funds of the Ministry of Sciences and Higher Education, under the research project No. 37, 1-6-400.

(**) Razi Institute, P.O. Box 656, Teheran, Iran.

MATERIALS AND METHODS

The fetuses were in different stages of gestation, varying in size from 45 to 70 cm in length. They weighed from 10 to 25 Kg, and they were estimated to be 3-4 months old.

Direct smears were prepared, and cultures were made from stomach contents cotyledons and heart blood, Tissue samples were preserved in 10% Formalin for histopathological study.

Blood agar and serum agar media were used for cultures, incubation was at 37°C. Eight guinea pigs were inoculated subcutaneously, each with 0.2 ml of overnight broth culture.

RESULTS AND DISCUSSION

Pathological changes were more or less similar in all 4 aborted fetuses. At necropsy, blood - tinged gelatinous edema, about 0.5 cm in thickness was observed in subcutaneous tissues all over the body, especially on the abdominal wall and on the shoulders.

Conspicuous congestion and edema were seen in respiratory and gastrointestinal organs. A blood - tinged fluid, rich in protein, accumulated in the plural, pericardial and abdominal cavities.

The spleen was moderately enlarged and contained numerous subcapsular petechial hemorrhagic foci. Similar petechial foci were also observed on the pericardium.

Edema and moderate hyperemia were also observed in the brain and spinal cord. Despite engorgement of the blood vessels, no cellular response or leukocyte infiltration was observed in the tissues (Fig. 1). Numerous disseminated bacterial colonies were noted in the tissues. They were arranged either as short chains, clumps of bacilli or individual bacillus (Fig. 2).

Gray and slightly haemolytic colonies appeared on blood agar medium within 24 hours. Stained smears from the culture medium showed Gram positive bacilli which measured $1 \times 3-4$ microns and appeared as long chains. Spores could be observed as separately located entities in the chains.

All of the eight inoculated guinea pigs died within 48 hours and **Bacillus anthracis** was isolated from different organs. Bacilli capsules were demonstrated in the smears, prepared from blood and spleen of aborted bovine fetuses and guinea pigs, by staining with 1% aqueous solution of polychrom-methylene blue (Fig. 3).

As no other causative agents were found during the investigation, it is quite possible that the **Bacillus anthracis** was responsible for both fever and abortion.

As Gibbons and Hussaini (1974) indicated, probably the fetus becomes infected during the bacteremia phase of the and dam bacilli continue to multiply in the fetus and cause the death of the fetus despite the recovery of their mother after antibiotic treatment.

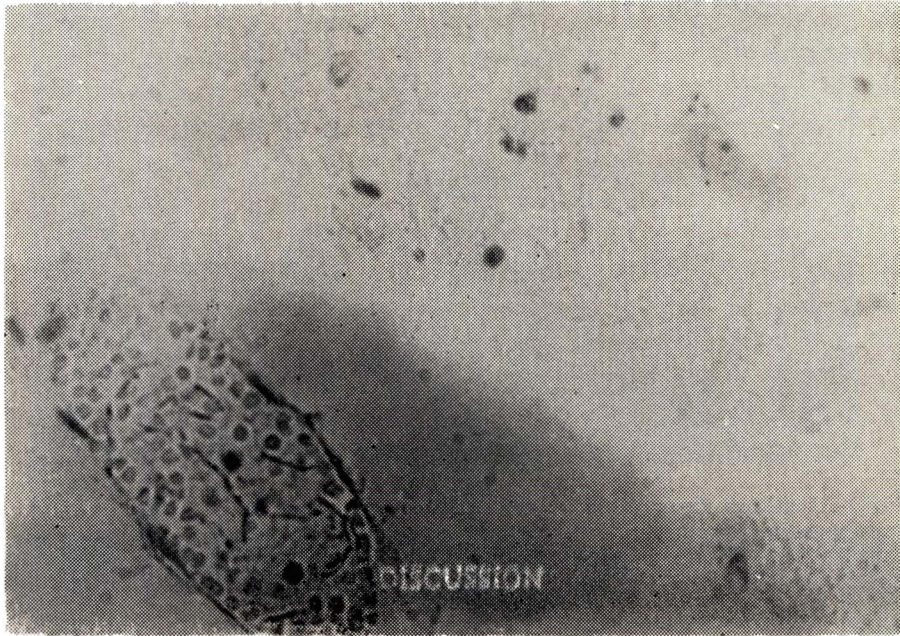


Fig. 1- Despite engorgement of the blood vessels, no cellular response or leukocyte infiltration was observed in the tissues.

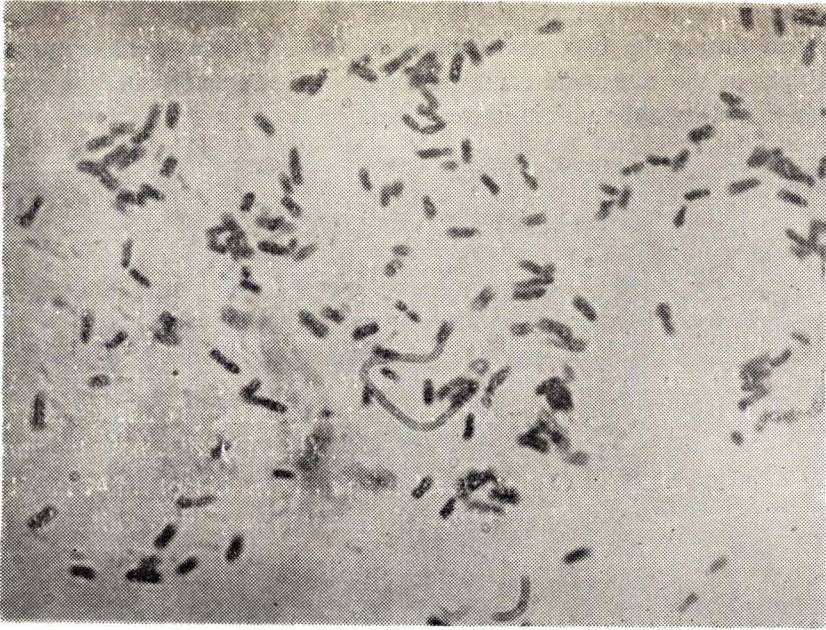

Fig. 2- Numerous disseminated bacterial colonies were noted in the tissues.

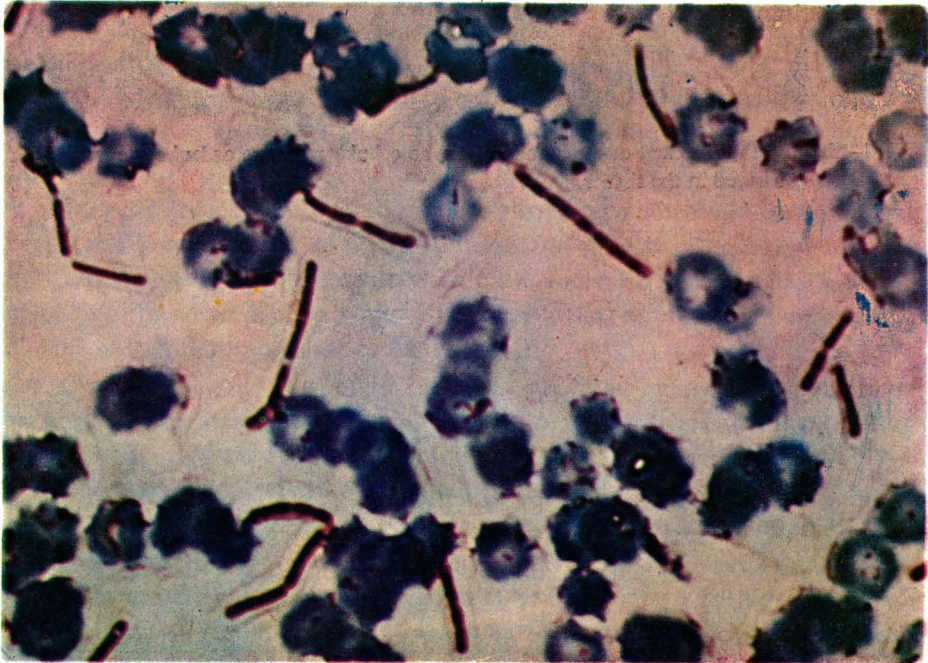


Fig. 3- Bacilli capsules were demonstrated in the smears, prepared from blood of aborted bovine fetuses and guinea pigs.

REFERENCES

Gibbons, D.F., Hussaini, S.N. (1974) Isolation of *Bacillus anthracis* from an aborted bovine fetus. *Nature*. **252**, 612.

Hugh-Jones, M.E., Hussaini, S.N. (1947) An Anthrax outbreak in Berkshire, *Vet. Rec.* **16**, 228–232.