

Original Article

Ultrastructural and Echocardiographic Assessment of Chronic Doxorubicin-Induced Cardiotoxicity in Rats

Babaei^{1,2}, H., Razmaraii^{1,3*}, N., Assadnassab⁴, Gh., Mohajel Nayebi², A., Azarmi², Y.,
Mohammadnejad¹, D., Azami^{1,5}, A.

1. Drug Applied Research Center, Tabriz University of Medical Sciences, Tabriz, Iran

2. School of Pharmacy, Tabriz University of Medical Sciences, Tabriz, Iran

3. Department of Cellular and Molecular Biotechnology, Razi Vaccine and Research Institute, Agricultural Research, Education, and Extension Organization, Karaj, Iran

4. Department of Veterinary Clinical Sciences, Tabriz Branch, Islamic Azad University, Tabriz, Iran

5. Student Research Committee, Tabriz University of Medical Sciences, Tabriz, Iran

Received 16 January 2018; Accepted 13 March 2019

Corresponding Author: nasserrazmaraii@gmail.com

ABSTRACT

Doxorubicin (DOX) is one of the secondary metabolites of *Streptomyces peucetius var. caesius*. It is a common and effective chemotherapeutic agent used for the treatment of different diseases, including lymphoma, leukemia, breast cancer, and solid tumors. However, this medicine causes cardiotoxic side effects, which limit its clinical application. The present study examined the cardiomyopathy induced by DOX via echocardiography and transmission electron microscopy (TEM). The main objective was to evaluate the capacity of echocardiography and TEM as diagnostic tools for DOX-induced cardiotoxicity. Moreover, the correlation between intracellular and functional changes due to cardiotoxicity was assessed in a rat model. Cardiomyopathy was induced in rats by two cumulative doses of DOX. Group I received DOX 12 [i.e., 12 mg/kg, intraperitoneal (IP)] and group II received DOX 15 (i.e., 15 mg/kg, IP) in six equal doses over two weeks. Group III as the control (Ctrl) group received normal saline as a vehicle. Mortality during the study was only observed in the DOX 15 group. The echocardiographic assessments revealed significant changes in ejection fraction, fractional shortening, and heart rate in the groups which received DOX. In addition, severe cardiac arrhythmia was evident in DOX-treated groups. Remarkable adverse effects, such as moderately degenerated cells and inflated mitochondria were observed in the TEM analysis of rat hearts in the DOX groups. The present study indicated that rat models are suitable for investigating DOX-induced cardiomyopathy, especially at the dose of 12 mg/kg. Furthermore, echocardiography and TEM examinations were found to be valuable methods for the determination of cardiotoxicity in rats due to DOX.

Keywords: Cardiomyopathy, Doxorubicin, Echocardiography, Electron microscopy, Rat heart

Étude Ultrastructurale et Échocardiographique de la Cardiotoxicité Chronique Induite par la Doxorubicine chez le Rat

Résumé: La doxorubicine (DOX) est l'un des métabolites secondaires de *Streptomyces peucetius var. caesius*. La DOX est un agent chimiothérapeutique commun et efficace utilisé pour le traitement de différentes maladies, y compris le lymphome, la leucémie, le cancer du sein et les tumeurs solides. Cependant, ce médicament provoque des effets secondaires cardiotoxiques, ce qui limite son application clinique. La présente étude a examiné la cardiomyopathie induite par la DOX par échocardiographie et microscopie électronique à transmission (MET). L'objectif principal était d'évaluer la capacité de l'échocardiographie et de la MET comme outils de diagnostic de la cardiotoxicité induite par la DOX. De plus, la corrélation entre les changements

intracellulaires et fonctionnels causés par la cardiotoxicité de cette substance a été évaluée dans un modèle de rat. La cardiomyopathie a été induite chez le rat par l'injection de deux doses cumulées de DOX. Le groupe I a reçu DOX 12 [12 mg/kg, intrapéritonéal (IP)] et le groupe II a reçu DOX 15 (15 mg/kg, IP) en six doses égales sur deux semaines. Le groupe III (groupe témoin, Ctrl) a reçu une solution saline normale comme véhicule. Au cours de cette étude, la mortalité n'a été observée que dans le groupe DOX 15. L'évaluation échocardiographique a révélé des changements significatifs dans la fraction d'éjection, le raccourcissement fractionnaire et la fréquence cardiaque dans les groupes traités avec la DOX. De plus, ces derniers montraient une arythmie cardiaque sévère évidente. L'analyse MET sur le cœur de rats traités avec la DOX a montré des effets indésirables remarquables comme des cellules modérément dégénérées et des mitochondries gonflées. Cette étude montrait que les modèles de rat conviennent pour étudier la cardiomyopathie induite par la DOX, en particulier à la dose de 12 mg/kg. De plus, l'échocardiographie et les examens MET se sont révélés être des méthodes précieuses pour la détermination de la cardiotoxicité de la DOX chez le rat.

Mots-clés: Cardiomyopathie, Doxorubicine, Échocardiographie, Microscopie électronique, Cœur de rat

INTRODUCTION

Anthracyclines, especially doxorubicin (DOX), are widely used in the chemotherapy regimens of various cancers, including leukemia, lymphoma, and rhabdomyosarcoma. Hematologic, gastrointestinal, dermal, hepatic, and cardiovascular complications could be mentioned among the various side effects of these medications (Octavia et al., 2012). Dose-related cardiovascular side effects are considered as the main DOX complications during long-term administration leading to limited clinical usage of this medicine. Heart damages caused by DOX treatment include cardiomyopathy, heart failure, arrhythmias, pericardial effusion, and sudden death, which can occur several years after DOX prescription (Tokarska-Schlattner et al., 2006). Numerous studies presented the diverse action mechanisms of DOX. An increase in mitochondrial calcium and reactive oxygen species (ROS) results in oxidative stress, DNA interactions, the formation of apoptotic signaling pathways, topoisomerase II inhibition in DNA replication, and prevention from RNA and DNA biosynthesis as the most important mechanisms of DOX activity (Keizer et al., 1990; Octavia et al., 2012). In the final stages of fatal DOX-induced cardiac toxicity, cardiac transplantation is essential (Ichikawa et al., 2014).

Evaluation of left ventricular systolic function by determining ejection fraction (EF) or fractional shortening (FS) is the most commonly used method to assess DOX cardiomyopathy during cancer therapy. The routine techniques for detecting DOX-induced cardiomyopathy are echocardiography and nuclear methods (Migrino et al., 2007). Distinct methods are utilized for the diagnosis of DOX-induced cardiovascular complications, among which echocardiography is a reliable and non-invasive technique (Goldberg et al., 1983). Echocardiography is a valuable instrument for the assessment of myocardial function. The standard echocardiography methods entail evaluating functional parameters, such as heart rate (HR), EF, FS, and ventricular septal thickness. Periodical echocardiography is known as the most cost-effective and safest method, especially in children (Cardinale et al., 2013). Consequently, the present study aimed to evaluate echocardiography and transmission electron microscopy (TEM) as diagnostic tools for the cardiotoxicity induced by DOX. Furthermore, the correlation between intracellular and functional changes related to cardiotoxicity was investigated in a rat model.

MATERIAL AND METHODS

Materials. The necessary materials were purchased from different companies, including DOX from Exir Nano Sina Co. (Iran), glutaraldehyde and resin from ProSciTech (Australia), ketamine hydrochloride from Alfasan (Netherlands), ethanol from Merck (Germany), and osmium tetroxide from TAAB (England).

Animals. Pasteur Institute (Tehran, Iran) provided the male Wistar rats weighting 180-220 g. The rats were treated in accordance with the guidelines of the Regional Ethics Committee of Tabriz University of Medical Sciences. Animals were placed in a well-ventilated room with light-dark cycles of 12 h and were fed a certified rodent diet. The temperature was set at $22\pm 1^\circ\text{C}$ and the animals had free access to food and water.

Protocols:

Animal Treatments. Thirty Wistar rats were divided into three groups through random allocation. The animals in the control group received normal saline intraperitoneally (IP) throughout the study. One of the intervention groups (DOX 12) received a cumulative dose of 12 mg/kg (IP) in six doses of 2 mg/kg/48h over 12 days (Razmaraii et al., 2016a). The other test group (DOX 15) was treated by a cumulative dose of 15 mg/kg (IP) in six doses of 2.5 mg/kg/48 h over 12 days.

All the procedures were carried out during 8-12 a.m. and the ethical considerations were taken into account to guarantee animal welfare and avoid any stressful situations. This study was approved by the Medical Research Ethics Committee of Tabriz University of Medical Sciences.

Echocardiographic Examinations. Transthoracic echocardiographic measurements were performed using iVis 60 EXPERT color Doppler system (CHISON Medical Imaging Co., China) 24 h after the last treatment as described in the literature (Razmaraii et al., 2016a). Briefly, for echocardiographic examination, the rats received a low dose of ketamine (10-20 mg/kg, IP) for optimal sedation. They were positioned in the chest-closed supine position and the soft fixation of animals was provided. The left

ventricular end-systolic diameter (LVESD) and left ventricular end-diastolic diameter (LVEDD) were determined via M-mode tracing following the gentle placement of the transducer in the left parasternal position. Moreover, the percentages of changes in LV cavity size, FS, and EF were calculated as follow (Bu'Lock et al., 1993):

$$\text{Fractional shortening (\%)} = [(LVEDD-LVESD)/LVEDD] \times 100$$

$$\text{Ejection fraction (\%)} = [(LVEDD3-LVESD3)/LVDD3] \times 100 \text{ (Razmaraii et al., 2016a)}$$

An expert veterinary radiologist, who was blinded to the groups, performed all echocardiographic measurements.

Heart Weight, Body Weight, and Heart/Body Weight Ratio. Initial body weight, final body weight, and heart weight were recorded during and/or after the study. Finally, the heart/body weight ratio was calculated and compared with the control group.

TEM Analysis. The ultrastructural assessment was carried out using the TEM method (Leo 906; Leo, Germany), as described in the literature (Mohammadnejad et al., 2012). At the end of the study, the sternum area was opened, the heart was exposed and isolated by cutting all the vessels and connected tissues and then washed with normal saline. For TEM analysis, the LV specimens were cut into pieces of 2×2 mm. The samples were fixed in 2.5% glutaraldehyde (ProSciTech, Australia) for 12 h and washed with 0.2 M phosphate-buffered saline. Osmium tetroxide (TAAB, 2% solution, England) was used post-fixation for 2 h. Following dehydration with graded concentrations of ethanol, clearance, and infiltration, the specimens were embedded in resin (ProSciTech, Australia). Toluidine blue was used to stain the semi-thin sections, which were then observed by optical microscopy. Ultra-thin sections of 80 nm thickness were provided from the selected blocks utilizing an ultramicrotome (Reichert-Jung, Australia). Uranyl acetate and lead citrate were applied to stain the thin

sections followed by an examination by the TEM method.

Statistical Analysis. Data are presented as mean \pm standard deviation for at least six rats per group. Groups were compared by the Student's t-test, analysis of variance (ANOVA), and Tukey's HSD test (if necessary) using the SPSS software version 13. $P < 0.05$ was considered significant.

RESULTS

Bodyweight and Heart/Body Weight Ratio.

Bodyweight, heart weight, and heart/body weight ratio decreased significantly in the DOX 12 and DOX 15 groups ($P < 0.001$), compared to the control group. The results are shown in Table 1 and Figure 1.

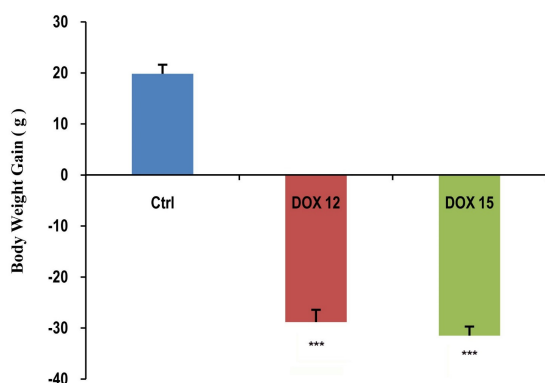


Figure 1. Bodyweight changes in the three groups; Ctrl: control group (normal saline); DOX 12: doxorubicin 12 mg/kg (2 mg/kg/48h, IP); DOX 15: doxorubicin 15 mg/kg (2.5 mg/kg/48h, IP); data are presented as mean \pm standard deviation (n=6) (***) $P < 0.001$ in comparison with the control).

Table 1. Heart weight, the ratio of heart weight to body weight, and mortality in the study groups

Treatment	HW (g)	HW/BW ($\times 10^{-3}$) (g)	Mortality
Ctrl	0.905 \pm 0.017	4.083 \pm 0.0001	0/6
DOX 12	0.54 \pm 0.0191***	2.982 \pm 0.0001***	0/6
DOX 15	0.51 \pm 0.021***	2.81 \pm 0.0001***	3/6

Ctrl: control; DOX 12: doxorubicin (12 mg/kg); DOX 15: doxorubicin (15 mg/kg); HW: heart weight; HW/BW: heart weight to body weight; g: gram; the values are expressed as mean \pm standard deviation (n=6); *** $P < 0.001$ in comparison with control

Echocardiographic Examinations. The echocardiographic measurements were performed to evaluate the changes in cardiac geometry. Cardiac dimensions are shown in Table 2 and echocardiography results of the three groups are displayed in Figure 2. A major reduction in the ventricular septum and posterior walls, in addition to a similar level of wall thinning, were reported in the DOX groups. The DOX 12 treatment appeared to result in the dilation of the left ventricle as evidenced by an increase in the mean LVEDD. The elevation in the dimensions of the left ventricle was associated with larger end-systolic ventricular dimensions, whereas in the DOX 15 group, left ventricular dilation was severe. Although the reduction in the mass was not significantly different between DOX 12 and 15 groups (12 and 15 mg/kg), the LV mass in these groups was lower than the control group. This finding indicates that cardiac growth and development diminished in the DOX groups. The FS and EF of DOX groups demonstrated a 30% decline, in comparison to the control group ($P < 0.01$). In addition, remarkable arrhythmia, ascites, and hepatomegaly were observed in the DOX groups. The HR significantly decreased ($P < 0.05$) in the DOX-treated groups, compared to the control group.

Table 2. Left ventricle echocardiography in the three groups

	Ctrl	DOX 12	DOX 15
LVDD (mm)	6.6 \pm 0.05	6.30 \pm 0.12	6.10 \pm 0.05
LVDS (mm)	4.4 \pm 0.07	4.97 \pm 0.21	4.91 \pm 0.14
FS (%)	33.31 \pm 1.24	21.16 \pm 2.88**	20 \pm 2.1**
EF (%)	70.19 \pm 1.71	50.03 \pm 5.1**	48.2 \pm 4.1**
HR (BPM)	229.9 \pm 11.7	191.15 \pm 10.3*	183.18 \pm 10.21*

TEM Analysis. Ultrastructural studies in the control group revealed the normal and regular structure of myocardial tissues, sarcomere, and mitochondria with plenty of more condense and regular cristae (Figure 3). On the other hand, the treatment of rats with DOX resulted in more severe and heterogeneous subcellular changes in cardiomyocytes, as well as large abnormal mitochondria with a small number of cristae. A clear matrix was shown in the DOX 12 group (12 mg/kg)

(Figure 3). Moreover, some markedly swollen mitochondria were found in the DOX-treated groups. However, these changes were more drastic in the DOX 15 group (15 mg/kg) (Figure 3).

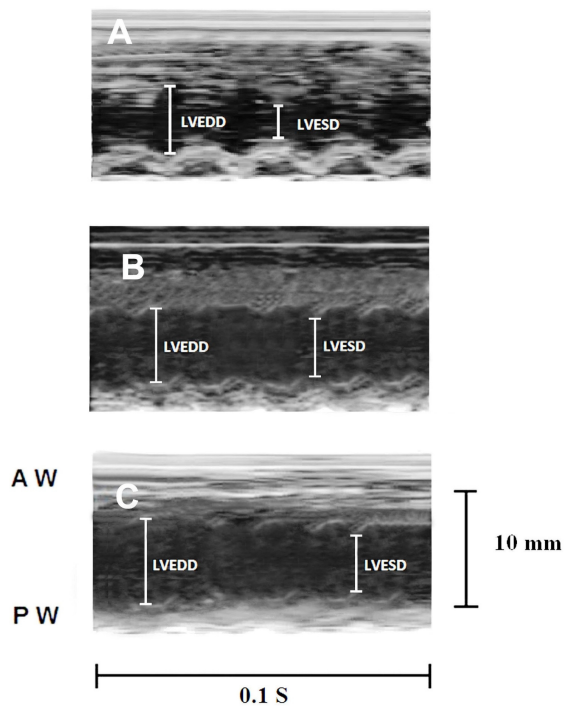


Figure 2. Echocardiography results from the three groups. A: control group (normal saline); B: doxorubicin (12 mg/kg; 2 mg/kg/48h, IP); C: doxorubicin (15 mg/kg; 2.5 mg/kg/48h, IP); AW: anterior wall; PW: posterior wall of the ventricular septum

DISCUSSION

The DOX is the leading compound of a broad family of antineoplastic anthracyclines used in the treatment of leukemia, lymphoma, and breast cancer (Blum and Carter, 1974). Cumulative doses of DOX augment cardiotoxicity and mortality strongly influencing the quality of life in cancer patients due to the side effects (Shan et al., 1996). Although DOX-induced cardiotoxicity mechanisms are not exactly known, the evidence suggests the formation of ROS, cell damage, and lipid peroxidation as the most remarkable outcomes of DOX treatment. In most cases, cardiomyopathy induction is dose-dependent and is

related to the frequency of DOX administration (Takemura and Fujiwara, 2007). In the present study, for determining the incidence of cardiomyopathy, a total cumulative dose (12 or 15 mg/kg) was administered during two weeks as reported previously (Nagi and Mansour, 2000; Razmaraii et al., 2016b). This method of DOX administration is similar to those used in human chemotherapy (Tarr et al., 2015). The echocardiography method is employed as a valuable diagnostic tool to detect DOX-induced cardiac toxicity in cancer patients. Early diagnosis of DOX cardiac toxicity in patients is the most considerable factor to prevent irreversible heart damage and death (Wouters et al., 2005). In the current study, the identification of DOX-induced heart failure in rats was simply performed using echocardiography technique. In addition, the intracellular changes were confirmed by ultrastructural evaluation. Two-dimensional transthoracic echocardiography is used to diagnose DOX-related cardiotoxicity and left ventricular dysfunction confirmed by the decline in EF and FS of the animals in the DOX groups (Razmaraii et al., 2016a). Furthermore, LV diastolic and systolic diameters altered in the DOX groups within two weeks. A significant reduction in the EF and FS measurements of the DOX groups indicated the incidence of the contractile disorder. Similar findings were repeatedly reported in the previous studies, which used the echocardiographic analysis of heart function in DOX-induced myocardial toxicity in human and animal models (Schwarz et al., 1998). Numerous reports demonstrated that the antioxidant compounds could regulate toxic agent-induced stress in rat heart. Therefore, antioxidant agents are recommended for decreasing the cardiac toxicity of DOX and other toxic agents, such as 7, 12-dimethylbenz anthracene. (Talas et al., 2010; Razmaraii et al., 2016b). In the present investigation, we induced cardiomyopathy in rats by DOX administration for two weeks. The DOX-treated groups showed a significant reduction in food intake along with weight loss, in comparison to the control group. Cardiac function

changed significantly as demonstrated by a significant decrease in FS and EF, which is in line with other studies (Koh et al., 2004). Furthermore, a remarkable reduction in body weight, heart weight, and the ratio of

This difference in mortality rate may be attributed to treatment duration, route of DOX administration, animal species, and individual sensitivity. Consequently, we managed to generate DOX-induced




Figure 3. Ultrastructure analysis of the three groups by TEM. Section A: control showing normal rat cardiomyocyte structure with typical mitochondria and sarcomere ($\times 10000$). Section B: DOX 12 (12 mg/kg; 2 mg/kg/48h, IP) showing changes in the morphology of mitochondria and sarcomere; M: mitochondria; S: sarcomere, and C: cristae; mitochondria with few cristae were detected ($\times 10000$). Section C: DOX 15 (15 mg/kg; 2.5 mg/kg/48h, IP) showing remarkable changes in the morphology of mitochondria. M: mitochondria; S: sarcomere, and C: cristae; giant mitochondria with the lowest number of cristae ($\times 10000$). D: DOX 12 (12 mg/kg; 2 mg/kg/48h, IP) deforming sarcomeres and inflated mitochondria ($\times 10000$)

HW/BW, reported by other researchers (Krishnamurthy et al., 2015), was observed in the present study. Forty-eight hours after the final DOX injection, five rats in the DOX 15 group died, whereas no death occurred in the DOX 12 and control groups. In contrast to our results, mortality was reported by other researchers for DOX 12 (Teraoka et al., 2000; Bernard et al., 2011).

cardiomyopathy in rats. Similar ultrastructural results regarding myocardial cell damage have been reported previously (Childs et al., 2002; Lebrecht et al., 2007). Ultrastructural evaluation of myocardium in the DOX-treated groups demonstrated remarkable changes in the morphology of mitochondria and sarcomeres. The increased size of mitochondria, destruction of crista,

and deformation of sarcomeres were significantly different between the DOX and control groups. The mitochondria of the myocardium in the DOX-treated groups were larger in size and fewer in quantity, compared to the animals in the control group.

In the present study, we employed echocardiography and TEM methods as diagnostic tools for DOX-induced cardiotoxicity in a rat model. The DOX (12 mg/kg, IP) administration at an optimal dose produced cardiomyopathy with no mortality in rats. The findings of echocardiography and TEM techniques confirmed the correlation between intracellular and functional changes associated with DOX cardiotoxicity in rats.

Ethics

We hereby declare all ethical standards have been respected in preparation of the submitted article.

Conflict of Interest

Authors of the present study declare no conflicts of interest for this investigation.

Grant Support

The authors would like to extend their gratitude to the Drug Applied Research Center for the financial support of this study with the grant number of 91.71. The findings were extracted from a Ph.D. thesis by N. Razmaraii submitted to the Drug Applied Research Center, Tabriz University of Medical Sciences, Tabriz, Iran.

Authors' Contribution

Study concept and design: Nasser Razmaraii, Hossein Babaei

Acquisition of data: Nasser Razmaraii, Hossein Babaei, Yadollah Azarmi, Gholamreza Asadnasab, Daryosh Mohammadnejad, Ayda Azami

Analysis and interpretation of data: Nasser Razmaraii, Hossein Babaei, Alireza Mohajel Nayebi, Gholamreza Asadnasab, Daryosh Mohammadnejad

Drafting of the manuscript: Nasser Razmaraii

Critical revision of the manuscript for important intellectual content: Nasser Razmaraii, Hossein Babaei
Statistical analysis: Nasser Razmaraii, Hossein Babaei, Daryosh Mohammadnejad, Gholamreza Asadnasab
Administrative, technical, and material support: Hossein Babaei, Gholamreza Asadnasab, Nasser Razmaraii

References

- Bernard, Y., Ribeiro, N., Thuaud, F., Turkeri, G., Dirr, R., Boulberdaa, M., *et al.*, 2011. Flavaglines alleviate doxorubicin cardiotoxicity: implication of Hsp27. *PLoS One* 6, e25302.
- Blum, R.H., Carter, S.K., 1974. Adriamycin. A new anticancer drug with significant clinical activity. *Ann Intern Med* 80, 249-259.
- Bu'Lock, F.A., Gabriel, H.M., Oakhill, A., Mott, M.G., Martin, R.P., 1993. Cardioprotection by ICRF187 against high dose anthracycline toxicity in children with malignant disease. *Br Heart J* 70, 185-188.
- Cardinale, D., Bacchiani, G., Beggiato, M., Colombo, A., Cipolla, C.M., 2013. Strategies to prevent and treat cardiovascular risk in cancer patients. *Semin Oncol* 40, 186-198.
- Childs, A.C., Phaneuf, S.L., Dirks, A.J., Phillips, T., Leeuwenburgh, C., 2002. Doxorubicin treatment in vivo causes cytochrome C release and cardiomyocyte apoptosis, as well as increased mitochondrial efficiency, superoxide dismutase activity, and Bcl-2:Bax ratio. *Cancer Res* 62, 4592-4598.
- Goldberg, S.J., Hutter, J.J., Jr., Feldman, L., Goldberg, S.M., 1983. Two sensitive echocardiographic techniques for detecting doxorubicin toxicity. *Med Pediatr Oncol* 11, 172-177.
- Ichikawa, Y., Ghanefar, M., Bayeva, M., Wu, R., Khechaduri, A., Naga Prasad, S.V., *et al.*, 2014. Cardiotoxicity of doxorubicin is mediated through mitochondrial iron accumulation. *J Clin Invest* 124, 617-630.
- Keizer, H.G., Pinedo, H.M., Schuurhuis, G.J., Joenje, H., 1990. Doxorubicin (adriamycin): a critical review of free radical-dependent mechanisms of cytotoxicity. *Pharmacol Ther* 47, 219-231.
- Koh, E., Nakamura, T., Takahashi, H., 2004. Troponin-T and brain natriuretic peptide as predictors for adriamycin-induced cardiomyopathy in rats. *Circ J* 68, 163-167.

- Krishnamurthy, B., Rani, N., Bharti, S., Golechha, M., Bhatia, J., Nag, T.C., *et al.*, 2015. Febuxostat ameliorates doxorubicin-induced cardiotoxicity in rats. *Chem Biol Interact* 237, 96-103.
- Lebrecht, D., Geist, A., Ketelsen, U.P., Haberstroh, J., Setzer, B., Walker, U.A., 2007. Dexrazoxane prevents doxorubicin-induced long-term cardiotoxicity and protects myocardial mitochondria from genetic and functional lesions in rats. *Br J Pharmacol* 151, 771-778.
- Migrino, R.Q., Zhu, X., Pajewski, N., Brahmabhatt, T., Hoffmann, R., Zhao, M., 2007. Assessment of segmental myocardial viability using regional 2-dimensional strain echocardiography. *J Am Soc Echocardiogr* 20, 342-351.
- Mohammadnejad, D., Abedelahi, A., Soleimani-Rad, J., Mohammadi-Roshandeh, A., Rashtbar, M., Azami, A., 2012. Degenerative effect of Cisplatin on testicular germinal epithelium. *Adv Pharm Bull* 2, 173-177.
- Nagi, M.N., Mansour, M.A., 2000. Protective effect of thymoquinone against doxorubicin-induced cardiotoxicity in rats: a possible mechanism of protection. *Pharmacol Res* 41, 283-289.
- Octavia, Y., Tocchetti, C.G., Gabrielson, K.L., Janssens, S., Crijns, H.J., Moens, A.L., 2012. Doxorubicin-induced cardiomyopathy: from molecular mechanisms to therapeutic strategies. *J Mol Cell Cardiol* 52, 1213-1225.
- Razmaraii, N., Babaei, H., Mohajjel Nayebi, A., Asadnasab, G., Ashrafi Helan, J., Azarmi, Y., 2016a. Cardioprotective Effect of Phenytoin on Doxorubicin-induced Cardiac Toxicity in a Rat Model. *J Cardiovasc Pharmacol* 67, 237-245.
- Razmaraii, N., Babaei, H., Mohajjel Nayebi, A., Assadnassab, G., Ashrafi Helan, J., Azarmi, Y., 2016b. Cardioprotective Effect of Grape Seed Extract on Chronic Doxorubicin-Induced Cardiac Toxicity in Wistar Rats. *Adv Pharm Bull* 6, 423-433.
- Schwarz, E.R., Pollick, C., Dow, J., Patterson, M., Birnbaum, Y., Kloner, R.A., 1998. A small animal model of non-ischemic cardiomyopathy and its evaluation by transthoracic echocardiography. *Cardiovasc Res* 39, 216-223.
- Shan, K., Lincoff, A.M., Young, J.B., 1996. Anthracycline-induced cardiotoxicity. *Ann Intern Med* 125, 47-58.
- Takemura, G., Fujiwara, H., 2007. Doxorubicin-induced cardiomyopathy from the cardiotoxic mechanisms to management. *Prog Cardiovasc Dis* 49, 330-352.
- Talas, Z.S., Ozdemir, I., Gok, Y., Ates, B., Yilmaz, I., 2010. Role of selenium compounds on tyrosine hydroxylase activity, adrenomedullin and total RNA levels in hearts of rats. *Regul Pept* 159, 137-141.
- Tarr, A., Stoebe, S., Tuennemann, J., Baka, Z., Pfeiffer, D., Varga, A., *et al.*, 2015. Early detection of cardiotoxicity by 2D and 3D deformation imaging in patients receiving chemotherapy. *Echo Res Pract* 2, 81-88.
- Teraoka, K., Hirano, M., Yamaguchi, K., Yamashina, A., 2000. Progressive cardiac dysfunction in adriamycin-induced cardiomyopathy rats. *Eur J Heart Fail* 2, 373-378.
- Tokarska-Schlattner, M., Zaugg, M., Zuppinger, C., Wallimann, T., Schlattner, U., 2006. New insights into doxorubicin-induced cardiotoxicity: the critical role of cellular energetics. *J Mol Cell Cardiol* 41, 389-405.
- Wouters, K.A., Kremer, L.C., Miller, T.L., Herman, E.H., Lipshultz, S.E., 2005. Protecting against anthracycline-induced myocardial damage: a review of the most promising strategies. *Br J Haematol* 131, 561-578.