

## ***Bovine Bacillary Hemoglobinuria (Clostridium haemolyticum) in Iran\****

Parviz Ahourai, Mahmoud Ardehali, Abbas Ezzi,  
Mohammad Reza Gholami, Mohsen Moosavi

**Keywords:** *Iran / Clostridium Haemolyticum*

Bacillary hemoglobinuria (redwater disease) in cattle is caused by *Clostridium haemolyticum*. The disease was first described in 1916<sup>6</sup> as an enzootic disease in areas of the western United States. Since then, the disease has been reported from Mexico, Peru, England, Chile, Turkey, Newzealand, and Australia.<sup>5,9-12</sup> The toxicity of the organism for cattle, sheep, rabbits, mice, and guinea pigs has been reported.<sup>2,4-10</sup>

Investigations have been done on the biochemical, toxigenic, and immunologic aspects of the organism.<sup>2,3</sup> For a decade starting in 1978, we investigated cases of icterohemoglobinuria in adult bovinds at the Razi Institute. Tehran-Iran. The great majority of cases were leptospirosis and a few were either

---

\* Reprinted from: *J. Vet. Diagn. Invest.* 2: 143-144 (1990)

abesiosis or postparturient hemoglobinuria.

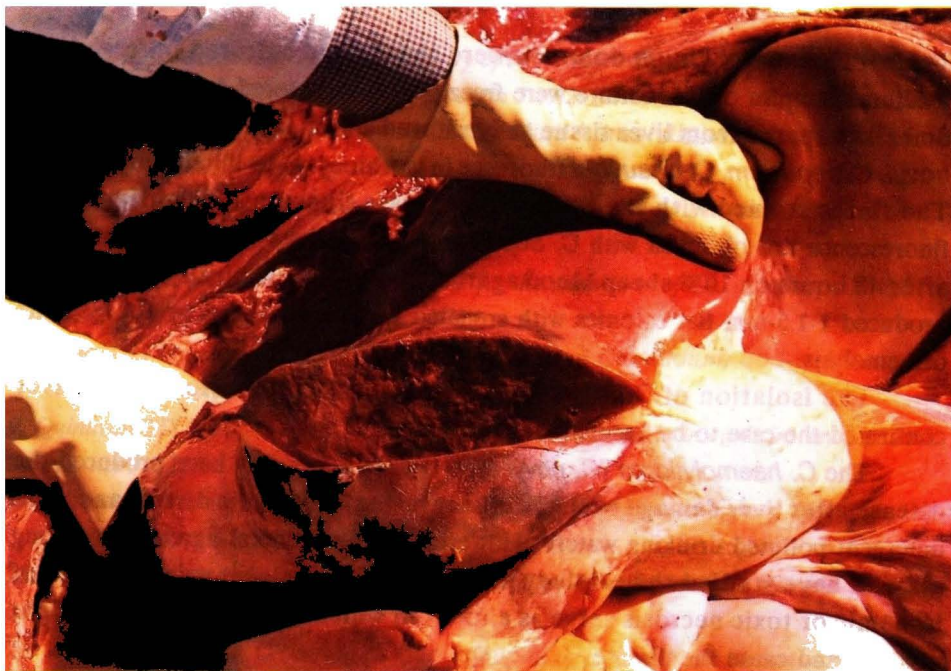
Although *Clostridium oedematiens* type D had been isolated from necrotic liver lesions of a sheep, to the best of our knowledge there is no documented report on either bacillary hemoglobinuria or the isolation of *Clostridium novyi* type D from cattle in Iran, This is the first report on the occurrence of bacillary hemoglobinuria in Iran.

In September 1988, a putrefied carcass of a dairy cow was submitted to the Pathology Department at the Razi Institute. The owner had 30 Holstein-native cross-bred cows on his farm, located 60 Km west of Tehran near the Razi Institute.

According to the owner, the cow had been ill for the previous 48 hours with anorexia and hemoglobinuria. A necropsy was performed. But the internal organs were decomposed. Smears prepared from liver tissue and Gram stained showed many gram-positive rod-shaped bacilli, some with ovoid or elongated subterminal spores.

The 20-month-old cow in late pregnancy appeared normal until 3 days prior to death. The first sign of illness was anorexia followed by hemoglobinuria 48 hours before death. Death was sudden. Another dead cow was submitted 2 weeks later. No other cases have been reported from this farm in the last 8 months.

Postmortem examination of the second cow revealed blood-stained mucus in the nostrils. The perineal region and tail were soiled by dark red urine and feces. Subcutaneous ecchymotic hemorrhages were found on the neck and shoulders. Blood-stained peritoneal fluid was present. Generalized jaundice was noted. The liver was friable, orange brown and showed a large sharply demarcated infarct on the parietal surface of the right lobe. The infarct was approximately 10 x 20 cm in diameter. 10 cm in depth. And contrasted strongly with the pale toxic liver (Fig. 1). The gallbladder was distended with dark bile. Generalized subserosal hemorrhages were noted. The abomasum and small intestine showed swelling accompanied by blood-stained ingesta. The kidneys were pale. Blood-tinged urine was present in the urinary bladder. Hemorrhages were noted in the myocardium and under the endocardium. All other organs appeared normal.



*Figure 1. Large sharply demarcated infarct in the right parietal lobe of the liver (arrow).*

The lesions and histological findings in the liver, kidneys, and cardiac and skeletal muscles conformed to the classical description of the disease. The histological architecture of necrotic foci in the liver was maintained, although there remained very little cellular detail and nuclei of parenchymal cells were generally lysed. In the necrotic areas, sinusoids and central veins were filled with fibrin and ghosts of red blood cells. The necrotic centers blended abruptly into a zone of degenerating parenchyma in which numerous viable neutrophils occluded the sinusoids. Large bacterial rods were seen in necrotic foci. There was a severe acute nephrosis, and the tubular epithelium had undergone varying degrees of degeneration. Myonecrosis, accompanied by hemorrhages and proteinaceous edema fluid, was prominent in skeletal and heart muscle.

Samples were taken immediately during necropsy from a freshly cut area of necrotic liver and were streaked on plates of fresh solidified medium. The plates were then incubated anaerobically in the Gax-Pakjar for 48 hours at 37 C.

Typical *C. haemolyticum* colonies were chosen and cultured in fresh liver medium. Samples of this culture were freeze dried and stored for future studies. Smears prepared from liver tissue and cultured colonies were stained with *C. novyi*, *C. septicum*, *C. chauvoei* fluoresce in isothiocyanate-labeled antibodies. The smear stained with the *C. novyi* conjugate fluoresced brightly, but no fluorescence was observed with *C. septicum* or *C. chauvoei*. The isolate grew after 48 hours on 10% sheep blood agar incubated anaerobically at 37 C. and produced 1-1.5-mm flat colonies with crenated edges surrounded by a large zone of hemolysis.

The isolation of *C. novyi* type D from a necrotic lesion in the liver confirmed the case to be bacillary hemoglobinuria.

The *C. haemolyticum* (*C. novyi* type D)<sup>8</sup> could possibly have produced the disease after liver damage by liver fluke invasion, metabolic disturbances, or detergent-polluted drinking water.<sup>11</sup> However, there is general agreement among all who have studied the etiology of bacillary hemoglobinuria that foci of ischemic or toxic necrosis serve as a focus in which clostridial spores might vegetate and cause the disease.

As we could not determine any predisposing factors except detergent-polluted drinking water, we postulate that a metabolic disturbance might have been a predisposing factor of the disease.

### Sources and Manufacturers

- a. Wellcome Research Laboratory, Backenham, Kent, UK.

### References

1. Ardehali M, Darakhshan H: 1977, first report of infection with *Clostridium oedematis* type D in sheep in Iran. *Arch. Inst. Razi* 29:91-93.
2. Jasmin AM: 1947. Isolation of *Clostridium hemolyticum* from bones. *Am J Vet Res* 28:1569.
3. Lozano EA, Smith LD: 1967. Electrophoretic fractionation of *Clostridium haemolyticum* toxic culture fluids. *Am J Vet Res* 28: 1569.

4. MacFarlane MG: 1950, *The biochemistry of bacterial toxins, the lecithinase activity of Clostridium hemolyticum toxin*. *Biochem J* 47:267-270.
5. Marshall SC: 1959, *The isolation of Clostridium hemolyticum from cattle in New Zealand*. *NZ Vet J* 7:115.
6. Meyer KF: 1916, *Studies to diagnose a fatal disease of cattle in the mountainous regions of California*. *J Am Vet Med Assoc* 48:552-565.
7. Moore WB: 1968, *Solidified media suitable for the cultivation of Cl. novyi type B*. *J Gen Microbiol* 53:415.
8. Oakley CL, Warrack GH: 1959, *The soluble antigens of Clostridium oedematiens type D (Cl. haemolyticum)*. *J pathol Bacteriol* 78:543-555.
9. Quinlivan TD, Wedderburn JF: 1959, *Bacillary haemoglobinuria in cattle in New Zealand*. *NZ Vet J* 7:113.
10. Recards E, Vawter LR: 1945, *Bacillary hemoglobinuria of cattle and sheep*. *Nev Agric Exp Stn Bull* 173.
11. Wellington NAM, Perceval A: 1966, *Bovine bacillary hemoglobinuria in Victoria*. *Aust Vet J* 42:128.
12. Williams BM: 1964, *Clostridium oedematiens infections (black disease and bacillary hemoglobinuria) of cattle in mid-Wales*. *Vet Rec* 76:591.