

Short Communication

Isolation of *Ornithobacterium rhinotracheale* from the brains of commercial broiler breeder chickens with meningitis and encephalitis

Banani^{*1}, M., Hablolvarid², M.H., Momayez¹, R., Nouri¹, A., Ghodsian³, N., Ashtari¹, A., Mirzaei¹.S.G.

1. Department of Avian Bacterial Diseases Research & Diagnosis, Razi Vaccine and Serum Research Institute, Karaj, Iran

2. Department of Pathology & Epidemiology Research & Diagnosis, Razi vaccine and Serum Research Institute, Karaj, Iran

3. Department of Quality Control, Razi vaccine and Serum Research Institute, Karaj, Iran

Received 16 March 2014; accepted 30 August 2014

Author for correspondence. Email: manban42@yahoo.com

ABSTRACT

Ornithobacterium rhinotracheale (ORT) has been identified as one of the respiratory bacterial pathogens in turkey and chicken flocks. Four live birds displaying severe torticollis were submitted from a 13-week-old commercial broiler breeder chicken flock located in Mazandaran province. These birds were suspected to pasteurellosis by the farm veterinarian. No other marked gross lesion except emaciation was seen. Histopathologic examination of the brains showed mild to moderate meningeal vasculitis, perivascular cuffing with lymphocytes, degeneration and necrosis of purkinje cells in the cerebellum. Viral culture of the brains especially for Newcastle disease and avian influenza viruses was negative. Bacterial culture of the brains onto the blood agar revealed pure growth of *Ornithobacterium rhinotracheale*. In this study molecular confirmation of ORT by using of a very specific polymerase chain reaction (PCR) was carried out. Amplification products of a 784 bp region of the 16S rRNA gene of ORT confirmed the bacterium identification. This is the first field case of ORT isolation from the brain of commercial chickens in Iran. These data suggest that this bacterium should be considered in differential diagnosis in cases of avian nervous signs. Further studies are necessary to confirm if ORT is a primary pathogen in such cases.

Keywords: Isolation, *Ornithobacterium rhinotracheale*, brain, broiler breeder, chickens, Iran

INTRODUCTION

Ornithobacterium rhinotracheale (ORT) is a slow growing, pleomorphic, Gram-negative, rod-shaped, bacterium. ORT infection also known as ornithobacteriosis, is a contagious disease of birds that mainly causes respiratory distress (Chin *et al* 2008, van

Empel & Hafez 1999). The severity of clinical signs, duration of the disease, and mortality are extremely variable and are influenced by pathogenicity of the strains, environmental factors such as poor management and the presence of other pathogens (Chin *et al* 2008, Hoerr 2010). ORT infection has played an associated role with other respiratory pathogens. After

a farm is infected, ORT becomes endemic, especially in multiple-age farms and in areas with intensive poultry production. Economic losses related to ORT infections in the poultry industry are estimated in hundreds of millions of dollars annually in the United States (Van Empel 1998, Gornatti Churria *et al* 2012). *O. rhinotracheale* which was named by Vandamme *et al.* (1994) has recently been isolated in many countries of the world and has incriminated as a possible additional causative agent in respiratory disease complex (van Empel & Hafez 1999). The first reported isolation of ORT in Iran was from a broiler and a pullet flock associated with respiratory disorders (Banani *et al* 2000). Some reports from Iran showed that *O. rhinotracheale* infection is a newly known problem in Iran poultry industry and also *O. rhinotracheale* is a relatively common pathogen in respiratory cases (Allymehr 2006, Asadpour *et al* 2008, Banani *et al* 2009, Banani *et al* 2004, Banani *et al* 2003). The major problem of the ORT infection is its important role as a respiratory pathogen and so the primary site for isolating *O. rhinotracheale* is the respiratory tract. However, at least some rare reports have been made of isolation of ORT from joints, heart, brain, and liver and ORT can induce arthritis and nervous signs (Gornatti Churria *et al* 2012, Chin & Charlton 1998). Because of investigators might not be aware of the possibility that *O. rhinotracheale* can cause infections other than the more well-known respiratory ones, diagnoses of ORT infection may be underestimate the true level of infection, as some infections are not related to respiratory tract (Chin & Charlton 1998, Zbikowski *et al* 2013). In general, there are about 4 main causes of torticollis (wry neck) in chickens: Newcastle diseases virus (Avian paramyxoviruses serotype 1), *Pasteurella multocida* (middle ear and cranial bones infection), Marek's disease (MD) virus and Vitamin E/Selenium deficiency (Encephalomalacia usually in less than 5 weeks old chickens) (Pattison *et al* 2008, Swayne *et al* 2013). The present study describes natural torticollis and obvious nervous signs in commercial chickens due

to meningitis and encephalitis which was associated with *O. rhinotracheale* infection in brain.

MATERIALS AND METHODS

Clinical and gross signs and sampling. Four 13-week-old live hens (pullets) suffered from torticollis and opisthotonus (Figure 1) submitted to Razi Institute for determining the cause of the clinical signs. They belonged to a commercial broiler breeder chicken farm located in Mazandaran province. The breed of the flock was Ross and the number of breeding pullets and roosters were 28000 and 4300 respectively. According to the history taking, the sign of torticollis has been started 3 weeks ago in a few number of the flock. Total morbidity was low (less than 0.2%) and they were removed quickly from the flock. According to owner other signs of the flock were arthritis in low morbidity and the flock was otherwise healthy and normal. After humanely euthanizing the birds, emaciation was the only gross lesion observed at necropsy. Samples of brains were collected for bacteriology and virology. Other brain samples were fixed in 10% formalin saline and processed routinely and 5 micron paraffin sections were prepared and stained with hematoxylin and eosin (H&E) and Gallocyanin staining.

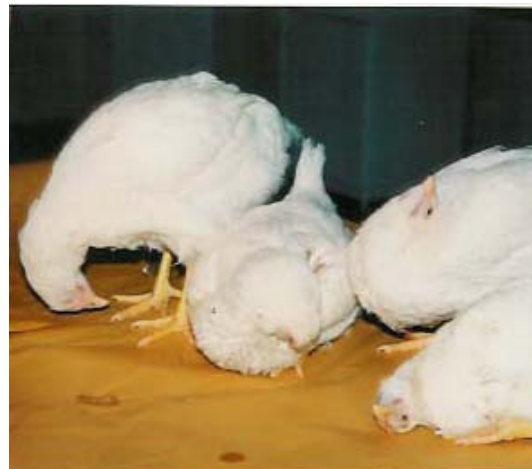

Figure 1. Four 12-week-old commercial broiler breeder chickens with nervous signs including head tremor, torticollis and opisthotonus.

Virus isolation and detection. Brain from chickens with typical signs of torticollis were homogenized to make a 10% w/v suspension in phosphate buffer saline (PBS) pH 7.0-7.2 containing 10,000 IU/ml penicillin, 10,000 µg/ml streptomycin, and 250 IU amphotericin-B/ml. Homogenized materials then were centrifuged at 1000 ×g for 15 minutes. The supernatant fluid was inoculated at 0.2 ml into 10 days old SPF embryonated chicken eggs (Valo, Lohmann, and Cuxhaven, Germany) via chorioallantoic cavity. Inoculated eggs were incubated at 37 °C. The embryos that died within 24 hours post inoculation were discarded. Allantoic fluids were harvested from dead or live embryos during 6 days post inoculation, and then were examined for hemagglutination activity. At least two serial blind passages were made. Harvested allantoic fluids were tested according to the procedure described for HA and HI tests (CEC 1992) using SPF chicken red blood cells (Alexander 2000).

Rapid HA test. Twenty 5 µl of allantoic fluids were mixed with 25 µl of 5% suspension of chicken red blood cells, with a plastic stick on the center of a clean glass slide, while 25 µl of 5% suspension of chicken red blood cells were mixed with 25 µl PBS on the left side of the same slide as negative control and 25 µl of 5% suspension of chicken red blood cells were mixed with 25 µl Newcastle disease virus suspension at right side as positive control and rotated for one minute. Clear and consistent HA was considered as the positive reaction (Alexander 2000).

Bacterial culture. For bacterial isolation, swab of brain samples were inoculated on 5% sheep blood agar (SBA) and MacConky agar plates. Plates were incubated under aerophilic and microaerophilic conditions at 37 °C (Chin & Charlton 1998).

PCR test. DNA of isolated bacterium was extracted and tested in PCR for more confirmation. The PCR was optimized using the primer combination OR16S-F1 and OR16S-R1 (van Empel & Hafez 1999, Van Empel 1998), positive control of ORT bacterium, and *Avibacterium paragallinarum* as negative control. All

samples were prepared for DNA extraction by use of phenol- chloroform method.

DNA extraction. Bacterial Pure colonies of bacterium were suspended in phosphate buffered saline (PBS). 100 µl of harvested bacterial suspension was added to 100 µl lysis buffer and tube was placed in a 56 °C bath for 4 hours. Then 200 µl saturated phenol was added and tube was centrifuged (13000 rpm or 15700 g) for 20 min. Upper phase was transferred to the next tube and equal volume of mixed phenol / chlorophorm (1:1) was added. After centrifugation at 13000 rpm for 20 min the aqueous phase was transferred and added to equal volume of pure chloroform and was centrifuged (13000 rpm) for 5 min. Upper phase mixed with 1/10 volume of acetate sodium and were precipitated with 2 fold volume of cool and absolute ethanol. After final precipitation using by 70% ethanol the DNA was dried and re-suspended in 50 µl TE buffer at 4 °C and used for PCR.

Primers. In this study two primers OR16S- F1: 5'-GAG AAT TAA TTT ACG GAT TAA G-3' and OR16S-R1: 5'-TTC GCT TGG TCT CCG AAG AT -3' which have been designed previously by Van Empel (1998) were used. They flank and amplify a 784bp region of the 16S rRNA gene of ORT.

PCR parameters and optimization. DNA amplifications were carried out in a total volume of 25 µl containing 4 µl DNA, 1 µl of each primer (10picomol), 0.5 µl dNTP mix (10mM) [CinnaGen Inc.], 1.5 µl MgCl₂ (25mM) [CinnaGen Inc.], 2.5 µl PCR buffer (10X) [CinnaGen Inc.], 0.5 µl Taq DNA polymeras (1.25 units) [Cinna Gen Inc.] and 14 µl sterile distilled water. Reaction mixtures were thermocycled 30 times beginning with an initial denaturation step of 7 min at 94 °C. The temperature and time profile of each cycle was as follows: 94 °C for 30sec (Denaturation), 53 °C for 1min (Annealing), and 72 °C for 2min. PCRs were finished with a final extension step of 7 min at 72 °C.

Amplicon electrophoresis. A ten µl aliquot of each PCR products was mixed with 2 µl loading buffer (6X) and separated by electrophoresis (100 volts for 1 hour) in an 1% agarose gel stained with SYBR Safe

(Invitrogen). PCR products were visualized following U.V. transillumination.

RESULTS AND DISCUSSION

Virus isolation. Viral culture of the brains for Newcastle disease virus (NDV), was negative. No other virus such as avian influenza virus (AIV) and infectious bronchitis (IBV) was isolated in this method.

ORT isolation. In blood agar, the isolate grew as small, grey and they did not grow on MacConkey agar. Optimal growth of the isolate was obtained in microaerobic conditions after 48h of incubation at 37 °C, although it was also able to grow in aerobic conditions. The bacterium was Gram-negative, non motile, non spore forming, oxidase-positive, catalase-negative and pleomorphic rod shape. Tests for production of indole and citrate were negative.

PCR results. Definitive molecular identification was achieved by PCR test. A fragment of 784-bp was amplified in positive control and also bacterium colonies (in pure culture) from the brain of broiler breeder pullets, but not in negative control (Figure 2).

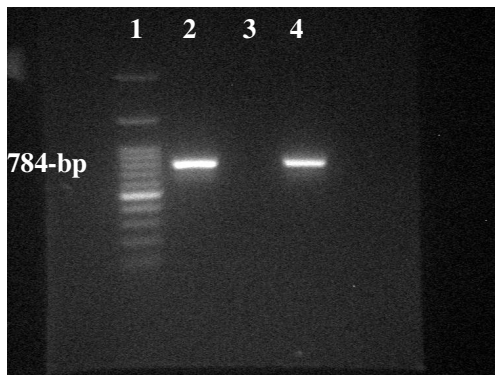


Figure 2. Agarose gel electrophoresis of *O. rhinotracheale* specific PCR products of 784-bp length of the 16S rRNA gene. 100 bp Ladder, Cinaclon (Lane 1), ORT positive control (lane 2), DNA from *Av. paragallinarum* as negative control (lane 3), DNA from isolated bacterium colonies (in pure culture) from the brain of broiler breeder pullets (lane 4).

Histopathology findings. Lesions observed in CNS of the chickens suspected to ORT infection include the following: vessels in the brain parenchyma surrounded by thin cuffs of lymphocytes (Figure 3), mild to

moderate infiltration of mononuclear cells in adventitia of leptomenigeal vessels (Figure 4), most of the purkinje cells in the cerebellum were shrunken, degenerated and necrotic (Figure 5) coagulated cytoplasmic remnants, ghost, of a purkinje cell was seen (Figure 6).

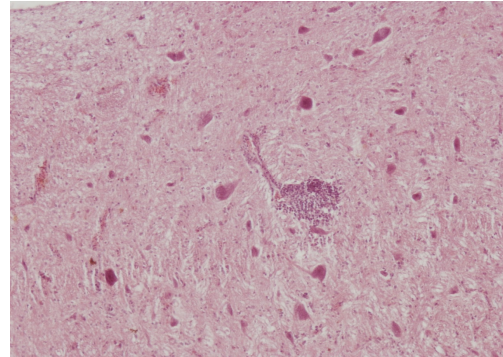


Figure 3. Encephalitis, *Ornithobacterium rhinotracheale* infection, cerebrum, chicken. Infrequently vessels in the brain parenchyma were surrounded by thin cuffs of lymphocytes (H&E x100).

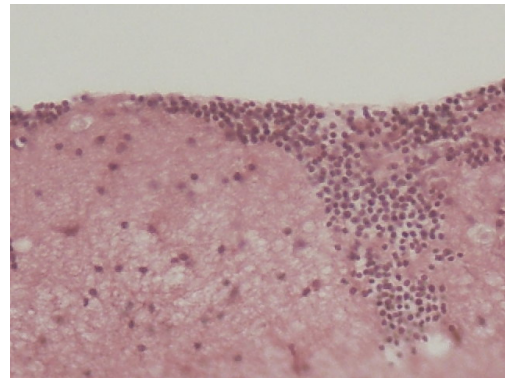


Figure 4. Meningitis, *Ornithobacterium rhinotracheale* infection, cerebrum, chicken. Infiltration of mononuclear cells in adventitia of leptomenigeal vessels are seen (H&E x 200).

The present study for the first time in Iran describes a field case of 13-week-old commercial broiler breeder chickens displaying torticollis and opisthotonus which ORT isolated from brains with meningitis and encephalitis. There appears to be only one other report of ORT infection from chickens associated with a nervous syndrome (Goovaerts *et al* 1998). Moreno *et al.* (2009) isolated *O. rhinotracheale* in pure culture from ear samples, skull and brain stem from farmed

partridges with nervous signs due to otitis and osteomyelitis without respiratory signs.

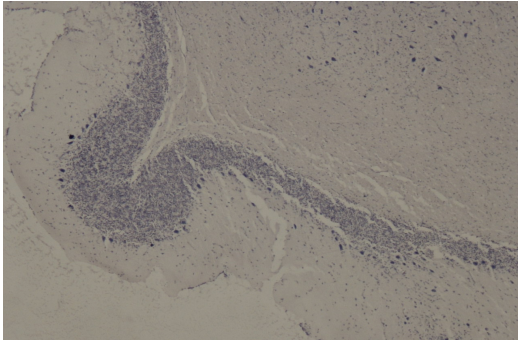


Figure 5. Encephalitis, *Ornithobacterium rhinotracheale* infection, cerebellum, chicken. Degeneration and necrosis of purkinje cells are seen well in this staining method (Gallocyanin x40).

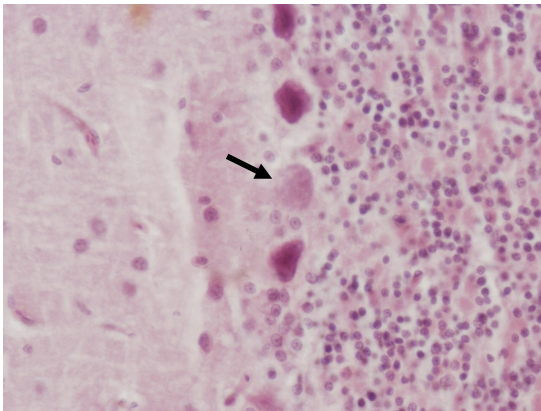


Figure 6. Encephalitis, *Ornithobacterium rhinotracheale* infection, cerebellum, chicken. Coagulated cytoplasmic remnant, ghost, of a purkinje cell is seen (Arrow) (H&E x400).

Although at least in two other reports ORT is considered as a primary respiratory pathogen in chickens (van Veen *et al* 2000; Pan *et al* 2012), the role of ORT as a primary respiratory pathogen has been questioned because it is frequently isolated together with other pathogens such as *E. coli* or *P. multocida* and can be aggravated by previous viral infections (van Empel & Hafez 1999, Gornatti Churria *et al* 2012, De Rosa *et al* 1996). In the present study no ND or AI viruses were isolated. But other virus participation such as avian metapneumovirus (APMV), could not completely be ruled out. In this study no other bacterial

pathogens like *E. coli* or *P. multocida* were isolated and ORT was isolated in pure culture. The most outstanding findings in histopathologic lesions of the brain in present study were perivascular cuffing with lymphocytes, degeneration and necrosis of purkinje cells and meningitis. Moreno *et al.* (2009) in contrast to (Goovaerts *et al* 1998) findings, observed only slight meningitis without significant encephalitis in partridges. Moreno *et al.* (2009) explained the main reason of nervous signs by the severe otitis with cranial bone involvement. They added that the signs were compatible with a vestibular syndrome which may be associated with otitis interna, encephalitis affecting the vestibular nucleus (as in listeriosis) or traumatic lesions in the vestibular apparatus (i.e. fracture of temporal or occipital bones). Otitis is rarely reported in birds (Shivaprasad *et al* 2006). Otitis media is more often described and is mainly associated with *Pasteurella multocida* infection. However, otitis interna in birds is very rare. Only recently Shivaprasad *et al* (2006) reported the first documentation of otitis interna caused by bacteria in an avian species (the turkey). Those authors considered the lesion to be a consequence of a systemic infection by *Salmonella enterica* subsp. *arizonae* and secondary to a meningoencephalitis. The slight meningeal lesions as well as the inner otitis might be considered as an extension of the severe otitis media and cranial osteomyelitis that had spread to all parts of the ears and the meninges (Moreno *et al* 2009). Chin *et al* (1991) isolated *Mycoplasma synoviae* from the brains of 22-week-old commercial meat turkeys displaying severe synovitis and infrequent central nervous system signs, Histological examination of the brains revealed mild-to-severe meningeal vasculitis. In contrast to cases of Chin *et al* (1991) from MS infected turkeys, and Moreno *et al.* (2009) from ORT infected partridges, in the present study lesions were in both meninges and parenchyma, whereas in those reports lesions primarily involved the leptomeninges. This study is more similar to Goovaerts *et al.* (1998) findings in ORT infected chickens. There are some other viral, bacterial, fungal or parasite infections that if

they infect the brain can result in meningitis and or encephalitis, and producing torticollis or opisthotonus, but this is fairly uncommon. Some vitamins deficiency and toxins can also cause these nervous signs. These uncommon causes of torticollis and opisthotonus are other serotypes of avian paramyxoviruses (APMV), highly pathogenic avian influenza viruses, Avian metapneumovirus (probably due to virus effects on the ear), Eastern equine encephalitis (EEE) virus (primarily in pheasants), West Nile (WN) virus (primarily in geese), *Salmonella enterica subsp. Arizonae* (*S. arizonae*) and other *Salmonella* serotypes., *Riemerella anatipestifer* (primarily in domestic ducks and geese. *Mycoplasma gallisepticum* (MG) and MS (in turkeys), *Listeria monocytogenes*, *Toxoplasma gondii*, *Aspergillus* and *Dactylaria* (encephalitic or meningoencephalitic aspergillosis or dactylariosis), and vitamin B1 deficiency (Star gazing in chicks), 3,5-dinitro-o-toluamide (or Zoalene that is an anticoccidial drug) and some toxins (Pattison *et al* 2008, Swayne *et al* 2013). Isolation of some other bacteria from brain of birds with torticollis and/or opisthotonus reported in Iran (Banani *et al* 2004, Banani *et al* 2003). Banani *et al.* (2004) isolated *E.coli* from the brain of mature broiler breeder chickens during egg production age. They show clinical signs of swollen head syndrome (SHS) including opisthotonus, low morbidity and mild upper respiratory disorder. Nakamura *et al* (1998) could reproduce swollen head syndrome (SHS) by only using the *E.coli* strains injection but they could not reproduce the disease by APMV (Previously known as turkey rhinotracheitis or TRT virus). They suggested that *E. coli* may play a significant role in the pathogenesis of SHS, but that the significance of TRT virus in the pathogenesis is still to be clarified. It might be concluded that ORT may play similar role in the nervous symptoms, and can produce this syndrome together with other pathogens or even alone. Banani *et al.* (2004) also isolated ORT from subcutaneous of head of broiler breeders and broilers suffered from SHS. In another study Banani *et al.* (2003) isolated *Salmonella* serogroup C1 from brain and liver of

pigeons suffered from nervous signs such as tremor, torticollis and unilateral blindness. Upon the results of this study ORT should be considered in differential diagnosis in the chicken nervous signs cases. Further studies are necessary to confirm if ORT is a primary pathogen in such cases.

Ethics

I hereby declare all ethical standards have been respected in preparation of the article.

Conflict of Interest

Hereby, I declare "no conflict of interest exists" regarding submitted article.

Grant Support

This study was supported by a project of the Razi Institute with the grant No. 2-18-18-86026.

References

- Chin, R.P., M. v.E.P.C., and M. H.H. (2008). Diseases of poultry. 12 ed. Blackwell Publishing Ltd, Oxford, United Kingdom.
- van Empel, P., and Hafez H.M. (1999). Ornithobacterium rhinotracheale: a review. *Avian Pathology* 28:217-227.
- Hoerr, F.J. (2010). Clinical aspects of immunosuppression in poultry. *Avian diseases* 54:2-15.
- Van Empel, P. (1998). Ornithobacterium rhinotracheale, University of Utrecht, Netherlands.
- Gornatti Churria, C.D., A. M.M., Vigo G.B., and Petruccelli M.A. (2012). Ornithobacterium rhinotracheale Infection in Poultry: an Updated Review. *International Journal of Molecular Zoology* 2:23-38.
- Vandamme, P., Segers P., Vancanneyt M., van Hove K., Mutters R., and Hommez J. (1994). Ornithobacterium rhinotracheale gen. nov., sp. nov., isolated from the avian respiratory tract. *International Journal of Systematic Bacteriology* 44:24-37.
- Banani, M., Khaki P., Goodarzi H., Vandyousefi J., and Pourbakhsh S.A. (2000). Isolation and identification of Ornithobacterium rhinotracheale from a broiler and a pullet flock. *Pajouhesh & Sazandegi* 46:106-109.
- Allymehr, M. (2006). Seroprevalence of Ornithobacterium rhinotracheale infection in broiler and broiler breeder chickens in West Azerbaijan Province, Iran. *Journal of*

- veterinary medicine. A, Physiology, pathology, clinical medicine* 53:40-2.
- Asadpour, Y., Bozorgmehrfard M.H., Pourbakhsh S.A., Banani M., and Charkhkar S. (2008). Isolation and identification of *Ornithobacterium rhinotracheale* in broiler breeder flocks of Guilan province, north of Iran. *Pakistan journal of biological sciences : PJBS* 11:1487-91.
- Banani, M., Pourbakhsh S.A., Erami M., Gholamin F., and Fatehmanesh M. (2009). Diagnosis of *Ornithobacterium rhinotracheale* using polymerase chain reaction (PCR). *Journal of Veterinary Research* 64:45-41.
- Banani, M., Pourbakhsh S.A., Khaki P., and Moazeni-Jula G.R. (2004). Isolation and identification of bacterial agents in commercial chickens suffered from swollen head and face. *Iranian Journal of Veterinary Research* 9:49-61.
- Banani, M., Pourbakhsh S.A., Khaki P., and Nikookhesal Gilvayi H. (2003). Serotyping and drug sensitivity of *Salmonellae* isolates from commercial chickens and domestic pigeons submitted to Razi institute. *Pajouhesh & Sazandegi* 59: 91-99.
- Chin, R.P., and Charlton B.R. (1998) A laboratory manual for the isolation and identification of avian pathogens. 4 ed. Blackwell Publishing Ltd, Oxford, United Kingdom.
- Zbikowski, A., Szeleszczuk P., and Binek M. (2013). Tissue tropism of *Ornithobacterium rhinotracheale* in chickens determined by culture and nucleic acid detection. *Polish journal of microbiology / Polskie Towarzystwo Mikrobiologow* 62:205-9.
- Pattison, M., McMullin P.F., Bradbury J.M., and Alexander D.J. (2008). In *Poultry Diseases*. 6 ed. W.B. Saunders Company.
- Swayne, D.E., Glisson J.R., McDougald L.R., Nolan L.K., Suarez D.L., and Nair V.L. (2013) In *Diseases of poultry*. 13 ed. Wiley-Blackwell (Wiley John & Sons, Inc.).
- Alexander, D.J. (2000). Newcastle disease and other avian paramyxoviruses. *Revue scientifique et technique* 19:443-62.
- Goovaerts, D., Vrijenhoek M., and van Empel P.C.M. (1998) Immunohistochemical and bacteriological investigation of the pathogenesis of *Ornithobacterium rhinotracheale* infection in South Africa in chickens with osteitis and encephalitis syndrome, In *Proceedings of the 16th meeting of the European Society of Veterinary Pathology*, Lillehammer, Norway. Pp. 81.
- Moreno, B., Chacon G., Villa A., Fernandez A., Vela A.I., Fernandez-Garayzabal J.F., Ferre S., and Gracia E. (2009). Nervous signs associated with otitis and cranial osteomyelitis and with *Ornithobacterium rhinotracheale* infection in red-legged partridges (*Alectoris rufa*). *Avian pathology* 38:341-7.
- van Veen, L., Gruys E., Frik K., and van Empel P. (2000). Increased condemnation of broilers associated with *Ornithobacterium rhinotracheale*. *The Veterinary record* 147:422-3.
- Pan, Q., Liu A., Zhang F., Ling Y., Ou C., Hou N., and He C. (2012). Co-infection of broilers with *Ornithobacterium rhinotracheale* and H9N2 avian influenza virus. *BMC veterinary research* 8:104.
- De Rosa, M., Droual R., Chin R.P., Shivaprasad H.L., and Walker R.L. (1996). *Ornithobacterium rhinotracheale* infection in turkey breeders. *Avian diseases* 40:865-74.