

Case Report

Concurrent occurrence of adeno like inclusion body hepatitis and cryptosporidiosis in an ostrich

Gholami*, M.R., Momayez, R.

Department of Pathology, Razi Vaccine and Serum Research Institute, Karaj, Iran

Received 26 Aug 2005; accepted 9 Mar 2006

ABSTRACT

Samples of formalin fixed gastrointestinal organs of three month ostrich chicks were submitted to the department of Pathology, Razi Vaccine and Serum Research Institute. Histologically hepatitis and pancreatitis with large eosinophilic intra nuclear inclusion bodies were prominent in hepatic and pancreatic cells. These inclusions were suspected as adenovirus inclusion body hepatitis (IBH) in variety of avian species. On the epithelium of main pancreatic duct large number of cryptosporidium parasites were present.

Keywords: Ostrich, Inclusion, Hepatitis, Pancreatitis, Cryptosporidiosis

INTRODUCTION

Several viral and none viral inclusions are recognized in component of specific disease entities. Intranuclear inclusion can confirm a diagnosis of well describe diseases (Cardona *et al* 1993). Necrotizing pancreatitis with inclusion has been observed as an additional lesion in some field cases of inclusion body hepatitis (IBH) in chickens and guinea fowl (Reece & Pass 1986, Gwen *et al* 1989). Intranucleare inclusion body of liver and pancreas were reported in chickens, turkey, pigeons, budgerigars and molard duck (McFerran 1976, Ramis *et al* 1992, Grimes *et al* 1976, Weissenbock & Fuchs 1995, Goryo *et al* 1988).

Cryptosporidium spp. is coccidian parasites that inhabit the micro villous border of epithelium. These parasites infect a wide range of hosts including mammals, reptile, fish and birds. Avian cryptosporidiosis has been reported in more than 30 species of birds in many countries (Santos *et al* 2005). In avian species they are pathogenic in the respiratory epithelium of chicken (Dhillon *et al* 1981, Itakura *et al* 1985, Randall 1985) turkey (Glisson *et al* 1984), Infection of the avian intestine (Doster *et al* 1979, Itakura *et al* 1985, Tham *et al* 1982) and bursa of fabricus (Fletcher *et al* 1975, Randall 1985).

Currently 14 species of cryptosporidium are officially recognized (Santos *et al* 2005). These parasites localize in the apical cytoplasm of

* Author for correspondence. E-mail: dr_mr_Gholami@yahoo.com

epithelial of the gastrointestinal tract and respiratory epithelium with less frequent involvement of the urinary, biliary and pancreatic epithelium. Infection with this parasite is often benign and self limiting, except in immuno compromised hosts, where it may be responsible for severe diarrhea as well as chronic air way infection (Jardine & Verwoerd 1997).

CASE HISTORY

A three month-old ostrich chick from an ostrich raising farm with clinical signs of diarrhea, rapid weight loss, anorexia and paresis was submitted to the department of Pathology at Razi Vaccine and Serum Research Institute. The bird died before any medical intervention. At necropsy emaciation and gastrointestinal tract hyperemia were seen. The liver and pancreas were slightly enlarged and pale. Samples of liver, pancreas, gizzard, heart, spleen, kidney and intestine were fixed in 10% formalin saline and processed routinely and 6 micron paraffin sections were prepared and stained with hematoxylin and eosin (H&E) and Gimsa methods.

Histopathologically, significant lesions were seen in the liver and pancreas. Hepatitis with focal areas of necrosis and swollen vacuolated hepatocytes, were noted. Inflammatory cells mainly mononuclear cells (lymphocytes and plasma cells) were infiltrated around the focal necrotic areas and large eosinophilic intranuclear inclusion bodies were seen in hepatocytes around necrosis areas (Figure 1). Pancreas acinar cells contain numerous large eosinophilic intranuclear inclusion bodies which completely filled the swollen nuclei and slight inflammatory cells were infiltrated throughout the liver (Figure 2). The main pancreatic ductal epithelium was infested with large number of cryptosporidium. The organisms were round variably basophilic to eosinophilic and various developmental stages were seen (Figures 3 and 4). The periductal interstitium was markedly thickened due to a prominent infiltration of macrophages,

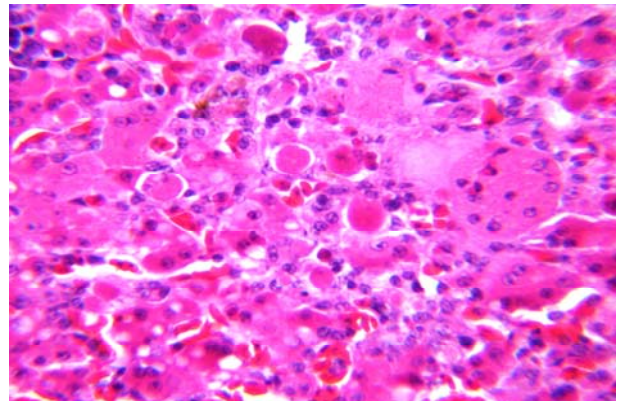


Figure 1. Liver focal necrosis with eosinophilic intra nuclear inclusion bodies in hepatocytes. (H&E), X 400.

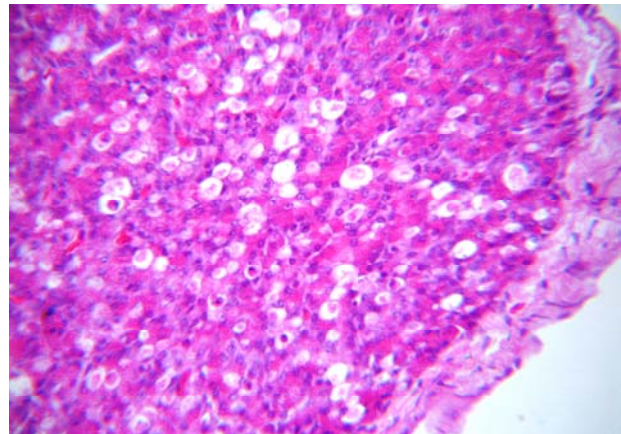


Figure 2. Pancreas with large number eosinophilic intra nuclear inclusion bodies in accinar cells. (H&E), X400.

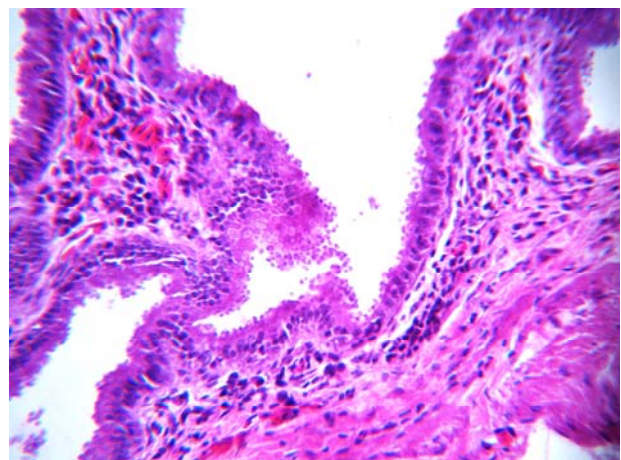


Figure 3. Cryptosporidium on the epithelium and lumen of main pancreatic duct.(H & E), X:400.

plasma cells, lymphocytes and fibroblast. The ductular epithelium generally showed proliferative changes characterized by disorder and densely-packed arrangement of cells and nuclei, giving the epithelium a pseudo-stratified appearance. There was also marked cytoplasmic vacuolation, with some necrosis and sloughing of individual cells.

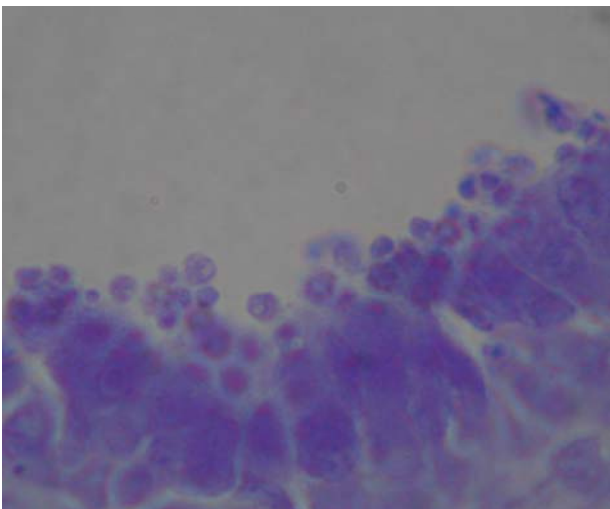


Figure 4. Cryptosporidium on the epithelium of main pancreatic duct. (Gimsa), X1000.

DISCUSSION

Ostrich farming is a developing industry in Iran. Little is known about ostrich pathology. Among viral diseases Newcastle were reported from Iran and other countries. In Italy an adenovirus associated with pancreatitis in four month olds ostrich was found to be pathogenic for guinea-fowl (Gough 1997, Capua 1994). In this case histopathological examinations (light microscopy) adenoviruses like intra-nuclear inclusion bodies were seen in hepatic and pancreatic cells and also cryptosporidium were present in the main pancreatic duct.

In this case, the pathological finding and especially pathognomonic intranuclear inclusion bodies in the liver and pancreas were same as adenovirus

inclusion body hepatitis (IBH) of avian species. Some histopathological lesions such as pancreatitis and inclusion body hepatitis were reported by many authors in birds. Informations and references on inclusion body hepatitis and pancreatitis in ostrich are very rare. In Italy an adenovirus associated with pancreatitis in a 4 month old ostrich was found to be pathogenic for guinea-fowl, histopathologically the birds showed intra-nuclear inclusion bodies in pancreas (Capua 1994). Gough 1997 isolated an adenovirus from ostrich. Adenoviruses are common infectious agents in poultry. Most of the viruses replicate in healthy birds with little or no apparent signs of infection, although they can quickly take on the role of opportunistic pathogens when additional factors, particularly concurrent infections occurred. Many different serotypes of adenoviruses have been associated with naturally occurring outbreaks of inclusion body hepatitis. Some workers have been successful in reproducing liver and pancreatic with intra-nuclear inclusion bodies (McFerran 1976).

Recently cryptosporidium infection has been identified in gastrointestinal tract, bursa of fabricius and cloacae of ostrich chick in association with phallic and cloacae prolapses (Allwright 1993, Bezudenhout 1993, Penrith 1993, Penrith 1994, Santos 2005). The presence of cryptosporidium sp in the faeces of asymptomatic adult ostrich has also been reported in Canada (Gajadhar 1993). As single report noted infection of the intra-lobular pancreatic ductal epithelium with accompanying periductal necrosis in one bird (Allwright 1993) and four, 4 month-old cases of pancreatic cryptosporidiosis in one farmed ostriches in south Africa (Jardine 1997). In this case the formalin fixed sample of intestine was not enough for the searching of parasites in different regions.

Tow official pancreatic cryptosporidiosis in ostrich were reported in the world (South Africa), and there are no any reports in other part of the world. This is the first report of pancreatic cryptosporidiosis in IRAN.

References

- Allwright, D.W. and Wessels, J. (1993). Cryptosporidium species in ostriches. *Veterinary Record* 133: 24.
- Bezuidenhout, A.J., Penrith, M.L. and Burger, W.P. (1993). Prolapses of the phallus and cloaca in the ostrich. *Journal of the South African Veterinary Association* 64: 156-158.
- Capua, I., Richard, E., Gough, P.S., Rossella, L. and Antonio, G. (1994). Isolation of an adenovirus from an ostrich (*Struthio camelus*) causing pancreatitis in experimentally infected guinea fowl (*Numida meleagris*). *Avian Diseases* 38: 642-646.
- Cardona, C.J., Trampel, W.D., Bickford, A.A., Daft, B.M., Droual, R. and Kinde, H. (1993). Intranuclear inclusions of unknown pathogenic significance from diagnostic cases in three avian species. *Avian Diseases* 37: 244-253.
- Dhillon, A.S., Tacker, H.L., Dietzel, A.V. and winterfield, R.W. (1981). Respiratory cryptobroiler chickens. *Avian Diseases* 25: 747-751.
- Doster, A.R., Mahaffey, E.A. and Mc-Clearen, J.R. (1979). Cryptosporidium of red-lord parrots. *Avian Diseases* 23: 654-661.
- Fletcher, O.J., Munnell, J.F. and Page, R.K. (1975). Cryptosporidiosis of the bursa of fabricius of chickens. *Avian Diseases* 19: 630-639.
- Gajadhar, A.A. (1993). Cryptosporidium species in imported ostriches and consideration of possible implication for bird in Canada. *Canadian Veterinary Journal* 34: 115-116.
- Glisson, J.R., Brown, T.P., Brugh, M., Page, R.K., Kleven, S.H., and Davis, R.B. (1984). Sinusitis in turkeys associated with respiratory cryptosporidiosis. *Avian Diseases* 28: 783-790.
- Goryo, M., Ueda, Y., Umemura, T., Haruna, A. and Itakura, C. (1988). Inclusion body hepatitis due to adenovirus in pigeons. *Avian Pathology* 17: 391-401.
- Gough, R.E., Drury, S.E., Capua, I., Courtenay, A.E., Sharp, M.W. and Dick, A.C.K. (1997). Isolation and identification of adenoviruses from ostrich (*Struthio camelus*). *Veterinary Record* 140: 402-403.
- Grimes.T.M., King.D.J., Kleven, S.H. and Fletcher, O.J. (1976). Involvement of a type-8 avian adenovirus in etiology of inclusion body hepatitis. *Avian diseases* 21(1): 26-37.
- Gwen, K.Z., Douglas, W.K. and Sherman, W.J. (1989). Adenoviral pancreatitis in guinea fowl (*Numida meleagris*). *Avian Diseases* 33: 586-589.
- Itakura, C., Goryo, M. and Umemura, T. (1985). Cryptosporidium infection in chickens. *Avian Pathology* 13: 487-499.
- Jardine, J.E. and Verwoerd, D.J. (1997). Pancreatic cryptosporidiosis in ostriches. *Avian Pathology* 26: 665-670.
- McFerran, J.B., McCracken, R.M., Connor, T.J. and Evans, R.T. (1976). Isolation of viruses from clinical outbreaks of inclusion body hepatitis. *Avian Pathology* 5: 315-324.
- Penrith, M. and Burger, W.A. (1993). *Cryptosporidium spp* in an ostrich. *Journal of Sought African Veterinary Association* 64: 60-61.
- Penrith, M., Bezuidenhout, A., Burger, W. and Putterill, J. (1994). Cryptosporidium infection as a cause of prolapses of the phallus and cloaca in ostrich chicks (*struthio camelus*) onderstepoort. *Journal of Veterinary Research* 61: 283-289.
- Randall, C.J. (1985). Cryptosporidiosis of the bursa of Fabricius and trachea in broilers. *Avian Pathology* 11: 95-102.
- Ramis, A.M., Marlasca, M.J., Majo, N. and Ferrer, L. (1992). Inclusion body hepatitis (IBH) in a group of electus parrots (*Electus roratus*). *Avian Pathology* 21: 165-169.
- Reece, R.L. and Pass, D.A. (1986). Inclusion body pancreatitis in ginea fowl (*Numida meleagris*). *Australian Veterinary Journal* 63: 26-27.
- Santos, M.M.A.B., Peiro, J.R. and Meireles, M.W. (2005). Cryptosporidium infection in ostriches (*Struthio Camelus*) in Brazil :Clinical and Molecular studies. *Brazilian Journal of Poultry Science* 7: 113-117.
- Tham, V.L., Kniesberg, S. and Dixon, B.R. (1982). Cryptosporidiosis in quails. *Avian Pathology* 11: 619-626.
- Weissenbock, H and Fuchs, A. (1995). Histological and ultra structural characterization of hepatic intranuclear inclusion bodies in psittacine bird and pigeons. *Avian Pathology* 24: 507-521.