

Short Communication

Coinfection Associated with Naturally Occurring Cryptosporidiosis in Broilers

Banai^{1§}, M., Pourbakhsh, S.A.,¹ Ezzi, A.,² Ardehali, M.³ and Jannati, M.⁴

§: m_banani@rvsri.com

1. Avian Diseases Research & Diagnosis Dept., Razi Vaccine and Serum Research Institute.

P.O.Box 11365-1558, Tehran, Iran

2. Pathology Dept., Razi Institute

3. Anaerobic Bacterial Vaccines Research & Production Dept., Razi Institute

4. Veterinary Faculty, Azad University, Karaj, Iran

Received 6 Jun 2001; accepted 30 Oct 2001

Summary

The clinical and laboratory findings associated with *Cryptosporidium* infection in four broiler flocks were reported. The severity of *Cryptosporidium*-induced disease is greatly compounded by the presence of other pathogens. Tracheal swab culture on blood agar revealed a bacterium, which identified as *Ornithobacterium rhinotracheale* by further biochemical and serological characteristics. This isolate was resistant to enrofloxacin and flumequine, and sensitive to ampicillin and tiamulin. *Escherichia coli* isolated from heart of the carcasses was resistant to all conventional antibiotics. *Eimeria tenella* was also detected in the ceca of some carcasses of this flock. Simultaneous isolation of *C.baileyi*, *Clostridium perfringens* type A, and *E. coli* serogroup O8 in a broiler flock affected by gangrenous dermatitis and serious weight gain loss was also reported.

Key words: *Cryptosporidium*, *Eimeria*, *Escherichia*, *Ornithobacterium*, *Clostridium*

Introduction

Cryptosporidium sp. are small protozoan parasites that infect, grow and reproduce in epithelial cells which line portions of the gastrointestinal (GI), respiratory and urinary tracts of vertebrates (Fayer 1997). In chickens two species of *C.meleagridis* (Slavin

1955) and *C.baileyi* (Current *et al* 1986) are able to induce infection and disease. Fletcher *et al* (1975), for the first time reported cryptosporidia in the bursa of Fabricius (BF). Their histologic examination was showed epithelial hyperplasia and heterophil infiltration in the BF, which associated with the presence of organisms attached to the microvillus border of epithelial cells lining the plicae of the BF. Banani *et al* (1996) reported the isolation and identification of *C.baileyi* in Iran that was the first report of cryptosporidia infection of BF and cloaca in broiler flocks of the country.

Many pathogens have been isolated from birds infected with *Cryptosporidium* species. Although in some cases attempts to find organisms other than *Cryptosporidium* sp. were not successful (Goodwin 1989, Current *et al* 1986, Mason 1986) the severity of *Cryptosporidium*-induced disease is greatly compounded by the presence of other pathogens (Current 1997, Guy *et al* 1988). Failure to properly gain body weight and body weight loss are the most common clinical signs in some infected birds, but in some cases any clinical signs are absent (Goodwin 1989). Many experimental works have confirmed the primary disease potential of *C.baileyi* and the negative effects of avian cryptosporidiosis on growth performance (Blagburn *et al* 1986, Blagburn *et al* 1987, Current 1997). *Ornithobacterium rhinotracheale* (ORT) recently described by Vandamme *et al* (1994) as a new species is a gram-negative, pleomorphic, rod-shaped and nonsporulating bacterium that constitutes a new genus within the rRNA superfamily V. The first reported isolation of ORT in Iran was from a broiler and a pullet flock associated with respiratory disorders (Banani *et al* 2000). The severity of clinical signs and economic losses of confirmed ORT outbreaks have been extremely variable. Various respiratory viruses and bacteria have a trigger effect on the outcome of ORT infection (van Empel & Hafez 1999). There is strong evidence that ORT can be regarded to be a primary pathogen in broilers (van Veen *et al* 2000) and can induce loss of weight in infected birds (Abdul-Aziz 1997). In the present report, we detail the clinical and laboratory findings associated with the isolation of *Cryptosporidium* infection of the BF and cloaca from broiler flocks submitted to Razi Institute.

Materials and Methods

Case history. During February 1999 through February 2000 some live and dead birds from four broiler flocks were submitted to the Avian Diseases Department of Razi Institute and in the course of routine diagnostic procedures cryptosporidia had been isolated from the BF and cloaca. ORT isolation was specifically targeted in these flocks. All the flocks had received live virus vaccination against Newcastle disease (ND) and infectious bursal disease (IBD) and one of them had also received infectious bronchitis (IB) live vaccine. Case (flock) 1, which submitted from Ghazvin province in February 1999 was a 50-day-old broiler flock with retarded growth and diarrhea. Daily mortality at the time of submission was 1%. Case 2 presented from Mazandaran province in July 1999 and was a 46-day-old broiler flock. Some ill birds showed a red-green discoloration in abdominal, thigh and flank skins. The average weight of the flock was 40% below the standard. Case 3 submitted from Ghazvin province in November 1999 and was a 44-day-old broiler flock. This flock suffered from respiratory rales and diarrhea and daily mortality was 1.5%. The average weight of the flock was 43% below the standard weight. Case 4 submitted from Ghazvin province in February 2000 was a 30-day-old broiler flock suffered from depression, reduced feed intake and growth rate, respiratory rales and low daily mortality (2%).

Pathology. Carcasses were completely necropsied at the time of submission. Blood samples of live birds were collected for serological assays. For histopathologic examination different tissues were fixed in 10% buffered formalin and embedded in paraffin blocks. Blocks were cut at 4-7 microns, mounted on glass slides and stained with hematoxylin and eosin (H&E) stain.

Parasitology. Wet smears were prepared from mucosal surface of BF and initial diagnosis of *Cryptosporidium* was carried out under light microscopy. By use of modified Ziehl-Neelsen staining technique (Henricksen & pohlenz 1981, Banani *et al* 1996), routine H&E technique and Sheater's sugar flotation (current 1990, Banani *et al* 1996) diagnosis of the parasite was confirm. The size of oocysts was measured by routine micrometry technique (Banani *et al* 1996). Samples from various parts of intestine and ceca for direct observation of oocyst and schizont of *Eimeria* were taken.

Bacteriology. Tissues were plated on 5% sheep blood agar (SBA) and MacConkey agar, and incubated at 37°C. For selective isolation of ORT, 5µg of gentamicin were added to each ml of SBA media and incubated for 48h under 7.5% CO₂. Biochemical characterization of isolates was performed according to bacteriologic methods. Identification and serotyping of ORT was carried out according to Joubert *et al* (1999) using the standard antisera donor by Dr. Amer Silim (Faculty of Veterinary Medicine, University of Montreal, Canada). Serotyping of *E.coli* was done by use of standard antisera (Mast Diagnostics, Mast Group LTD., Mast House, Derby Road, Bootle, Merseyside L20 1EA, U.K.). Disc diffusion method was used for evaluation of antibiotic susceptibility of the isolates. In one submission suspected to gangrenous dermatitis (GD) subcutaneous tissues were transferred into fresh liver broth tube and incubated anaerobically at 37°C for 24h. Then streaking on SBA plates made fresh culture, and the plates were incubated anaerobically at 37°C for 24h. Biochemical tests have been done for identification of the isolates. In some cases that *Clostridium perfringens* was diagnosed, toxin typing of the isolate was identified by *Cl.perfringens* types A and C antitoxins as described by Sterne and Batty (1973).

Serology. Sera were examined for hemagglutination inhibition (HI) antibodies against NDV and avian influenza virus (AIV) subtype H9N2 by using standard HI test.

Results & Discussion

Necropsy. Postmortem examinations showed cecal hemorrhages and ascites in case 1, stunting and GD in case 2, pericarditis, perihepatitis, visceral gout and stunting in case 3, airsacculitis, pericarditis, and/or unilateral pneumonia in all carcasses, and cecal hemorrhages in 20% of them in case 4.

Parasitology. Various diagnosis procedures showed various stages of *Cryptosporidium* sp. only on mucosal surface of BF and cloaca in all cases. Examination of fresh mucosal scrapings revealed endogenous stages of *Cryptosporidium* sp. in apical portion of the epithelium of the BF and cloaca (Figure 1). Oocysts concentrated by Sheater's sugar flotation and viewed with light

microscopy, appeared as translucent ovoid to spherical bodies containing one to four dark granules (Figure 2). In acid fast staining, oocysts stained red against a green or blue (depending on counterstain) background (Figure 3).

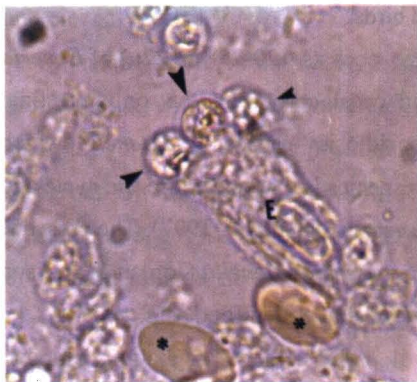

Figure 1. Light microscope photomicrograph of wet smear preparation of mucosal bursa in PBS. Arrows point to developmental stages of the *C.baileyi* in the microvillus border of the epithelial cell (E) lining the plicae of the BF. Two RBCs (stars) are also seen

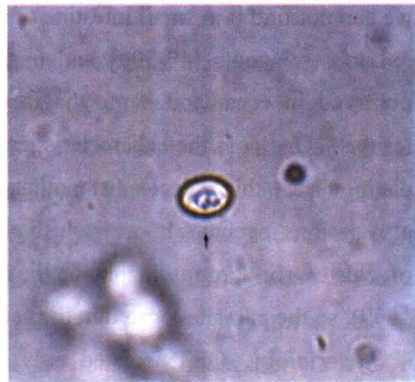
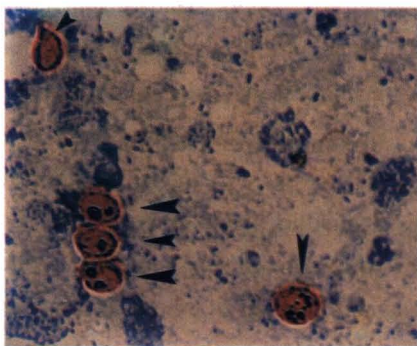
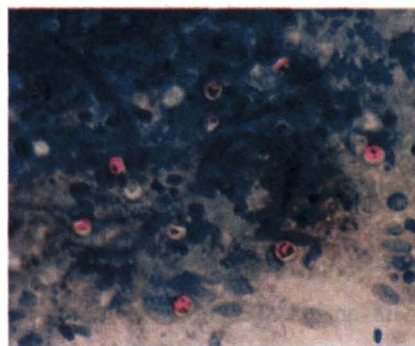


Figure 2. Light microscope photomicrograph of an oocyst of *C.baileyi* in Sheater's sugar flotation method. Note the ovoid shape of the oocyst, oocysts of other species in chickens (*C.meleagridis*) are spherical



a



b

Figure 3. Light microscope photomicrograph of an impression smear of mucosal bursa. In this modified Ziehl-Neelsen staining oocysts of cryptosporidia stain red (arrows) against blue background (a x600, b x1500)

Histopathological sections of the BF revealed cryptosporidia of various sizes attached to the surface of the lining epithelial cells. Based on the parasite localization, hosts, size and shape of the oocysts (Banani *et al* 1996, Current 1997, Fayer 1997) it

was concluded that the parasite appeared to be *C.baileyi*. In this study the average size of oocysts measured by micrometry was $6.5 \times 4.5 \mu$. *C.baileyi* differs in site of development from *C.meleagridis*. The site of infection was only cloaca and BF, and we can not find it in small intestine of infected birds.

Large schizonts ($40-50 \mu$) and medium size oocysts ($20-25 \times 17-22 \mu$) of *Eimeria* observed in ceca, and hemorrhagic ceca and cecal core were the only intestinal lesions. One of the characteristics of coccidiosis caused by *E.tenella* which distinguishes this species from other *Eimeria* species is that, the entire life cycle and also lesions occurs almost exclusively in the ceca (Calnek *et al* 1997). The presence of clusters of large schizonts in the ceca also indicated *E.tenella* (Jordan & Pattison 1999), so the parasite located in the ceca of cases 1 and 4 identified as *E.tenella*.

Bacteriology. ORT isolated only in case 4. After 24h of incubation, pinpoint colonies were apparent on SBA. At 48h, the colonies were 1-2 mm in diameter, circular, grey, and convex with an entire edge. No corresponding growth occurred on MacConkey agar. Isolated organism was gram-negative and highly pleomorphic rods, catalase negative, oxidase positive and grew poorly on TSI slants with no change in the butt or slant portions of the tube (van Empel & Hafez 1999). Standard anti-serum against ORT confirmed the identification of the bacterium. The isolate was sensitive to ampicillin and tiamulin and resistant to neomycin, enrofloxacin and flumequine. *E.coli* isolated from heart and liver, in cases 3 and 4, and from subcutaneous tissues in case 2. Somatic (O) antigen of the isolate in case 2 was O8. *E.coli* isolated in case 4 was resistant to enrofloxacin, flumequine, ampicillin, tiamulin, neomycin and tetracycline. Anaerobic culture on blood agar revealed low convex, semiopaque, and with an entire margin colonies. An inner and narrow zones of β -hemolysis and an outer zone of α -hemolysis due to alpha toxin surrounded the colonies. Fermentation tests, according to the table given by Smith and Holdeman (1988), showed that the isolate was *Cl.perfringens*. The results of toxin typing proved that it was type A. *Cl.perfringens* type A isolated from subcutaneous tissues in case 2 simultaneously with *E.coli* serogroup O8.

Serology and Pathology. All cases did not show AIV infection subtype H9N2, and only showed vaccination titers of NDV. Histopathologic examinations of various tissues of respiratory and GI tracts showed cryptosporidia infection only in the BF and cloaca.

Upon the results of this study, this is the first report of simultaneous infection of a broiler flock with *Cryptosporidium* sp. of the BF, ORT, *E.tenella* and *E.coli*. This is also the first report of concomitant *C.baileyi*, *Cl.perfringens* type A and *E.coli* serogroup O8 infection in a broiler flock affected by GD and serious weight gain loss. All the pathogens isolated in this study can cause loss of feed intake, and/or reduction of weight gain so the severe weight gain loss of broilers in this study can be due to the complex infection of these pathogens. *Cryptosporidium* sp. infection in Ghazvin and Mazandaran provinces had not reported previously. Khodacaram-Tafti *et al* (1997) and Banani *et al* (1996) reported cryptosporidia of the BF in a chicken (probably a pullet) affected by Marek's disease, and from broilers infected by IBD respectively. In another report all infected birds with cryptosporidia showed chronic respiratory disease (CRD) and poisoning (Noori *et al* 1994). Cryptosporidia infection in poultry was reported from Tehran (Noori *et al* 1994) and Shiraz (Banani *et al* 1996). In those two reports the isolates were identified as *C.meleagridis* and *C.baileyi*, respectively. In two broiler flocks serious weight gain loss was seen. Cloaca and BF cryptosporidiosis in chickens may result in histologic lesions but does not usually result in gross lesions or in overt signs of disease. Several reports suggest, however, that performance of broilers can be adversely affected (Current 1997, Fayer 1997). An unusually high mortality was associated with *C.baileyi* infection in the BF (Gorham 1987), and there were lower pigmentation scores when inoculated birds with cloaca and BF infection, were compared with noninfected control (Blagburn 1987).

C.Baileyi is a primary pathogen and can induce clinical respiratory disease and other pathogens can enhance the severity of *C.baileyi*-induced disease in chickens (Current 1997). Experimental works showed that acute respiratory cryptosporidiosis exerts a significant effect on weight gain, but similar to *E.tenella* in birds those

survive the acute phase of the disease can compensate the growth loss (Blagburn 1987). Because of immunosuppressive agents, the course of infection may last more, and beside that, most cryptosporidia infections in broiler flocks occurs in the last weeks of their life (Banani *et al* 1996, 2000) and may be no time for compensation. Poor growth may induce by *Salmonella* sp. infection or mycotoxicoses and/or nutritional deficiency (Jordan & Pattison 1999). Cases 2 and 3 were apparently *Salmonella*-free and according to the owners feed used for these two flocks were also aflatoxin-free and apparently there was no nutritional deficiency in both diets. We could not rule out the role of some intestinal viruses especially reovirus in the poor growth observed in this report, however, gross and histologic lesions did not show typical signs of infectious stunting syndrome (Jordan & Pattison 1999). Guy *et al* (1988) showed that weight gain of chickens orally inoculated with only reovirus or *C.baileyi* was depressed, and coinfection of these two pathogens enhanced the severity of the weight gain loss. Their work also indicated that coinfection of chickens with reovirus had little effects on oral *C.baileyi* infections, but shedding of both virus and oocysts appeared to be enhanced by some unknown mechanism.

Our current examinations indicate that ORT is an emerging agent with high prevalence in broiler flocks. The previous work did not show high prevalence of cryptosporidia infection in broiler flocks (Banani *et al* 2000). According to the previous experimental works, ORT and *C.baileyi* are primary pathogens that can complicate the poultry diseases and can affect the weight gain of the broiler flocks, so monitoring of these emerging infections in broiler flocks is recommended.

Acknowledgement

We thank M. Mohammad-Taheri, H. Modirrousta, Z. Salahi and S.Z. Mousavi for their technical assistance. This work supported by ministry of Jihad-e-Agriculture grant 79-0430117000-02.

References

Abdul-Aziz, T.A. (1997). *Ornithobacterium rhinotracheale* developing into a serious infection. *World Poultry Misset* 8:47-48.

Banani, M., Dadras, H., Khodacaram-Tafti, A. and Sajjadi, S.M., (1996). Cryptosporidial lesions in broiler chickens suffering from IBD in Shiraz area. *Pajouhesh & Sazandegi* 32:100-104 (In Persian).

Banani, M., Khaki, P., Goodarzi, H., Vandyousefi, J., and Pourbakhsh, S. A. (2000). Isolation and identification of *Ornithobacterium rhinotracheale* from a broiler and a pullet flock. *Pajouhesh & Sazandegi* 46:106-109 (In Persian).

Banani, M., Dadras, H., Moazeni-Jula, G. and Hooshmand-Rad, P. (2000). Serologic incidence of cryptosporidial infection in broiler flocks in Shiraz, Iran. *Archives of Razi Institute* 51:95-102.

Blagburn, B.L., Lindsay, D.S., Hoerr, F.L., Giambone, J.J., and Sundermann, C.A. (1986). Avian cryptosporidiosis: an emerging disease problem. *Poultry Digest* 11:436-440.

Blagburn, B.L., Lindsay, D.S., Giambone, J.J., Sundermann, C.A., and Hoerr, F.J. (1987). Experimental cryptosporidiosis in broiler chickens. *Poultry Science* 66:442-449.

Calnek, B.W., Barnes, H.J., Beard, C.W., McDougald, L.R., and Saif, Y.M. (1997). *Disease of Poultry*. (10th edn.), Pp:131-141, 265-268, 865-883. Iowa State University Press.

Current, W.L. (1997). Cryptosporidiosis. In: B.W. Calnek, H.J. Barnes, C.W. Beard, L.R. McDougald and Y.M. Saif (Eds). *Diseases of Poultry* (10th edn.). Pp:883-890. Iowa State University Press.

Current, W.L. (1990). Techniques and laboratory maintenance of *Cryptosporidium*. In: J.P. Dubey, C.A. Speer, and R. Fayer (Eds). *Cryptosporidiosis of man and animals*. Pp:31-49. Boca Raton FL, CRC Press.

Current, W.L., Upton, S.J., and Haynes, T.B. (1986). The life cycle of *Cryptosporidium baileyi* n. sp. (Avicomplexa, Cryptosporidiidae) infecting chickens. *The Journal of Protozoology* 33:289-296.

Fayer, R. (1997). *Cryptosporidium* and cryptosporidiosis. CRC Press.

Fletcher, O.J., Mannell, J.F., and Page, R.K. (1975). Cryptosporidiosis of bursa of Fabricius of chickens. *Avian Diseases* 19:630-639.

Goodwin, M.A. (1989). Cryptosporidiosis in birds-a review. *Avian Pathology* 18:365-384.

Gorham, S.L., Mallinson, E.T., Snyder, D.B., and Odor, E.M. (1987). Cryptosporidiosis in the bursa of Fabricius - a correlation with mortality rates in broiler chickens. *Avian Pathology* 16:205-211.

Guy, J. S., Levy, M.G., Ley, D.H., Barnes, H.J., and Gerig, T.M. (1988). Interaction of reovirus and *Cryptosporidium baileyi* in experimentally infected chickens. *Avian Diseases* 32:381-390.

Henricksen, S.A., Pohlenz, J.F.L. (1981). Staining of cryptosporidia by a modified Ziehl- Neelsen technique. *Acta Veterinaria Scandinavia* 22:594.

Jordan, F.T.W., Pattison, M. (1999). *Poultry Diseases* (reprinted). Pp:9-24, 63-64, 254-260, 375-388. WB Saunders.

Joubert, P., Higgins, R., Laperle, A., Mikaelian, I., Venne, D., and Silim, A. (1999). Isolation of *Ornithobacterium rhinotracheale* from turkey in Quebec, Canada. *Avian Diseases* 43:622-626.

Khodacaram-Tafti, A., Sohrabi-Haghdoost, I., Bozorgmehri- Fard, M.H., and Nagshineh, R. (1997). A Pathological study (gross and microscopic pathology) of Marek's disease (MD) in some poultry farms of Tehran area. *Journal of the Faculty of Veterinary Medicine, University of Tehran*. 51(1&2):29-47 (In Persian).

Mason, R.W. (1986). Conjunctival cryptosporidiasis in a duck. *Avian Diseases* 30:598-600.

Noori, M., Bozorgmehri-Fard, M.H., and Mosavari, N., (1994). Respiratory and intestinal cryptosporidiosis in commercial chicken in Tehran. *Journal of the Faculty of Veterinary Medicine, University of Tehran*. 49:93-98 (In Persian).

Slavin, D. (1995). *Cryptosporidium meleagridis* (sp. nov.). *Journal of Comparative Pathology* 65:262-266.

Smith, L.D., Holdeman, L.V. (1988). The pathogenic anaerobic bacteria. Pp:109-139. C.C. Thomas Co., Fort Lauderdale, F.L.

Sterne, M., Batty, I. (1973). Pathogenic clostridia, typing of *Clostridium perfringens*. Pp:79-82. Butterworth, London.

Vandamme, P., Segers, P., Vancaneyt, M., van Hover, K., Muttters, R., Hommez, J., Dewirst, F., Paster, B., Kerster, K., Falsen, E., Devrieze, L., Bisgaard, M., Hinz, K-H., and Mannheim, W. (1994). Description of *Ornithobacterium rhinotracheale* gen. Nov. sp. nov. isolated from the avian respiratory tract. *International Journal of Systemic Bacteriologic* 44:24-37.

van Empel, P.C.M., Hafez, H.M. (1999). *Ornithobacterium rhinotracheale*: a review. *Avian Pathology* 28:217-227.

van Veen, L., van Empel, P., and Fabri, T. (2000). *Ornithobacterium rhinotracheale*, a primary pathogen in broilers. *Avian Diseases* 44:896-900.