



Experimental histopathologic study of the lesions induced by serotype 793/B (4/91) infectious bronchitis virus

Mahdavi^{1*}, S., Tavasoly², A., Pourbakhsh¹, S.A., Momayez, R.

1. Razi Vaccine and Serum research institute, Karadj, Iran

2. Faculty of Veterinary Medicine, University of Tehran, Tehran, Iran

Received 07 Aug 2006, accepted 15 Jan 2007

ABSTRACT

The study was conducted to determine the type, frequency and severity of gross, histopathologic changes, effect of route of infection and also, tissue tropism of serotype 793/B (4/91) infectious bronchitis virus. 20 day-old specific pathogen free chicks were inoculated intra-tracheally and intra-orally with 793/B serotype and lesions studied histopathologically at interval up to 10 days post-inoculation (pi). The mortality was 7.5% in the IBV-inoculated groups but not in the controls one. Grossly, a small amount of clear mucus and slight congestion were present in the lumen of the trachea, also congestion observed in the lungs. Swollen and pale kidneys due to IBV infection were slightly severe. At the early stage of infection, the histopathological changes in the lungs, kidneys, intestines, were similar in both groups. So, the route of infection with IBV may affect the incidence of disease is not supported. At the late stage of infection, the changes of kidneys were more severe and characterized by nephritis with formation of lymphoplasmacytic nodules in kidneys and other feature of infection with this serotype on intestine was enteritis of both IBV-inoculated groups.

Keywords: Histopathologic, Infectious bronchitis virus, Serotype 793/B (4/91)

INTRODUCTION

Infectious bronchitis (IB) is one of the most significant highly acute viral respiratory and urogenital diseases of commercial chickens in the world (King *et al* 1991). The disease first was described in the USA by Schalk & Hawn in 1931. IB causes high morbidity in all ages of chickens and high mortality in chicks less than 6 weeks old. The disease also causes reduction of egg production with poor egg quality in layer flocks (Case *et al* 1983, Ca-

vanagh & Naqi 2003). Infectious bronchitis virus (IBV) is classified in the Coronaviridae family, genus Coronavirus with many variants and more than 26 serotypes, (Cavanagh *et al* 1992, Gelb *et al* 1991, Jia *et al* 1995). Infectious bronchitis has been a cause of serious economic problems in poultry industry. The presence of new serotypes of IBV with antigenic, pathogenic differences and their wide and variable tropism to different tissues cause to change vaccine strategies (Gough *et al* 1992).

The first isolation of IBV with antigenic related to Massachusetts (Mass) serotype was reported by Aghakhan *et al* in 1994. Some IBV field isolates

* Author for correspondence E-mail: s-mahdavi@rvsri.ir

suggested the presence of IBV variant were reported by some researchers in Iran (Vasfi Marandi & Bozorgmehri Fard 2000, Seifi Abad Shapouri *et al* 2000). Recently, an Iranian isolate of 793/B (491) serotype of IBV with serious economic losses was reported (Momayez *et al* in 2001, Momayez *et al* 2006). The description of the histopathological changes to be observed by IBV isolates were reported (Riddell *et al* 1987, Chen *et al* 1996). The aim of this study was threefold. Firstly, to describe the histopathological changes of experimental infection of the Iranian 793/B strain in 20 day-old specific pathogens free (SPF) chicks. Secondly, to compare the affectedness of infection route and thirdly, to reveal the tissue tropism and infective virus content in the different tissues that was examined on the site of virus replication.

MATERIALS AND METHODS

Virus. The IR/773/2001 IBV strain of 793/B serotype was used in this study. The virus had been isolated from a commercial broiler flock at 30 days of age in Ardebil province without receiving IB vaccines. Chickens were showing respiratory sign and nephritis were followed by mortality resulting from coli-septicemia. Different organs including trachea, lung, kidney and cecal tonsils were used for the virus isolation. The samples were inoculated via the chorioallantoic cavity of ten 10-day-old specific pathogen free (SPF) embryonated chicken eggs after homogenization and clarification. The harvested chorioallantoic fluid of inoculated eggs showed no hemagglutination (HA), bacteria and fungi by specific test. Following 3 passages in embryonated eggs, the samples caused embryo mortality, dwarfing, stunting and curling of the embryos 5-7 days post-inoculation (PI). Dead embryos also revealed urate in the mesonephros and focal necrosis in the liver (De Wit *et al* 2000, Momayez *et al* 2006). The purity of the virus was confirmed on sera examination of 2-week-old SPF chickens that

had been inoculated with the virus by intramuscularly and intraocular method using haemagglutination inhibition (HI), agar gel precipitation (AGP), seroagglutination and enzyme linked immunosorbent assay (ELISA) tests (Momayez *et al* 2006, European Pharmacopoeia 2005). The inoculum was prepared in 0.01 M phosphate buffer saline (PBS) at a titer of 10^5 EID₅₀/0.1ml.

Chicken. White leghorn SPF chickens (Valo, Lohmann, Cuxhaven, Germany) were used. They were hatched at this institute and each group was housed by isolate. They were provided with food and water ad libitum.

Experimental Design. Eighty 20 day-old SPF chicks were divided into 4 groups. The 4 groups were kept in separate isolated places for prevention of cross contamination between them. Infection was initiated intra-nasally, intra-orally or intra-tracheally on different occasions, but ultimately the intra-tracheal and intra-oral routes were found to be the most suitable for experimental purposes and were adopted as standard. The infected groups (A=20, B=20) were inoculated intra-tracheally (A) and intra-orally (B) with virus (0.3 ml). It seems unnecessary to detail all the procedures taken to ensure that experimental chicks were free from all respiratory infections at the time of experimentation, but every effort was made to attain this end, at the same time control groups of an equal number of chicks (C=20, D=20) kept under the same conditions and were inoculated with 0.3ml of 0.01 M PBS (intra-tracheal and intra-orally). In the four groups, clinical signs were recorded daily for 10 days post-inoculation and five chicks each were killed at 1, 3, 6 and all surviving chicks were killed at 10 days post-inoculation (PI).

Necropsy Procedures. All chicks were killed by dislocation of the neck. Morbid or dead chicks of both sex at 21, 23, 26, and 30 days of age from the four groups were subjected to pathological examination. After post-mortem examination, the

left lung, kidney, caecal tonsil and trachea were removed aseptically (for virus isolation). The caudal aspect of the trachea and right lung from each chick were perfused with neutral-buffered 10% formalin and fixed in situ for 30 minutes before being removed from the chick. The right lungs were perfused and fixed in their entirety for at least 10 hours and were then each cut into three pieces. Samples from the trachea were removed from the upper, middle and lower regions (cut off a vertical and horizontal). The kidneys were removed and were pooled as a single sample. Other tissues were necropsied and examined for the presence of gross lesions in brain, air sac, liver, spleen, proventriculus, gizzard, intestine (duodenum, jejunum, ileum, cecum), heart muscle. These samples were then labeled for each bird separately. Samples were removed and placed in 10% neutral buffered formalin.

Virus isolation. Isolation of virus was attempted by inoculation the samples after preparation via the chorioallantoic cavity of 10 days old SPF embryonated chicken eggs (Alexander *et al* 1977, Gelb *et al* 1998). The Specimens for inoculation were prepared as described (Momayez *et al* 2001, Momayez *et al* 2006). Two blind passages at 48 hours intervals and a third of 7 days were used before embryos were examined for changes. The changes were indicative of IBV infection, namely curling, dwarfing, clubbed down and death. Five embryos were used for each tissue passage. Samples inducing lesions in the first, second, or third passage were given values of 3, 2 and 1, respectively. Negative samples were rated 0. The values for all samples of a given tissue were added to obtain an isolation index. Virus isolations were considered positive when at least one embryo showed typical IBV lesions such as embryo mortality, dwarfing, stunting and curling of the embryos 5-7 days PI. They were considered negative when lesions were not observed after three serial passages.

Histological examination. After fixation, the tissues were routinely processed, dehydrated in methanol, cleared in xylene, embedded in paraffin, and sectioning at 4 to 5 μm on a rotary rocker microtome. After sectioning, the tissues were stained with haematoxylin and eosin (HE). Lesion scores were given mean severity index from five chickens to each trachea examined included: Epithelial deciliation, degeneration, desquamation, necrosis, hyperplasia and decrease of mucus cells, heterophil and lymphoid infiltration. Lesion scores were given to each kidney as well as trachea examined included: Ductotubular dilation, epithelial degeneration, regeneration and heterophil, lymphoid cell infiltration also lymphoplasmacytic nodule and fibroblastic proliferation. Because, no significant changes were detected in other tissues, so the scores were established only for trachea and kidney. Variations to varied degrees from no change, mild, moderate, severe are designated by (-), (+), (+ +) or (+ + +) scores.

RESULTS

Clinical signs. Some chickens of the infected groups showed mild tracheal rales, coughing and gasping at 3 days PI. The signs were less severe by 8 days PI. There was a slight fall in food consumption from the 2nd to the 7th day after PI when the chickens appeared mildly depressed. Whitish-green watery diarrhea was observed in the majority of the chicks and this was particularly noticeable between the 3rd and 8th day PI. Some chicks of the infected groups showed dehydration, ruffled feathers, trembling and in coordination that were noted from 3 to 8 days PI. Three chickens of infected groups died in duration of study. The appetite returned to normal at 10 days PI and almost all signs disappeared after 10 days PI. There were neither clinical signs nor death in the control groups.

Gross findings. Chickens from each group, selected at random, were killed and necropsied as

follows: 5 chickens at 1, 3, 6 and 10 days after infection. The chicks were examined for gross and histological lesions in tissues. In the infected groups, small amount of clear mucus was present in the lumen of the trachea and extrapulmonary bronchi 1st day after infection and this was still evident in an occasional chicken up to the 10th day. Slight hyperaemia and oedema of the tracheal mucosa were observed at 3 days PI (especially to groups that intra-tracheally inoculated). Consolidation of the one or both lungs was seen in a few chicks from the 3rd to 10th day post-infection. Cloudiness of the air sacs was observed from 6th to 10th day PI. The kidneys were enlarged and pale in color that especially observed in intra-orally inoculated from 5 to 10 days PI. Renal changes of this type were also seen in all the chickens which died during the study. Lesions in the respiratory tract of the dead chicks were similar to those seen in chicks sacrificed at the same stage (days) of the disease. Although IBV has a wide tropism for intestine (Alexander & Gough 1977, Lucio & Fabricant 1990, Ambali & Jones 1990, Ambali 1992), but no gross changes have been induced by the virus in this study. Also, IBV has been isolated from a variety of other tissues such as liver (Alexander & Gough 1977, Ambali & Jones 1990) and spleen (Otsuki *et al* 1990) it has not been documented to be involved with any functional damage. No gross lesions were observed in brain, gizzard, pro-ventriculus and heart muscle as well as liver and spleen. No comparable gross lesions were observed in control groups (Table 1).

Histopathology of trachea. The progression of lesions in the trachea has been divided into three stages, degenerative, hyperplastic and recovery. At 2 days PI, compared with the tracheal mucosa of control chickens, deciliation and necrosis of mucosal epithelial cells were prominent in chickens of the two groups inoculated by intra-tracheal and intra-orally. Deciliation and desquamation of epithelial and goblet cells occur, following which the virus replication in that cells. So, the epithelial

cells and goblet cells of the mucous layer of trachea were markedly decreased in number. Mild to moderate infiltration of lymphocytes in the lamina propria was in the both infected groups. Occasionally, epithelial cells were seen in the tracheal lumen.

Table 1. Clinical and gross finding in infected chicks and control.

	Infected groups		Control groups
	Intra-orally	Intra-tracheally	
Respiratory signs	20/20(100) ^a	20/20(100)	0/40(0)
Diarrhea	15/20(75)	16/20(80)	0/40(0)
Renal swelling	9/20(45)	9/20(45)	0/40(0)
Tracheal catarrhal exudation	10/20(50)	12/20(60)	0/40(0)
Other changes of IBV infected	8/20(40)	7/20(35)	0/40(0)
Mortality	1/20(5)	2/20(10)	0/40(0)

a = Number of positive chicks/number examined (%)

The submucosa appeared slightly oedematous and lymphocytes and occasional polymorphs were lightly scattered throughout. During the hyperplastic stage, at 3 to 5 days PI, newly formed epithelial cells are observed which usually have no cilia. The appearance of the tracheal mucosa was very similar on the 5th to 10th days PI, but a gradual reduction in the number of infiltrating lymphocytes was evident (Figure 1). The tracheal mucosa in infected groups was covered with squamous or cuboidal epithelium on the surface, accompanied with severe deciliation, degeneration and necrosis. In Table 2 summarizes the histopathological changes in the trachea in IBV inoculated groups.

Histopathology of lung. At 3 days PI, small areas of pneumonia begin observed in the lungs of the both IBV inoculated groups. Pulmonary lesions were limited to primary bronchi. Diffuse peribronchial infiltration of lymphocytes and few heterophils were common in chickens.

Histopathology of kidney. No abnormality was detected in the kidneys until the 3rd day after post-inoculation. At 3 days PI, small changes begin observed in the kidneys. The virus causes degeneration, vacuolation and desquamation of the tubular epithelium. The changes were observed mainly in the collecting ducts (CD), collecting tubules (CT) and distal convoluted tubules (DCT) of the medulla.

Table 2. Histopathology of tracheas of IBV-inoculated chicks.

	Infected groups							
		Intra-orally			Intra-tracheally			
Tracheal lesion	1 ^a	3	6	10	1	3	6	10
Epithelial deciliation	-	+ ^b	++	++	-	+	++	+++
Epithelial degeneration	-	++	+++ ^c	++	-	+	++	++
Epithelial necrosis	-	+	++	++	-	+	+++	++
Epithelial hyperplasia	-	-	+	+++	-	-	+	+++
Decrease of mucus cells	-	+	++	+	-	+	++	+
Lymphoid infiltration	-	+	+	++	-	+	++	+++
Heterophil infiltration	-	-	-	-	-	-	-	-

a=Days post inoculation

b=Mean severity index from five chicks: -, no change, +, mild, ++, moderate, ++++, severe.

c=Mean no of lesions per 5 microscopic fields tissue lesion ($\times 400$) from five chicks: -, no change, +, 1 to 9, ++, 10 to 20, +++ over 20.

A few infiltrations of inflammatory cells in the interstitium were in the both infected groups (Figure 2). Between the 4th or 5th days PI, the changes were more generalized involvement of the kidneys in both cortex and medulla. In addition, single or small groups of tubules and ducts were observed in which the epithelium appeared necrotic and was actively desquamating. Cell degeneration and necrosis were detected in tubules and ducts of medulla and cortex, particularly in CD, CT and DCT in both groups.

Occasionally, lymphocytes with desquamated epithelial cells and macrophages were frequently seen in the lumina of tubules and ducts. Interstitial oedema with infiltration of lymphocytes and macro-

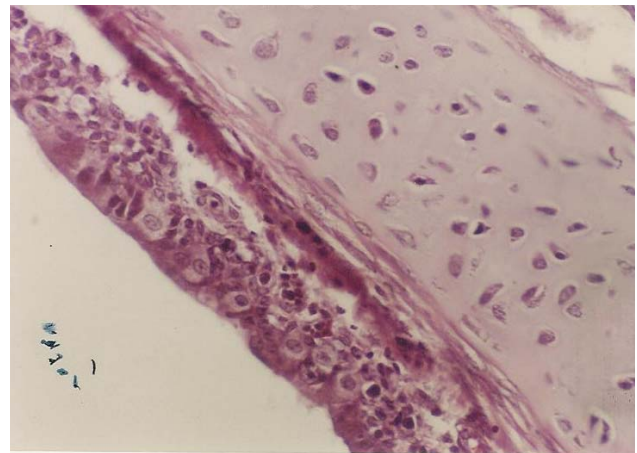


Figure 1. Trachea, chicken. Cross-sectional view of deciliated epithelium. H&E $\times 400$.

phages were observed in the vicinity of degenerating tubules and ducts, as cuffs of 1 to 3 cells in thickness around occasional glomeruli and as extensive cuffs around some cortical blood vessels in both groups. Pathological changes in the glomeruli were not a feature of the disease. Infrequently swelling of the cells of the visceral layer of Bowman's capsule was observed and a few inflammation cells were sometimes seen between the mesangial cells. Infiltration of the interstitial tissue and vicinity of lesions areas by lymphocytes and other inflammation cells was more pronounced on the 7th to 8th days PI. Table-3 summarizes the histopathological changes in the kidney in IBV inoculated groups.

Histopathology of other tissues. No significant histological changes have been seen in the intestine. Only, there was patchy desquamation and necrosis of epithelial cells. No abnormality was detected at any stage of the disease in the brain, liver, spleen, proventriculus, gizzard and heart muscle.

Virus isolation. In this experiment inoculated virus was re-isolated from trachea, lung, kidney and intestine samples by inoculation into the chorioallantoic cavity of ten 10-days old SPF embryonated chicken eggs. The infected embryos showed typical IBV lesions such as embryo mortality, dwarfing, stunting and curling of the embryos 7 days PI.

Table 3. Histopathology of kidneys of IBV–inoculated chicks.

	Infected groups							
	Intra-tracheally				Intra-orally			
Renal lesion	1 ^a	3	6	10	1	3	6	10
Epithelial degeneration	-	+ ^b	++	+++	-	+	++	+++
Epithelial regeneration	-	-	- ^c	++	-	-	-	+
Ductotubular dilation	-	+	++	+++	-	+	+++	+++
Heterophil infiltration	-	-	-	-	-	-	-	-
Lymphoid infiltration	-	+	++	+++	-	+	++	+++
Lymphoplasmacytic nodule	+	+	++	++	+	+	++	+++
Fibroblastic proliferation	-	-	-	+	-	-	+	+

a = Days post–inoculation

b = Mean severity index from five chicks: –, no change, +, mild, ++, moderate, ++++, severe.

c = Mean no of lesions per 5 microscopic fields tissue lesion (×400) from five chicks: –, no change, +, 1 to 14, ++, 15 to 30, +++ over 30.

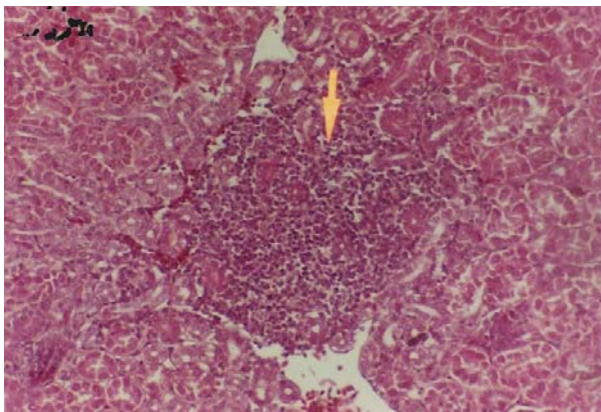


Figure 2. Chickens' kidney. The histopathological changes consisting an inflammatory cell reaction in the interstitium (ducto-tubular interstitial nephritis). H&E ×400.

DISCUSSION

This study was conducted to determine the type, frequency and severity of gross, histopathologic changes, effect of route of infection for serotype 793/B (4/91) infectious bronchitis virus, that recently has been reported in the Iran (Momayez *et al* 2006). In the present study, it is interesting to note that the infected chicks showed almost similar patterns of clinical signs, gross findings. Thus, the suggestion by Purcell *et al* (1976) that the route of infection

with IBV may affect the incidence of disease is not supported. The serotype 793/B (4/91) isolated in Iran, had a broad tissue distribution that included: respiratory, digestive and urinary tract tissues. The histopathological changes reported here were characterized by prominent lesions in the trachea and kidneys. Replication of IBV in the respiratory tissues causes characteristic changes (Mahdavi *et al* 2005). In the present study, the frequent finding of histopathological changes was in the epithelium of trachea and also in kidneys, intestine. Thus, the suggestion by Purcell *et al.* (1976) that the virus is primarily epitheliotropic and enters the cells by viropexis is supported. The pattern of the reaction in the trachea was similar to that previously described by McDonald (1970) in infected chicks with an IB virus of Massachusetts type. Of course, the pattern of heterophils infiltration in the lamina propria of trachea was not similar to that of Massachusetts type. However, in this study, the initial reaction was the destruction of ciliated epithelium. Although, there was a lymphocytic infiltration on the 4th day PI, and this was not comparable to the score and degree of infiltration described by Garside (1965). The detection of IBV antigen for this serotype in the renal epithelial cells correlated with the development of kidney damage in virus inoculated chicks (Mahdavi *et al* 2003). The histopathological changes presented in this study indicate that the serotype 793/B isolated in Iran, may be a nephropathogenic virus (NIBV). Renal lesions consisting of tubular degeneration, desquamation and necrosis in epithelium, and an inflammatory cell reaction in the interstitium (ducto-tubular interstitial nephritis). These findings and other principal lesions are similar to those produced by infection with the nephropathogenic IBV (NIBV) (Albassam *et al* 1985, Capua *et al* 1999, Chen *et al* 1996, Chong *et al* 1982, Dhinakar *et al* 1996, Julian *et al* 1996, Purcell *et al* 1976, Siller 1981, Winterfield *et al* 1984). The pathogenesis of the compacted areas in the different parts of kidneys is yet open to question. Compared

with the kidney damage, the tracheal lesions recovered faster in both infected groups. Thus, the upper respiratory tract (especially trachea) may be the site of virus replication. On the other hand, these tissues were inferior only to urinary tissues and also were supporting for virus multiplication.

References

- Aghakhan, S.M., Abshar, N., Fereidouni, S.R., Marunesi, C. and Khodashenas, M. (1994). Studies on avian viral infections in Iran. *Archives of Razi Institute* 44 / 45: 1-5.
- Albassam, M.A., Winterfield, R.W., Thacker, H.L. (1985). Comparison of the nephropathogenicity of four strains of infectious bronchitis virus. *Avian Diseases* 30 (3): 468-476.
- Alexander, D.J., Gough, R.E. (1977). Isolation of avian infectious bronchitis virus from experimentally infected chickens. *Research Veterinary Science* 23: 344-347.
- Ambali, A.G., Jones, R.E. (1990). Early pathogenesis in chicks of infection with an enterotropic strain of IBV. *Avian Diseases* 34: 809-817.
- Ambali, A.G. (1992). Recent studies on the enterotropic strain of avian IBV. *Veterinary Research Communications* 16: 153-157.
- Capua, I., Minta, Z., Karpinska, E., Mawditt, K., Britton, P., Cavanagh, D., Gough, R.E. (1999). Co-circulation of four types of infectious bronchitis virus (793/B, 624/I, B1648 and Massachusetts). *Avian Pathology* 28: 587-592.
- Case, J.T., Ardans, A.A., Bolton, D.C. and Reynolds, B.J. (1983). Optimization of parameters for detecting antibodies against infectious bronchitis virus using an enzyme-linked immunosorbent assay: temporal response to vaccination and challenge with live virus. *Avian Diseases* 27: 196-210.
- Cavanagh, D., Davis, P.J., Cook, J.K.A., Li, A., Kant, A. and Koch, G. (1992). Location of the amino acid differences in the S1 spike glycoprotein subunit of the closely related serotypes of infectious bronchitis virus. *Avian Pathology* 21: 33-43.
- Cavanagh, D., Naqi, S.A. (2003). Infectious Bronchitis. In: Y.M., Saif, Barnes, J.R., Glisson, A.M., Fadly, L.R., McDougald and Swayne, D.E. (Eds.), *Diseases of Poultry* (11th edn.). Pp: 101-119. Iowa State University Press: Ames.
- Chen, B.Y. and Itakura, C. (1996). Cytopathology of chickrenal epithelial cells experimentally infected with avian infectious bronchitis virus. *Avian Pathology* 25: 675-690.
- Chen, B.Y., Hosi, S., Nunoya, T. and Itakura, C. (1996). Histopathology and immunohistochemistry of renal lesions due to infectious bronchitis virus in chicks. *Avian Pathology* 25: 269-283.
- Chong, K.T. and Apostolov, K. (1982). The pathogenesis of nephritis in chickens induced by infectious bronchitis virus. *Journal of Compendium Pathology* 92: 199-211.
- DeWit, J.J. (2000). Detection of infectious bronchitis virus. *Avian Pathology* 29: 71-93.
- Dhinakar raj, G. and Jones, R.C. (1996). An *in vitro* comparison of the virulence of seven strains of infectious bronchitis virus using tracheal and oviduct organ cultures. *Avian Pathology* 25: 649-62.
- Garsid, J.S. (1965). The histopathological diagnosis of avian respiratory infections. *Veterinary Records* 77: 354-366.
- Gelb, J., Wolff, J.B. and Moran, C.A. (1991). Variant serotypes of infectious bronchitis virus isolated from commercial layer and broiler chickens. *Avian Diseases* 35: 82-87.
- Gough, R.E., Randall, C.J., Dagless, M., Alexander, D.J., Cox, W.J. and Pearson, D. (1992). A "new" strain of infectious bronchitis virus infecting domestic fowl in Great Britain. *Veterinary Records* 130: 493-494.
- Jia, W., Karaca, K., Parrish, C.R. and Naqi, S.A. (1995). A novel variant of avian infectious bronchitis virus resulting from recombination among three different strains. *Archives of Virology* 140: 259-271.
- Julian, R.T. and Willis, N.G. (1969). The nephritis syndrome in chickens caused by a holt strain of infectious bronchitis virus. *Canadian Veterinary Journal* 10: 18-19.
- King, D.J. and Cavanagh, D. (1991). Infectious bronchitis. In: B.W. calnek, H.J. Barnes, C.W. Beard W.M. Reid and H.W. Yoder, J.R (Eds.), *Diseases of poultry*. (9th edn). Pp: 471-484. Iowa: Iowa State University Press, Ames.
- Lucio, B. and Fabricant, J. (1990). Tissue tropism of three cloacal isolates and Massachusetts strain of infectious bronchitis virus. *Avian Diseases* 34: 865-870.
- Mahdavi, S., Tavasoly, A., Pourbakhsh, A. and Shamsedini, (2005). The immunohistochemistry study of lesions due to avian infectious bronchitis (serotype

- 4/91) on different tissues in SPF chicks, *Journal Faculty of Veterinary Medicine* 60 (1):
- McDonald, J.W. (1970). Histopathology of infectious bronchitis, Diagnostic problems. *Veterinary Record* 87: 729-736.
- Momayez, R., Pourbakhsh, S.A., Khodashenas, M. and Banani, M. (2002). Isolation and identification of infectious bronchitis virus from commercial chickens, *Archives of Razi Institute* 53: 1-10.
- Momayez, R., Pourbakhsh, S.A., Toroghi, R. Akhavizadegan, M.A., Ebrahemi, M.M., Banani, and M., Masoudi (2006). Research on technology of the production of oil emulsion infectious bronchitis vaccine. *Unpubilshed Report*.
- Otsuki, K., Huggins, M.B. and Cook, J.K.A. (1990). Comparison of the susceptibility to infectious bronchitis virus infection of two inbred lines of White Leghorn chickens. *Avian Pathology* 19: 467-475.
- Purcell D.A., Tham V.L. and Surman P.G. (1976). The histopathology of infectious bronchitis in fowls infected with a nephrotropic T strain of virus. *Australian Veterinary Journal* 52: 85-91.
- Riddell, C. (1987). Avian Histopathology. In: *American Association of Avian Pathology*: Kennett Square, PA.
- Seify Abad Shapouri, M.R., Mayahi, M., Chakhkar, S. and Assasi, K. (2000). Serotype identification of recent Iranian isolates of infectious bronchitis virus by type-specific multiplex Rt-PCR. *Archives of Razi Institute* 53: 79-85.
- Siller, W.G. (1981). Renal pathology of the fowl. A review. *Avian Pathology* 10: 187-262.
- Vasfi Marandi, M. and Bozorgmehri Fard, M.H. (2000). Isolation and identification of infectious bronchitis viruses in chickens in Iran. In: *Proceedings of the World's Poultry Congress 2000*. Montreal, Canada.
- Winterfield, R.W. and Albassam, M.A. (1984). Nephropathogenicity of infectious bronchitis virus. *Poultry Science* 63: 2356-2363.