

## Mortality of wild swans associated with naturally infection with highly pathogenic H5N1 avian influenza virus in Iran

Shoushtari<sup>1\*</sup>, A., Hablolvarid<sup>2</sup>, M.H., Vascellari<sup>3</sup>, M., Hedayati<sup>2</sup>, A.

1. Department of avian diseases, Razi Vaccine and Serum Research Institute, Karaj, Iran

2. Department of pathology, Razi Vaccine and Serum Research Institute, Karaj, Iran

3. Istituto zooprofilattico sperimentale delle Venezie, Padova, Italy

Received 02 Apr 2007; accepted 23 Sep 2007

---

### ABSTRACT

In the February 2006 in two wetlands in northern Iran, the mortality among wild swans was observed. Paralysis was the most prominent feature of the disease. Histologically, diffused necrosis of acinar cells in pancreas, degeneration and necrosis of some neurons in central nervous system (CNS), severe necrotic and hemorrhagic enteritis, foci of haemorrhage and myocardial cell necrosis in the heart, mild to moderate multifocal hepatocytic necrosis, limited focal necrosis in the kidney and testis and morphological evidence of apoptosis in the spleen were observed. Immunohistochemically, influenza virus antigen were detected more often in the acinar cells of pancreas, some neuron and glial cells in CNS, renal tubule of kidney and hepatocytes of the liver. Moreover, antigen was seen in the meissner plexus of the intestine and testis, but seldom in the lung. The RT-PCR tests showed the presence of H5, N1 and NP genes of influenza virus in trachea, lung, liver, kidney, spleen, and cerebellum. Deduced amino acid sequence at cleavage site was PQGERRRKKR G which is typical for highly pathogen avian influenza viruses. The phylogenetic analysis of HA (hemagglutinin) protein showed a very close similarity of Z/101(H5N1) virus with HA proteins of H5 influenza viruses isolates from cat, wild duck, chicken, ostrich and turkey in various geographical regions. Our data confirmed that these new emerging viruses are systemically able to infect wild swans. The high HA protein sequence similarity among H5N1 viruses from various geographical areas of the world shows that the wild aquatic birds are the major cause of worldwide spreading of H5N1 viruses.

**Keywords:** Influenza, Swan, H5N1, RT-PCR, Immunohistochemistry, Histopathology

---

### INTRODUCTION

Avian influenza (AI), or bird flu, is a virus typically found in wild birds, especially waterfowl and shorebirds. It is generally accepted that waterfowl play an important role in the generation,

spread, and enzootic transmission of avian influenza (AI). Published surveys indicate that all 16 hemagglutinin (HA) and 9 neuraminidase (NA) subtypes have been isolated from wild waterfowl and aquatic shorebirds (Hanson *et al* 2003 and Alfonso *et al* 1995). However, the virus is only found in a small number of birds in the wild, and

---

\*Author for correspondence. E-mail: hamid1342ir@yahoo.com

generally does not cause clinical signs of disease (Alexander 2000).

Avian influenza viruses can be sorted on the basis of virulence (Garten & Klenk, 1999, Horimoto & Kawaoka, 2005). Low pathogenic avian influenza (LPAI) viruses lead to benign respiratory and/or intestinal tract infections. Highly pathogenic avian influenza (HPAI) viruses cause a multi-organ systemic infection responsible for high levels of mortality. These viruses are rarely isolated in wild birds (Swayne & Suarez 2000). Conversely, domestic birds, especially poultry, are victims of recurrent outbreaks due to HPAI viruses of subtypes H5 and H7 (Alexander 2000, Olsen *et al* 2006). In poultry, AIV evolve independently of the wild bird reservoir (Suarez 2000).

Highly pathogenic (HP) H5N1 viruses have been detected in China since 1996 (Tang *et al* 1998; Xu *et al* 1999). Outbreaks were reported almost simultaneously in eight neighboring Asian countries between December 2003 and January 2004, suggesting that the viruses had spread recently and rapidly (Sims *et al* 2005). In July 2005, HP H5N1 viruses started their westward progression by crossing the Russian border (Kilpatrick *et al* 2006, Gauthier-Clerc *et al* 2007): outbreaks were first detected in Western Siberia, and almost simultaneously in Kazakhstan and Mongolia (O.I.E. 2006). In October 2006, it was found in Romania, Croatia and the Western edge of Turkey. From February 2006 onwards a second phase started, characterized by numerous sporadic outbreaks affecting mainly wild birds in European countries, but also poultry in Africa (e.g. Nigeria) and the Middle East (e.g. Iraq). Migratory water birds were at the top of the list of suspects for the spread of HP H5N1 viruses (Webster *et al* 2006, Normile 2005, 2006). Nevertheless, the potential role of wild birds in the HP H5N1 crisis is still put forward (FAO 2006, Gauthier-Clerc *et al* 2007), calling for more research towards a better understanding including pathogenesis of avian influenza viruses in wild

birds. During the recent outbreaks in Europe, swans appeared to be primarily affected and were designated as an indicator species of the presence of HPAIV H5N1 in wild birds (Melville & Shortridge 2006, Capua & Alexander 2006, Munster *et al* 2005). The main objective of our study is description the process of detection and characterization first introduced HPAI viruses into the country emphasizing on molecular tools such as RT-PCR and sequencing. We also report the results of postmortem examinations and describe the distribution of histological lesions and viral antigen of HPAIV in wild swans, naturally infected and succumbed to fowl plague during the recent outbreak in two marshes (Selkeh & Espand) at Somaesara (Anzali Wetland).

## MATERIALS AND METHODS

**Sampling and necropsy.** Necropsy was performed on all cases. Of twenty five examined dead swan, nineteen carcasses were in good condition. However the internal organs of all dead bodies including brain, heart, trachea, lung, pancreas, intestine, kidney, spleen and liver were sampled and carried under Trizol solution (Roche, Germany) to laboratory. The same panel of tissue samples was fixed in 10% phosphate-buffered neutral formaldehyde and processed for histopathology and immunohistochemistry (ICH) studies. Parallel sampling also were done in 10% formalin for histopathology and immunohistochemistry studies.

**RT-PCR and DNA sequencing.** The RNA extraction was carried out using Trizol solution (Roche, Germany) following manufacture instruction. All samples were tested by molecular methods recommended by WHO (2002) using One Step Titan RT-PCR kit (Roche, Germany). All samples were tested for H5N1, H9 and H7 influenza viruses (Yuen *et al* 1998, Wright *et al* 1995). The samples also examined for detecting of Newcastle

disease virus (NDV) and duck plague viruses (DPV). Finally an approximately 500 PCR product for H5 gene of influenza virus (Lee *et al* 2001) was amplified and sequenced for further studies.

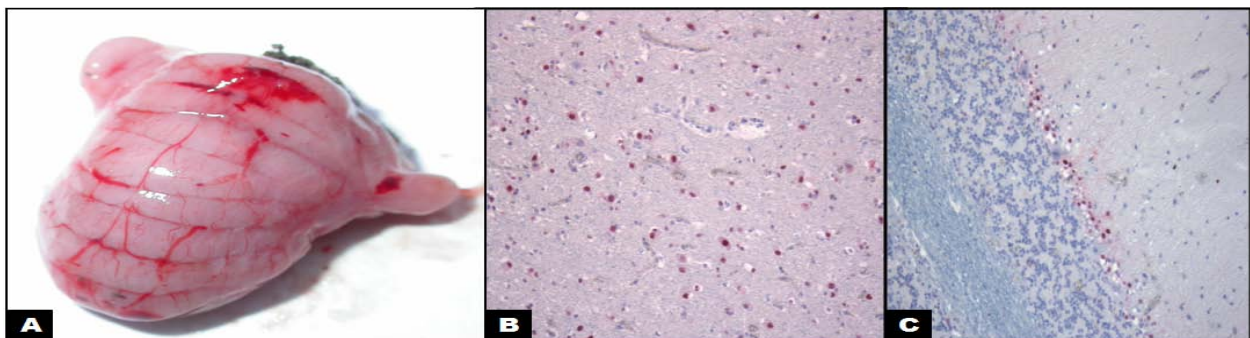
#### Histopathology and immunohistochemistry.

Tissues were fixed in 10% v/v buffered formaldehyde solution embedded into paraffin blocks and then cut into 3 to 4 mm thin sections and stained with haematoxylin eosin. To demonstrate influenza in immuno histochemistry study a nucleoprotein a rabbit antinucleoprotein serum was used. The sections were deparafinized, treated in 100% xylene and dehydrated through graded ethanols. To quench endogenous peroxidase activity all sections were treated for 5min 3% H<sub>2</sub>O<sub>2</sub> in methanol (blocking solution). Following 4, 3min washing with PBS, the samples were treated with 0.3% trypsin for 20min to unmask the formalinated antigens. The main blocking was carry out using 5% bovine serum albumin for 30min , then the tissues were incubated with a rabbit anti-nucleoprotein serum and conjugated goat anti- rabbit IgG, and peroxidase solution respectively.

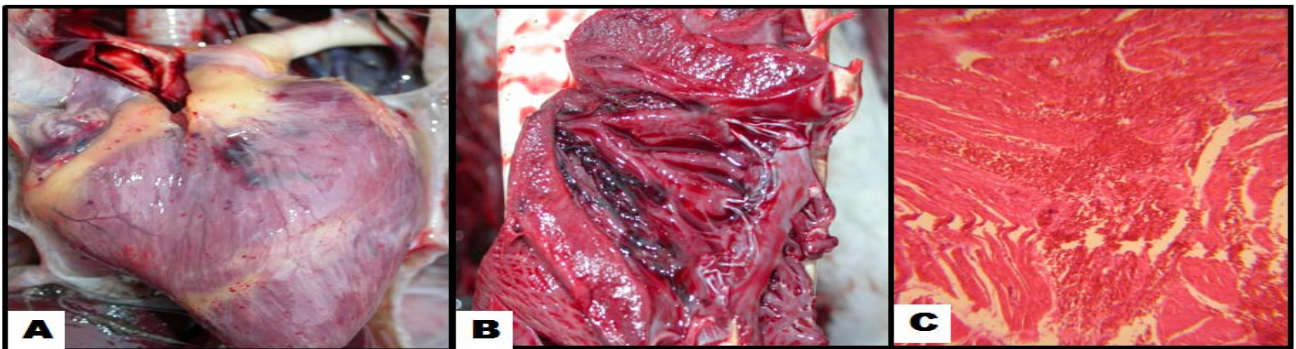
## RESULTS

**Gross pathology.** No alive ill swan was observed by the author. However a circulating movement was recorded by local veterinarian. In general most of dead bird had no external lesions. A few of birds showed exudates around their nostril. Also a small number had diarrhea according existence of green discolored feathers around the cloacae. The predominant feature in necropsy in all examined case was hemorrhage of various sizes in many organs including cerebellum (Figure 1A), heart (epicardium, endocardium) (Figure 2A & 2B), lung , rectum, liver. There were also variable lesions like edema and congestion of lung, focal necrosis within the parenchyma of the pancreas (Figure 3A), and enlargement of spleen and liver.

**Histopathology.** Main histopathologic lesions were seen in the intestine, pancreas, liver, spleen, cerebrum, cerebellum, testis and heart. In the pancreas diffuse acinar epithelial necrosis was noted (Figure 3B). In the liver mild to moderate multifocal hepatocytic necrosis with deposition of hemosiderin and infiltration of lymphocytes, especially around the vessels, were evident. Degeneration of the renal



**Figure 1.** (A) Haemorrhage in the cerebellum. (B) Some neurons show intense immunohistochemical positive reactions to influenza virus of H5N1 subtype (IHC  $\times 20$ ). (C) cerebellum of the dead swan. Intensive immunohistochemical positive reaction is seen in, mostly in pokinjie cell layer, cerebellum (IHC  $\times 20$ ).

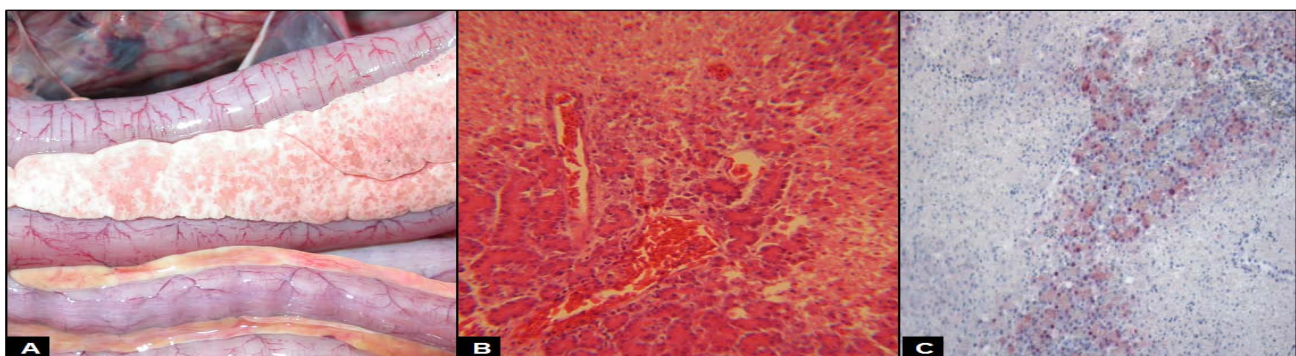


**Figure 2.** The heart of the dead swan. Ex tensive haemorrhage in (A)epicardium and (B) endocardium. (C)Haemorrhage and necrosis of some myocardial fibers is seen (H&E  $\times$  100).

tubule epithelium (Figure 4), especially proximal tubules, and rare focal necrosis and lymphocytic tubulo-interstitial nephritis was evident in the kidney. Sections of the central nervous system (CNS) revealed congestion and few small foci of haemorrhage and malacia. Moreover, some of neurons were degenerated / necrotic.

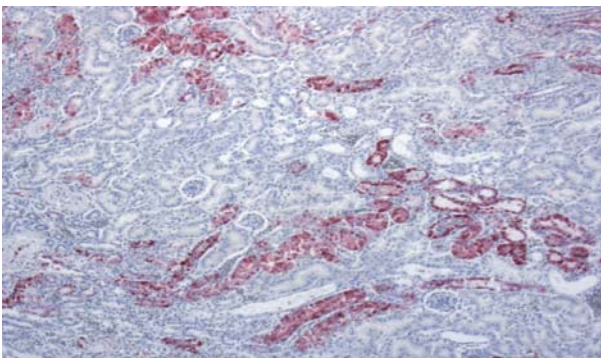
The intestine, Jejunum, was necrotic and hemorrhagic. Diffuses infiltration of the lymphocytes was detected in the infected villi. In the testis, Limited focal necrosis with mild infiltration of the lymphocytes was detected. Congestion was the main histopathological finding in the lung. In the heart there were foci of haemorrhage with myocardial cell degeneration and necrosis of some myocardial fibers (Figure 2C).

**Immunohistochemically.** influenza virus antigen were detected more often in the acinar cells of pancreas, some neuron and glial cells in CNS, renal tubule of kidney and hepatocytes of the liver. On IHC examination diffuses viral localization site were seen in nucleus and cytoplasm of acinar cells, especially in the margins of the necrotic foci (Figure 3C). Avian influenza virus nucleoprotein was identified in meisner plexus and rarely in epithelial cells. Some of the cells in testis sites showed positive reaction to viral nucleoprotein in IHC examination. Mild positive immunohistochemical reaction against the viral nucleoprotein antigen was detected in some of the hepatocytes. Some of the lymphocytes in the spleen exhibited morphological evidence of apoptosis. But no positive reaction was detected in



**Figure 3.** Pancreas of the dead swan. (A) The pancreas appears enlarged, and whitish in color with light pink spots. (B) Sever necrotizing pancreatitis. Necrotic part in the right side and bottom of the picture and the normal acinar cells in the left and upper part is seen (H&E  $\times$  100). (C) Pancreas of the dead swan. Intense immunohistochemical positive reaction in acinar cells of the pancreas (IHC  $\times$ 20).

IHC examination of this organ. IHC examination revealed intensive positive reaction to viral replication on nucleus and cytoplasm of the renal tubule epithelium (Figure 4). In IHC examination of cerebrum intensive positive reaction was detected in some neurons and glial cells. However, in the cerebellum intensive positive reaction mostly detected in purkinje cells (Figure 1B, 1C) and rarely in the cells of the other layers of gray matter.



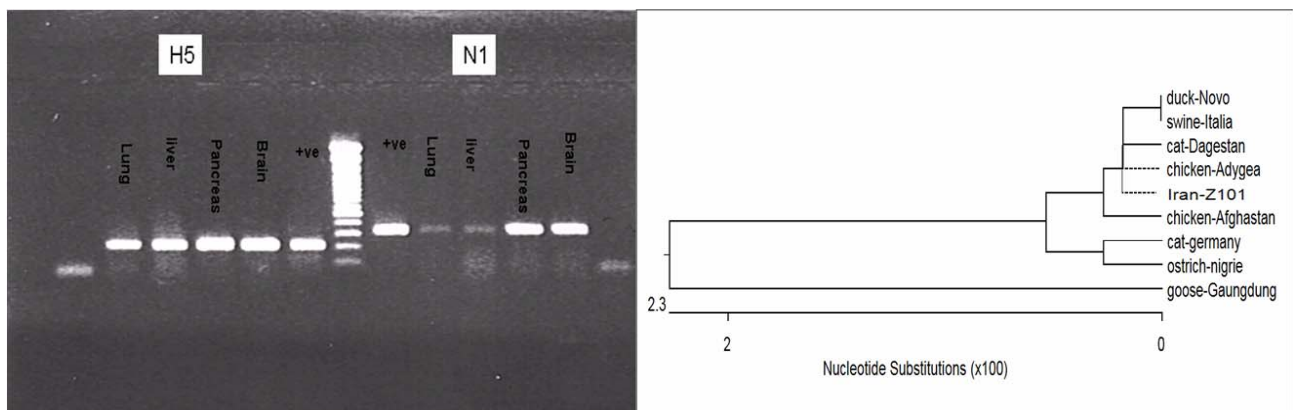
**Figure 4.** The red spots are influenza virus localization sites in renal tubule of the dead swan kidney (IHC  $\times 20$ ).

There was seldom positive reaction to viral nucleoprotein in some parts of the lung, no avian influenza virus nucleoprotein was identified in IHC examination of the heart spleen, and cerebellum (Figure 5A).

**RT-PCR and DNA sequencing.** The RT-PCR tests showed the presence of H5, N1 and NP genes of influenza virus in trachea, lung, liver, kidney, sequence at cleavage site was P<sub>Q</sub>G<sub>E</sub>R<sub>R</sub>R<sub>R</sub>K<sub>K</sub>R\* G which is typical for highly pathogen avian influenza viruses. The phylogenetic analysis of HA (hemagglutinin) protein showed a very close similarity of Z/101 (H5N1) virus with HA proteins of H5 influenza viruses isolates from cat, wild duck, chicken, ostrich and turkey in various geographical regions (Figure 5B). No positive reaction was observed for H9, H7, ND and duck plague viruses.

## DISCUSSION

Aquatic birds including orders Anseriformes (duck, geese, and swan) are the natural reservoir of influenza A viruses. The normally avirulent nature of avian influenza viruses in ducks suggests optimal adaptation of these viruses to their host (Alexander 2000). However we found that wild swans could be infected as victims of HPAI viruses. Although these finding must be considered as an exception of evolutionary stasis, however it seems that there is an evolutionary tendency among HPAI viruses to infect aquatic birds which may lead to disruption of longstanding equilibrium between influenza viruses



**Figure 5.** (A) The RT-PCR tests showed the presence of H5 and N1 and genes of influenza virus in trachea, lung, liver, kidney, spleen, and cerebellum. (B) The phylogenetic analysis of HA (hemagglutinin) protein showed a very close similarity of Z/101(H5N1) virus with HA proteins of H5 influenza viruses isolates from cat, wild duck, chicken, ostrich and turkey in various geographical regions.

and these birds. Such extraordinary nature of H5N1 has been experienced when these avian viruses could directly infect the human beings (Subbarao *et al* 1998).

There are many natural and experimental infection studies on pathologic effect of HPAI viruses in poultry. Excluding skin necrosis the pathologic effect of H5N1 virus in wild swan in this study are the same those have been described for domestic fowl. The predominant feature in necropsy in all examined case was haemorrhages of various sizes in many organs including, cerebellum, heart (epicardium, endocardium), lung, rectum and liver.

The asymmetric budding process (i.e. apical vs. basolateral) is believed to have an important role in viral pathogenesis and tissue tropism in that viruses that bud from the internal cell surface, tend to cause systemic disease, whereas viruses such as influenza virus that bud from the external cell surface generally have a more restricted tissue tropism (Feldmann *et al* 2000). However, in the present study, the extensive distribution of the virus and character of lesions is attributed to the acute and systemic viral infection. The sequence analysis of the virus indicated the presence of a multibasic cleavage site. Although the presence of multibasic cleavage site points out the highly pathogenic nature of the virus, the extensive gross lesion and histopathological finding especially in vital organs such as brain and heart may be considered as diagnostic tool suggesting the highly pathogenic characteristics of the virus.

The major migratory flyways in Asia encompass Siberia, the Caspian Sea, the Persian Gulf, the former Soviet republics, and extend to Alaska, Australia, and the island countries of the Pacific. There are extensive wetlands surrounding Caspian Sea area, such as Anzali wetland. The coincidence infection of H5N1 viruses in Russia and the former Soviet republics shows that the introducing of infection might be happened from these areas into Iran. This confirmed by our phylogenetic analysis

data and close relationship between the viruses detected in mentioned areas and of Z/101(H5N1) virus. It appears likely that migratory birds will carry avian influenza through Central Asia to the Caspian Sea area from its current position in the Ural mountains. This kind of introducing of infection into the country may happen again and again so these areas should be monitored closely. Many of these states are beginning to discover and tap oil reserves throughout their respective countries. If this new oil exploration is not properly managed, it may inflict damage on the wetlands of the area. This damage may cause alternate migratory routes, resulting in increased stopover points on proximate farms and towns.

The results of present study and other related researches indicate that there is significant species-related variation in susceptibility, clinical disease, in wild birds. But, based on our experience, wild swains are highly susceptible to H5N1 HPAI viruses with substantial illness and death. If H5N1 were introduced into the country, Iran, this species may serve as effective indicator species in a surveillance program.

## References

- Alexander, D.J. (2000). A review of avian influenza in different bird species. *Veterinary Microbiology* 74: 3-13.
- Alfonso, C.P., Cowen, B.S. and Van Campen, H. (1995). Influenza A virus isolated from waterfowl in two wildlife management areas of pennsylvania. *Journal of Wildlife Diseases* 31(2): 179-185.
- Capua, I. and Alexander, D.J. (2006). The challenge of avian influenza to the veterinary community. *Avian Pathology* 35: 189-205.
- Feldmann, A. Schafer, M.K. and Garten, W. (2000). Targeted infection of endothelial cells by avian influenza virus A/FPV/Rostock/34 (H7N1) in chicken embryos. *Journal of Virology* 74(17): 8018-8027.
- Food and Agriculture Organization of the United Nations (FAO). (2006). Wild birds' role in HPAI crisis confirmed. <http://www.fao.org/newsroom/en/news/2006/1000312/index.html>.

- Garten, W. and Klenk, H.D. (1999). Understanding influenza virus pathogenicity. *Trends of Microbiology* 7: 99-100.
- Gauthier-Clerc, M., Lebarbenchon, C. and Thomas, F. (2007). Recent expansion of highly pathogenic avian influenza H5N1: a critical review. *Ibis* 149: 202-214.
- Hanson, B.A., Stallknecht, D.E., Swayne, D.E., Lewis, L.A., and Senne D.A. (2003). Avian Influenza Viruses in Minnesota Ducks During 1998-2000. *Avian Diseases* 47: 867-871.
- Horimoto, T., Kawaoka, Y. (2005). Influenza: lessons from past pandemics, warnings from current incidents. *National Review of Microbiology* 3: 591-600.
- Kilpatrick, A.M., Chmura, A.A., Gibbons, D.W., Fleischer, R.C., Marra, P.P. and Daszak, P. (2006). Predicting the global spread of H5N1 avian influenza. *Proceeding National Academy of Science U.S.A.* 103: 19368-19373.
- Lee A.B., Poa-Chun Chang C., Jui-Hung Shien A., Ming-Chu Cheng B. and Happy K.S. (2001). Identification and subtyping of avian influenza viruses by reverse transcription-PCR. *Journal of Virological Methods* 97: 13-22.
- Melville, D.S. and Shortridge, K.F. (2006). Spread of H5N1 avian influenza virus: an ecological conundrum. *Letter Applied Microbiology*. 42: 435-437.
- Munster, V.J., Wallensten, A., Baas, C., Rimmelzwaan, G.F., Schutten, M., Olsen, B., Osterhaus, A.D.M.E. and Fouchier, R.A.M. (2005). Mallards and highly pathogenic avian influenza ancestral viruses, *Northern Europ Emerging Infection Disease* 11: 1545-1551.
- Normile, D. (2005). Are wild birds to blame? *Science* 310: 426-428.
- Normile, D. (2006). Evidence points to migratory birds in H5N1 spread. *Science* 311: 1225.
- O.I.E. (2006). Update on avian influenza in animals (type H5). [http://www.oie.int/downld/AVIAN%20INFLUENZA/A\\_AI-Asia.htm](http://www.oie.int/downld/AVIAN%20INFLUENZA/A_AI-Asia.htm).
- Olsen, B., Munster, V.J., Wallensten, A., Waldenstrom, J., Osterhaus, A.D.M.E. and Fouchier, R.A.M. (2006). Global patterns of influenza A virus in wild birds. *Science* 312: 384-388.
- Sims, L.D., Domenech, J., Benigno, C., Kahn, S., Kamata, A., Lubroth, J., Martin, V. and Roeder, P. (2005). Origin and evolution of highly pathogenic H5N1 avian influenza in Asia. *Veterinary Record* 157: 159-164.
- Suarez, D.L. (2000). Evolution of avian influenza viruses. *Veterinary Microbiology* 74: 15-27.
- Swayne, D.E. and Suarez, D.L. (2000). Highly pathogenic avian influenza. *Revue Scientifique et Technique de l'Office International des Epizooties* 19: 463-482.
- Tang, X.Y., Tian, G.B. and Zhao, C.S. (1998). Isolation and characterization of prevalent strains of avian influenza viruses in China. *Chinese Journal of Animal and Poultry Infectious Diseases*. 20: 1-5.
- Webster, R.G., Peiris, M., Chen, H. and Guan, Y. (2006). H5N1 outbreaks and enzootic influenza. *Emerging Infectious Diseases* 12: 3-8.
- WHO (2002). Recommended laboratory tests to identify avian influenza A virus in specimens. Geneva, World Health Organization (document WHO / CDS / CSR / NCS/2002(5), available at: ([http://www.who.int/csr/disease/avian\\_influenza/guidelines/labtests/en/](http://www.who.int/csr/disease/avian_influenza/guidelines/labtests/en/)).
- Wright KE. (1995). Typing and subtyping of influenza viruses in clinical samples by PCR. *Journal of Clinical Microbiolog* 33: 1180-1184.
- Xu, X., Subbarao, K., Cox, N.J. and Guo, Y. (1999). Genetic characterization of the pathogenic influenza A/Goose/Guangdong/1/96 (H5N1) virus: similarity of its Hemagglutinin gene to those of H5N1 viruses from the 1997 outbreaks in Hong-Kong. *Virology* 261: 15-19.
- Yuen, K.Y., Chan, P.K., Peiris, M., Tsang, D.N., Que, T.L., Shortridge, K.F., Cheung, P.T., To, W.K., Ho, E.T., Sung, R. and Cheng, A.F. (1998). Clinical features and rapid viral diagnosis of human disease associated with avian influenza A H5N1 virus. *Lancet*, 351: 467-471.
- Subbarao, K. Klimov, A. and Katz, J. (1998). Characterization of an avian influenza A (H5N1) virus isolated from a child with a fatal respiratory illness. *Science* 279: 393-396.