

Short Communication

**Nematode association with *Bellamya bengalensis* snail and its medical and veterinary importance in Khuzestan province (south west of Iran)**

**Farahnak\*, A., Mobedi, I., Ghobadi, H.**

*Department of Parasitology and Mycology, School of Public Health, Tehran University of Medical Sciences, Tehran, Iran*

Received 2 Aug 2005; accepted 30Jan 2006

---

**ABSTRACT**

Limited studies have been done on nematodes of *Bellamya bengalensis* (fresh water snails) in the world. Following, our clinical observations on eye disease in a fish ponds, which were contained *Bellamya bengalensis* snails, present study was made to determine of nematodes fauna of *Bellamya bengalensis* and evaluation of their medical and veterinary importance in Khuzestan province. For this purpose, 1143 bellamya snails were collected from Ahoudasht and Chogha Mish regions, including fish pond in the central areas of Khuzestan province during 2002-2003. Bellamya snails examined for nematodes with emerging or crushing methods and identified by systematic key references. In addition, to confirm of clinical observations in the field, an experimental infection protocol was designed in our laboratory. From the total of bellamya snails which examined for nematodes, 27 (2.36%) snails were found to be infected with *Oionchus* nematode parasite. In the experimental infection, cloudy appearance of cornea was observed. These results have been recorded for the first time and show the importance of bellamya snails in the region.

**Keywords:** *Bellamya bengalensis*, Nematode, Fish

---

**INTRODUCTION**

In recent years snails have received increased attention because of the roles of certain species to establish important zoonoses in some parts of world. The importance of snails as intermediate and paratonic host for certain species of nematodes,

although well recognized, has been overshadowed by the role of snails in the life cycle of medically and economically important trematodes (Ghobadi 2004, Malek 1974). Freshwater snails are the first intermediate host for man and animals helminthes parasites. Snail transmitted disease such as Angiostrongylosis due to *Angiostrongylus* spp (Angiostrongylidae; Nematodes) are national or international public health problems (Dissanaik *et*

---

\* Author for correspondence. E-mail: farahnak@sina.tums.ac.ir

al 2001, Thoma et al 2002, Tsai et al 2003, Barcante et al 2003, Wan et al 2004). *Bellamya bengalensis* snail is belonging to fresh water snails and having limited widespread in Khuzestan province, south western Iran. Base on our observations these snails are localized in Ahoudasht and Agirob regions in central areas of Khuzestan. In addition our observations were showed the existence of injured fishes in Chogha Mish region. Therefore, the purpose of the present study was to determine the bellamaya snail transmitted nematodes in these regions and their relationship with fish disease.

## MATERIALS AND METHODS

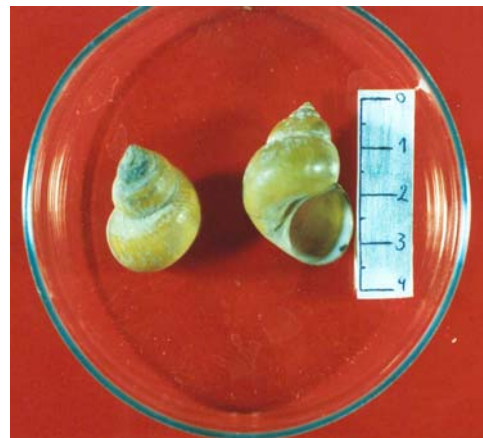
**Fish clinical studies.** Following request of a fish ponds owner for fish's eye problem, our team surveyed his ponds for fish diseases. In this regard samples of snails and fishes were collected from his ponds and examined for infectious agent and clinical signs respectively.

**Field studies.** Field study was made on 1143 *Bellamya bengalensis* snails which were collected from Ahoudasht and Chogha Mish regions in the central area of Khuzestan province. *Bellamya* snails were collected from the ponds, drains and canals by a wooden handle paddle with 1.5 meter long and net size 30 x 40 cm. The snails were transferred to Dezfoul health research center as alive. The snails were keeping in aquarium and nematode helminthes obtained by emerging and crushing methods. In the emerging method snails put in Petri dish containing dechlorinated tap water and were placed against light for two hours or over night in room. In the crushing method, shells of snails were broken with tweezers and soft tissue were placed between 2 slides and squashed. Obtained nematodes observed as alive and then fixed in alcohol 70 v/v%. Measurements and drawings were made on living or fixed specimens under light cover glass pressure and stained with azocarmine. Nematode was identified by using systematic key references (Yamaguti 1961).

**Experimental studies.** To confirm of fish clinical observations in the field, an experimental infection protocol was designed in our laboratory. For this purpose, infected bellamya snails were placed in an aquarium with healthy *Gambusia affinis* fish for 1 month. Non infected bellamya associate with *Gambusia affinis* were also leaved in another aquarium as negative control. Fishes were daily examined for eye injuries for one month period.

## RESULTS AND DISCUSSION

Clinical examinations of collected fish (*Cyprinus* spp.) from the fish ponds in the region, revealed cornea injuries in the eyes as cloudy appearance of cornea.



**Figure 1.** *Bellamya bengalensis* snail from Ahodasht region from Khuzestan province, south west of Iran

From 1143 *Bellamya bengalensis* snails (Figure 1) which were examined in this survey, 27 (2.36%) were associated with *Oionchus* nematode (Figure 2).

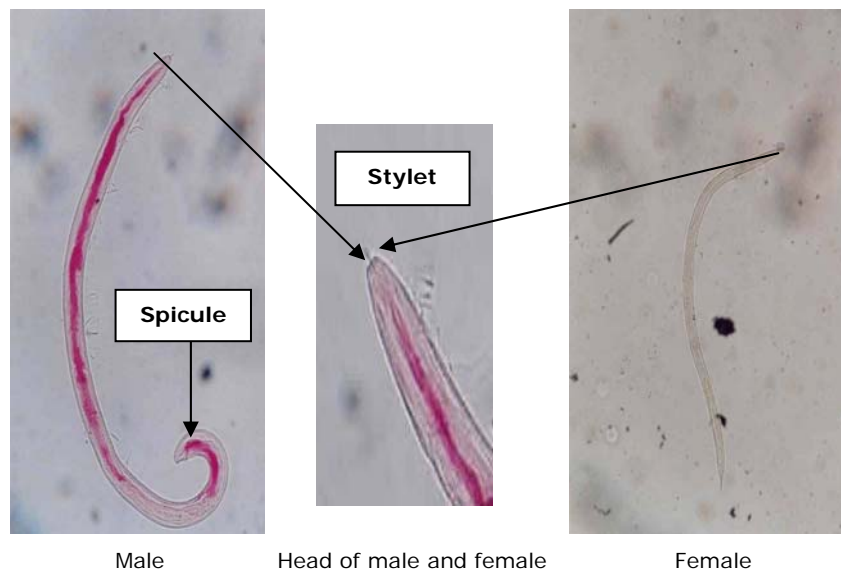
**Morphological specificity of nematode.** Major and specific characters which identified in this nematode were as follows: Male; with stylet and spicule; Female: With stylet and with eggs in uterine; Larva stage: Without spicule or eggs however with stylet.

**Table 1.** The size of *Oionchus* and stylet organ from *Bellamya bengalensis* (in micron).


Nematode	Length	Wide	Stylet
<i>Oionchus</i> (Adult)	1845-2100	52-4	27-30
Larvae	600	20	10

in fish eyes were observed (Figure 3). These symptoms were like fish injuries in the field examinations.

Chitwood and his colleagues (1937) distinguished the nematodes occurring in snails as belonging to six group based on differences in life cycle pattern as follows:



**Figure 2.** Male and Female of *Oionchus* nematode.



**Figure 3.** Gambusia fish with cornea inflammation after 20 days post infection

**Morphometric specificity of nematode.** The size of *Oionchus* from *Bellamya bengalensis* are presented in the Table 1.

**Experimental studies.** After 20-30 days post infection in aquarium, cloudy appearance of cornea

1) Free living and plant parasitic nematodes that may pass through an animals' digestive tract uninjured. 2) Obligatorily parasitic nematodes living in the host's digestive tract.

3) Nematodes with parasitic larvae occurring in the foot muscle of the host and with a free living adult stage. 4) Adult nematodes living in the genital organs of the host. 5) Nematodes the live in the lung and body spaces and leave the host for free living existence. 6) Parasitic nematodes of vertebrates, the larvae of which occurring snails (Chitwood *et al* 1937). It seems *Bellamya bengalensis* could be as a potential source for nematode infection of man and animals especially fish. Natural and experimental association of adult and larva stage of *Oionchus* show, this snail presumably is a definitive host for

this nematode. Many larval nematodes can be occurring in the tissue of snails and encapsulated. The final host would be infected after consuming infected snail such as *angiostrongylus* (Muller 2002). Other larvae of nematodes occurring in tissue of snails without any encapsulation and transform to adult form of parasite. From pathogenesis stand point the stylet organ is very important. Stylet is very long, strong and flexible structure in the nematode. The nematode could be empty the content of tissue by stylet. This process leads to chronic inflammation of tissue such as cornea and finally results to cloudy appearance of fish eyes.

Khouzestan province has many ponds, drains and canals which are using for bathing, drinking and washing by people. These places are suitable for living of *Bellamya bengalensis* snails. Due to bellamaya infection, water could be infected with this nematode; therefore the nematode should be able to attack the man eye, especially children. The present study has demonstrated that *Bellamya* snails were infective with *Oionchus* nematode which could be injuring to fish and presumably man. These results which have been recorded for the first time, they showed the importance of bellamaya snails in transmission of disease in the region. More studies should be done and focused not only on snails but also on biology and life cycle of parasite and clinical examinations on local people especially children.

### Acknowledgements

We wish to thank Dr. Mansoorian for his review on snails. Thanks also to staff of Dezful Health Research Center, Mrs. Jahanbani M., Poorshojaii R. and Shakerian A. for sampling and Kotalan H. for transportation and Mirsepahi N. for her helping. This study

was supported by Tehran University of medical sciences.

### References

- Barcante, T.A., Barcante, J.M., Dias, S.R. and Lima-Wdos, S. (2003). *Angiostrongylus vasorum* (Baillet, 1866) Kamensky, 1905: Emergence of third-stage larvae from infected *Biomphalaria glabrata* snails. *Parasitology Research* 91: 471-5.
- Chitwood, B.C., and Chitwood, M.B. (1937). Snails as hosts and carriers of nematodes and nematomorpha. *Nautilus* 50: 130-135.
- Dissanaike, A.S., Ithalamulla, R.L., Naotunne, T.S., Senarathna, T. and Withana, D.S. (2001). Third report of ocular para-strongyliasis (angio-strongyliasis) from Sri Lanka. *Parasitologia* 43: 95-97.
- Ghobadi, H. and Farahnak, A. (2004). A Faunistic survey on cercariae of *Bellamya* (viviparous) *bengalensis* snails and their zoonotic importance. *Iranian Journal of Public Health* 33: 38-42.
- Malek, E.A. (1974). *Medical and Economic Malacology*. Academic Press, New York and London.
- Muller, R. (2002). *Worms and Human Disease* (2<sup>nd</sup> edn.). Wallingford, Oxon, Oxford University Press, USA (CABI Publishing).
- Toma, H., Matsumura, S., Oshiro, C., Hidaka, T. and Sato, Y. (2002). Ocular angiostrongylosis without meningitis symptoms in Okinawa, Japan *Journal of Parasitology* 88: 211-211.
- Tsai, H.C., Liu, Y.C., Kunin, C.M., Lai, P.H., Lee, S.S., Chen, Y.S., Wann, S.R., Lin, W.R., Huang, C.K., Ger, L.P., Lin, H.H. and Yen, M.Y. (2003). Eosinophilic meningitis caused by *Angiostrongylus cantonensis* associated with eating raw snails: correlation of brain magnetic resonance imaging scans with clinical findings. *American Journal of Tropical Medicine and Hygiene* 68: 281-285.
- Wan, K.S. and Weng, W.C. (2004). Eosinophilic meningitis in a child raising snails as pets. *Acta Tropica* 90: 51-53.
- Yamaguti, S. (1961) *Systema helminthum: The nematodes of vertebrate* (volume 3). Interscience publisher, Inc New York, USA.